



Laparoscopy in Acute Cholecystitis: To Drain or Not to Drain

Aly Saber^{1,*}, Emad Hokkam^{2,3}, Abdulmonem Alshayeb⁴

¹Department of Surgery, Port-Fouad General Hospital, Port-Said, Egypt

²Department of Surgery, Faculty of Medicine, Jazan University, Jazan, KSA

³Department of Surgery, Faculty of Medicine, Suez Canal University, Ismailia, Egypt

⁴Department of Surgery, Najran General Hospital, Najran, KSA

Email address:

ehokkam@gmail.com (E. Hokkam), Alysaber54@gmail.com (A. Saber)

*Corresponding author

To cite this article:

Aly Saber, Emad Hokkam, Abdulmonem Alshayeb. Laparoscopy in Acute Cholecystitis: To Drain or Not To Drain. *Journal of Surgery*. Special Issue: Minimally Invasive and Minimally Access Surgery. Vol. 5, No. 3-1, 2017, pp. 28-32. doi: 10.11648/j.js.s.2017050301.16

Received: January 25, 2017; **Accepted:** January 29, 2017; **Published:** February 18, 2017

Abstract: *Introduction:* Regarding cholecystectomy for acute cholecystitis, there is still debate regarding drain insertion. The aim of the present study was to detect if there is a beneficial added value to drain the abdomen in case of laparoscopic cholecystectomy for acute cholecystitis. *Patients and Methods:* A total of 120 patients diagnosed having acute cholecystitis were enrolled to this study and were divided according to the drain insertion into two main groups; with drain (group A) and without drain (group B). *End Points:* The primary endpoint was the presence of operative field fluid collection at abdominal ultrasonography when performed twenty four hours after surgery. Secondary endpoints included postoperative abdominal, length of hospital stay and wound infection. *Results:* Concerning the demographic data, there was no statistical significant difference between the two groups regarding age, sex and body mass index. The mean operative time, hospital stay, postoperative pain and wound infection rate were higher in drain versus no drain group. *Conclusion:* The present study showed that there was no added benefit for prophylactic drain insertion after cholecystectomy for acute calculous cholecystitis. Drain insertion may be a cause of delayed discharge and prolonged hospital stay after laparoscopic procedures. Increased intensity of postoperative pain and wound infection are claimed to be due to drain insertion.

Keywords: Acute Cholecystitis, Laparoscopy, Drain, No Drain

1. Introduction

Drainage of body cavities has been practiced in medicine for a long time and drainage after abdominal surgery has always been a subject of controversy [1]. Fear of blood collection requiring intervention is another reason for routine drainage after cholecystectomy [1, 2]. Nowadays, there is consensus that there is no indication to insert a prophylactic drain after elective laparoscopic or open cholecystectomy [3]. However, regarding cholecystectomy for acute cholecystitis, there is still debate regarding drain insertion [4, 5]. The diagnosis of acute cholecystitis should be confirmed by clinical examination, laboratory data and ultrasound study [6] according to the Tokyo Guidelines for the management of acute cholangitis and cholecystitis [7]. The aim of the present

study was to detect if there is a beneficial added value to drain the abdomen in case of laparoscopic cholecystectomy for acute cholecystitis.

2. Patients and Methods

A total of 120 patients diagnosed having acute cholecystitis were enrolled to this prospective randomized study from April 2010 to December 2015 at Port-Fouad general hospital and Suez-Canal University hospital. Patients were divided according to the drain insertion into two main groups; with drain (group A) and without drain (group B). Written consent was obtained from all patients or first degree relatives before the management procedure and the local ethics committee approved the study.

2.1. Preoperative Workup

The diagnosis of acute cholecystitis was confirmed by clinical examination, laboratory data and ultrasound study. Ultrasonography findings were confirmed when sonographic Murphy sign with tenderness on ultrasound probing was elicited. Thickened gallbladder wall >4 mm and enlarged gallbladder with long axis diameter >8 cm, short axis diameter >4 cm. Sonolucent layer in the gallbladder wall, striated intramural lucencies, and pericholecystic fluid collection [6]. Grading of acute cholecystitis was considered according to our previously published paper [6]; mild acute cholecystitis Grade I; is defined as acute cholecystitis in a healthy patient with only mild inflammatory changes in the gallbladder, Grade II; moderate acute cholecystitis is diagnosed when palpable tender mass in the right upper abdominal quadrant with marked local inflammation in US together with WBC count >18 000/mm³ and Grade III; severe acute cholecystitis is accompanied by organ dysfunctions. In our study, patients of both grades I and II were included but grade III patients were excluded from our protocol.

2.2. Operative Technique

Laparoscopic cholecystectomy was performed by the treating surgical team consisting of a consultant surgeon and an assistant professor of surgery using the standard 4-trochar technique. Gallbladder contents were aspirated in cases with gallbladder distension. Meticulous dissection was paid to identify the structures in Calots triangle and attempts of retrograde dissection of the gallbladder starting at the fundus were done in case of severe inflammation and anatomical difficulty of the pericystic space. We used plastic bags for gallbladder removal from the abdomen for prevention of wound infection and falling of stones. Meticulous dissection of the gallbladder from its bed was performed and perfect haemostasis was secured all over the operative field and after that, drains were inserted in patient belonging to group A.

Randomization

Randomization was performed prior to study commencement as follows: Opaque envelopes were numbered sequentially from 1 to 120. A computer-generated table of random numbers was used for group assignment; if the last digit of the random number was from 0 to 4, assignment was to Group A [Laparoscopic cholecystectomy with drain], and if the last digit was from 5 to 9, assignment was to Group B [Laparoscopic cholecystectomy without drain]. The assignments were then placed into the opaque envelopes and the envelopes sealed. As eligible participants were entered into the study, these envelopes were opened in sequential order to give each patient his or her random group assignment. The envelopes were opened by the operating surgeon after patient consent indicating the agreement of the study protocol and just prior to the surgery.

2.3. End Points

The primary endpoint was the presence of operative field

fluid collection at abdominal ultrasonography when performed twenty four hours after surgery. Secondary endpoints included postoperative abdominal, length of hospital stay and wound infection.

Statistical analysis

Data collected were processed using SPSS version 15 (SPSS Inc., Chicago, IL, USA). Quantitative data were expressed as means \pm SD while qualitative data were expressed as numbers and percentages [%].

3. Results

A total of 120 cholecystectomies were performed 60 for both early and delayed laparoscopic cholecystectomies. Concerning the demographic data, there was no statistical significant difference between the two groups regarding age, sex and body mass index. Grades and severity of acute cholecystitis were traced in both groups according to the clinical finding, laboratory data and imaging studies. Only grade I and grade II were included as shown in table 1.

Table 1. Grades and severity of acute cholecystitis in both groups A & B.

Item	Group A		Group B	
	Male	Female	Male	Female
Grade I	7	22	10	23
Grade II	9	22	8	19

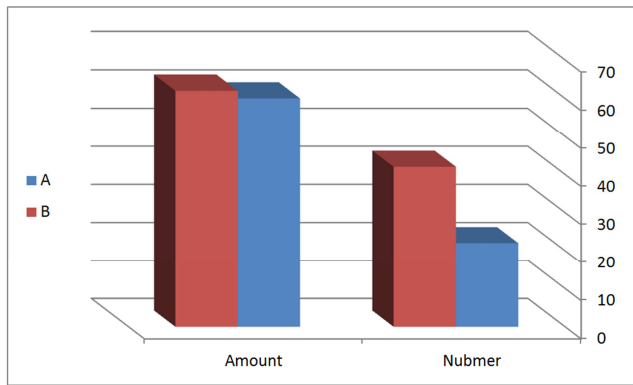
In the present study, there was neither operative nor 30 days postoperative mortality. The mean operative time was 88.62 ± 9 minutes in group B and was 96.55 ± 6.7 minutes in group A respectively showing this difference considered to be extremely statistically significant {P value ≤ 0.0001 }. The authors calculated the mean total hospital stays in days for patients in group A was 3.83 ± 5.33 days compared with 2.4 ± 1.1 days in group A with significant distribution [P ≤ 0.04].

We relied on Visual Analog Scale pain score to detect the postoperative pain experienced by our patients; Mild (1-4) = 1 point, moderate (5-7) = 2 points, severe (8-10) = 3 points. Table 2 shows the detailed descriptions of pain in both groups as well as the mean pain score this difference is considered to be extremely statistically significant. [P < 0.0001].

Table 2. Shows the detailed descriptions of pain in both groups.

Group	Mild	Moderate	Severe	Total pain score	Mean \pm SD
A	10	17	33	143	2.3 \pm 0.75
B	30	18	12	78	1.7 \pm 0.78

We observed on the day 2 postoperatively, abdominal ultrasonography revealed that the amount of intraabdominal fluid collection was ≥ 50 ml in 36.6% of patients in group A (with drain) with mean value as 60 ± 10.46 and in 70% patients in group B (without drain) with mean value as 62.5 ± 11.6 . By the day 3 postoperative, this amount got reduced with no evidence of increased amount except for 5 cases in both groups. By conventional criteria, this difference is considered to be not statistically significant {P ≥ 0.4007 } as shown in graph 1.



Graph 1. Shows the amount of intraabdominal fluid collection with number of cases in both groups.

Follow up of the 5 cases as shown in table 3, with persistent intraabdominal fluid collection revealed that three cases belonged to group B and the other 2 for group A. These patients needed readmission for serial US evaluation and image guided percutaneous aspiration.

As regard to surgical site infection, the authors detected no intraabdominal infection and only superficial wound infection was observed in the form of port site infection in three patients; two in group A and the last in group B

Table 3. Postoperative outcome and complications in both groups.

Complication	Group A		Group B		P value	T value
	Number	%	Number	%		
Pain score	143		78		0.7031 (NS)	0.3999
Residual fluid	2	(3.3)	3	(2)		
Readmission	2	(3.3)	3	(2)		
Infection	2	(3.3)	1	(1.7)		

4. Discussion

The potential function of intra-abdominal drains is to detect early postoperative bleeding and leakage of enteric suture lines and therefore prophylactic drainage has gained wide acceptance as a useful method for early detection of these complications after gastrointestinal surgery [8] while some studies have called into question the benefit of routine drainage [9, 10, 11]

As regard the operative time, it is logic that the time taken to secure the drain in the proper space will increase the operative time in drain group versus non drain group and this point met with other studies of same interest [1, 2, 8, 12].

Studies have shown that using of drain after gastrointestinal surgery is associated with postoperative pain and all patients had abdominal pain 24 hours after the operation and also analysis of the data revealed that there was significant difference in the severity of pain at the drain site whether mild, moderate or severe [13]. In our patients without drainage, the total pain score was half the value of those with drain inserted [14]. It was reported that the increase in pain in patients with drains is probably because of irritation of the peritoneum and skin at the entry point of the drains. When postoperative pain was studied in depth by assessing visual analog scale scores at different times after

surgery, the results favored the no drain group [14, 15]. Other researchers found that in elective laparoscopic cholecystectomy, abdominal pain is more prevalent in patients with a drain and on postoperative day 1, all of their patients had abdominal pain and the most prevalent site for the pain was the drain site, which is similar to results to obtained for cholecystectomy procedures [13, 16].

The use of a drain after an abdominal operation is one of the most problematic issues for surgeons and some surgeons do not recommend it. However, most surgeons use a drain at the end of the operation for early diagnosis and treatment of complications, especially leakage or bleeding [17]. Prevention of intra-abdominal collections after laparoscopic cholecystectomy is the main reason of drainage [18]. The peritoneal cavity usually absorbs serous fluids rapidly, but blood and bile are absorbed more slowly and postcholecystectomy collections in the subhepatic space are on the whole small, rapidly reabsorbed, and essentially similar in size and number whether a drain is used or not [2, 18]. The drain may also give false sense of security as it may get blocked and the patient continue to bleed internally and later presenting with signs of shock, as reported in one study [2]. Another study reported laparotomy for postcholecystectomy bile peritonitis in patients who had drains placed, suggesting that drain placement does not guarantee prevention of this complication [12, 16]. It is assumed that the use of a drain might be helpful for early detection of postoperative bleeding. However, significant bleeding can also be easily detected by clinical data and ultrasonographic imaging in the event that there is no drain [16].

Bile leak is one of the most feared complications of laparoscopic cholecystectomy (LC) for acute cholecystitis. The reported incidence for bile leak after laparoscopic cholecystectomy for acute cholecystitis is approximately 2–3% [12]. Studies from the era of open cholecystectomy showed that most patients who underwent laparotomy for postcholecystectomy bile peritonitis had drains placed, suggesting that drain placement does not detect this complication effectively [18]. In cases of excessive intraoperative blood loss, drains are not a substitute for adequate hemostasis and do not facilitate detection of hemorrhage unless bleeding is immediate and brisk [19]. Moreover, severe bleeding may be rapidly diagnosed because of postoperative hypotension, acute blood loss anemia, and intra-abdominal hypertension. Drains are also not effective to treat bleeding in elective LC [20, 21].

The drain fever syndrome after cholecystectomy was described as development of fever and right upper quadrant pain if a drain is in place for longer than 48 hours [22, 23] and this pain and fever disappeared spontaneously within 1–3 days and occurred in 23% of the group with drains and 4% in the group without drains [24]. This syndrome may be explained as follows: 1) the presence of a drain causes a foreign body reaction; 2) the drain forms a connection between the peritoneal cavity and skin; and 3) the feeling of discomfort produced by the drain prevents patients from coughing [25]. On the other hand, prophylactic drainage after acute calculous

cholecystitis is still controversial, especially for cases with pericholecystic collections, excessive adhesions or empyema [8]. Multiple reviews, trials and retrospective studies, in particular randomized clinical trials, have dealt with the issue whether to drain or not to drain such cases. However, the results of these trials are contradictory, deal with non-complicated cases and did not answer the clinical question in acute or complicated conditions [8, 10, 11].

The mean total hospital stays in days for our patients with drains is significantly longer than those without drains. Many authors reported that surgically placed drains have some risk; they have been associated with increased rates of intra-abdominal and wound infection, increased abdominal pain, decreased pulmonary function, and prolonged hospital stay [8, 15, 26, 27].

The use of drain after elective laparoscopic cholecystectomy increases wound infection rates and delays hospital discharge therefore, evidence to support the use of drain after laparoscopic or open cholecystectomy could not be found [20]. Many gastrointestinal operations can be performed safely without prophylactic drainage and drains should be omitted after hepatic, colonic or rectal resection with primary anastomosis and appendectomy for any stage of appendicitis [28]. A retrospective review found that even the complicated appendicitis (with secondary peritonitis and sepsis) in the modern era of antibiotics does not necessitate the use of prophylactic drain placement which, at times, may even prove counterproductive [29].

The authors in their previous work on scheduled laparoscopic cholecystectomy [3] found that wound infection occurred in 18.75% patients of drain group versus 5% patients in no drain group and that showed significant difference that came in consistent with other studies of same interest [12, 20, 26, 27, 30].

5. Conclusion

The present study showed that there was no added benefit for prophylactic drain insertion after cholecystectomy for acute calculous cholecystitis. Drain insertion may be a cause of delayed discharge and prolonged hospital stay after laparoscopic procedures. Increased intensity of postoperative pain and wound infection are claimed to be due to drain insertion.

References

- [1] Fahad S. Al Amri, Hala F. Ali, Abdul Rahman Nimeri, Abdul Rahman M. Al Amri, Adel A. Assiri, Mohammed I. Abdul Aziz, Mohammed A. Bawahab, Walid M Abd El Maksoud, Saeed A. Alsareii. Drainage vs. non-drainage after cholecystectomy for acute cholecystitis: a retrospective study. *J Biomed Res.* 2014 May; 28 (3): 240–245.
- [2] Shamim M. Routine Sub-hepatic Drainage versus No Drainage after Laparoscopic Cholecystectomy: Open, Randomized, Clinical Trial. *Indian J Surg.* 2013 Feb; 75 (1): 22–27.
- [3] El-Labban G, Hokkam E, El-Labban M, Saber A, Heissam K, El-Kammash S. Laparoscopic elective cholecystectomy with and without drain: A controlled randomised trial. *J Minim Access Surg.* 2012 Jul; 8 (3): 90-2.
- [4] Gurusamy KS, Samraj K. Routine abdominal drainage for uncomplicated open cholecystectomy. *Cochrane Database Syst Rev* 2007, 2, Art. No.: CD006003. DOI: 10.1002/14651858.CD006003.pub2.
- [5] Gurusamy KS, Samraj K, Mullerat P, Davidson BR. Routine abdominal drainage for uncomplicated laparoscopic cholecystectomy. *Cochrane Database Syst Rev* 2007, 4, Art. No.: CD006004. DOI: 10.1002/14651858.CD006004.pub3.
- [6] Saber A and Hokkam EN. Operative Outcome and Patient Satisfaction in Early and Delayed Laparoscopic Cholecystectomy for Acute Cholecystitis. *Minimally Invasive Surgery.* 2014 (2014); 162643: 1-4.
- [7] Yamashita Y, Takada T, Strasberg SM, Pitt HA, Gouma DJ, Garden OJ, Büchler MW, Gomi H, Dervenis C, Windsor JA, Kim SW, de Santibanes E, Padbury R, Chen XP, Chan AC, Fan ST, Jagannath P, Mayumi T, Yoshida M, Miura F, Tsuyuguchi T, Itoi T, Supe AN; Tokyo Guideline Revision Committee. TG13 surgical management of acute cholecystitis. *J Hepatobiliary Pancreat Sci.* 2013; 20 (1): 89-96.
- [8] Bawahab MA, Abd El Maksoud WM, Alsareii SA, Al Amri FS, Ali HF, Nimeri A, Al Amri AM, Assiri AA, Abdul Aziz MI. Drainage vs. non-drainage after cholecystectomy for acute cholecystitis: a retrospective study. *J Biomed Res.* 2014 May; 28 (3): 240–245.
- [9] Moshe Schein. To Drain or not to Drain? The Role of Drainage in the Contaminated and Infected Abdomen: An International and Personal Perspective. *World J Surg.* 2008; 32: 312–21.
- [10] Henrik P, Nicolas D, Valentin, Pierre-Alain C. Evidence-based Value of Prophylactic Drainage in Gastrointestinal Surgery. *Ann Surg.* 2004; 240: 1074–85.
- [11] Karliczek A, Jesus EC, Matos D, Castro AA, Atallah AN, Wiggers T. Drainage or nondrainage in elective colorectal anastomosis: a systematic review and meta-analysis. *Colorectal Dis.* 2006; 8: 259–65.
- [12] Piero Lucarelli, Marcello Picchio, Jacopo Martellucci, Francesco De Angelis, Annalisa di Filippo, Francesco Stipa, Erasmo Spaziani. Drain After Laparoscopic Cholecystectomy for Acute Calculous Cholecystitis. A Pilot Randomized Study. *Indian J Surg.* 2015; 77 (Suppl 2): 288–292.
- [13] Eidy M, Jesmi F, Raygan F, Pishgahroudsari M, Pazouki A. Evaluating the Effect of Drain Site on Abdominal Pain after Laparoscopic Gastric Bypass Surgery for Morbid Obesity: A Randomized Controlled Trial. *Bariatric Surg Pract Patient Care.* 2015 1; 10 (1): 38–41.
- [14] Marcello Picchio, Pierino Lucarelli, Annalisa Di Filippo, Francesco De Angelis, Francesco Stipa, Erasmo Spaziani. Meta-Analysis of Drainage Versus No Drainage After Laparoscopic Cholecystectomy. *JSLs.* 2014 Oct-Dec; 18 (4): e2014.00242.
- [15] Uchiyama K, Tani M, Kawai M, Terasawa H, Hama T, Yamaue H. Clinical significance of drainage tube insertion in laparoscopic cholecystectomy: a prospective randomized controlled trial. *J Hepatobiliary Pancreat Surg.* 2007; 14: 551–556.

- [16] Tzovaras G., Liakou P., Fafoulakis F, et al. Is there a role for drain use in elective laparoscopic cholecystectomy? A controlled randomized trial. *Am J Surg* 2009; 197: 759–763.
- [17] Dallal RM., Bailey L., Nahmias N. Back to basics-clinical diagnosis in bariatric surgery. Routine drains and upper GI series are unnecessary. *Surg Endosc* 2007; 21: 2268–2271.
- [18] Takada T, Kawarada Y, Nimura Y, Yoshida M, Mayumi T, Sekimoto M, Miura F, Wada K, Hirota M, Yamashita Y, Nagino M, Tsuyuguchi T, Tanaka A, Kimura Y, Yasuda H, Hirata K, Pitt HA, Strasberg SM, Gdacz TR, Bornman PC, Gouma DJ, Belli G, Liau KH. Tokyo guidelines for the management of acute cholangitis and cholecystitis. *J Hepatobiliary Pancreat Surg*, 2007, 14: 1–10.
- [19] Dougherty SH, Simmons RL. The biology and practice of surgical drains. Part II. *Curr Probl Surg*, 1992, 29: 633–730.
- [20] Gurusamy KS, Samraj K, Mullerat P, Davidson BR. Routine abdominal drainage for uncomplicated laparoscopic cholecystectomy (review). *Cochrane Database Syst Rev* (2007) 4: CD006004.
- [21] Tzovaras G, Liakou P, Fafoulakis F, Baloyiannis I, Zacharoulis D, Hatzitheofilou C. Is there a role for drain use in elective laparoscopic cholecystectomy? A controlled randomized trial. *Am J Surg* (2009) 197: 759–763.
- [22] Abbott J, Hawe J, Srivastava P, Hunter D, Garry R. Intraperitoneal gas drain to reduce pain after laparoscopy: randomized masked trial. *Obstet Gynecol*. 2001; 98: 97–100.
- [23] Liu CL, Fan ST, Lo CM, et al. Abdominal drainage after hepatic resection is contraindicated in patients with chronic liver diseases. *Ann Surg*. 2004; 239: 194–201.
- [24] Myers MB. Drain fever: a complication of drainage after cholecystectomy. *Surgery*. 1962; 52: 314–8.
- [25] Ahmet Gurer, Ersin Gurkan Dumlu, Erol Dikili, Gulten Kiyak, and Nuraydin Ozlem2. Is a Drain Required after Laparoscopic Cholecystectomy?. *Eurasian J Med*. 2013 Oct; 45 (3): 181–184.
- [26] Ammori BJ, Davides D, Vezakis A, Martin IG, Larvin M, Smith S, et al. Day-case laparoscopic cholecystectomy: a prospective evaluation of a 6-year experience. *J Hepatobiliary Pancreat Surg*. 2003; 10: 303–8.
- [27] Yeh CY, Changchien CR, Wang JY, Chen JS, Chen HH, Chiang JM, et al. Pelvic drainage and other risk factors for leakage after elective anterior resection in rectal cancer patients: a prospective study of 978 patients. *Ann Surg*. 2005; 241: 9–13.
- [28] Petrowsky H, Demartines N, Rousson V, et al; Evidence-based value of prophylactic drainage in gastrointestinal surgery: a systematic review and meta-analyses. *Ann Surg*. 2004 Dec; 240 (6): 1074-84; discussion 1084-5.
- [29] Rather SA, Bari SU, Malik AA, et al; Drainage vs no drainage in secondary peritonitis with sepsis following complicated appendicitis in adults in the modern era of antibiotics. *World J Gastrointest Surg*. 2013 Nov 27; 5 (11): 300-5.
- [30] Borzellino G, Sauerland S, Minicozzi AM, Verlato G, Di Pietrantonj C, deManzoni G, Cordiano C (2008) Laparoscopic cholecystectomy for severe acute cholecystitis. A meta-analysis of results. *Surg Endosc* 22: 8–15.