

Case Report

Emphysematous Cholecystitis a Rare and Serious Clinical Entity: A Case Report of 6 Patients

Leh Bi Kalou Ismaël^{1, *}, Bamba Inza¹, Ekra Amos Serge¹, Kouakou Blaise Amos¹, Ghassam Mzahem², Dager Nahed²

¹Department of General and Digestive Surgery, University Hospital of Bouaké, Bouaké, Côte d'Ivoire

²Centre Hospitalier Intercommunal de Villeneuve Saint-Georges, Paris, France

Email address:

klehbi@yahoo.fr (Leh Bi Kalou Ismaël)

*Corresponding author

To cite this article:

Leh Bi Kalou Ismaël, Bamba Inza, Ekra Amos Serge, Kouakou Blaise Amos, Ghassam Mzahem et al. (2023). Emphysematous Cholecystitis a Rare and Serious Clinical Entity: A Case Report of 6 Patients. *Journal of Surgery*, 11(6), 136-139. <https://doi.org/10.11648/j.js.20231106.13>

Received: November 5, 2023; **Accepted:** November 23, 2023; **Published:** December 6, 2023

Abstract: *Introduction:* Emphysematous cholecystitis or pneumocholecystitis is a condition caused by gas-forming microorganisms that cause ischemia and necrosis of the vesicular wall. It is characterized by the presence of gas in the wall and lumen of the gallbladder. Its incidence is higher in diabetics. It is a rare disease entity responsible for high mortality. However, early diagnosis combined with prompt and appropriate treatment can prevent the progression to septic shock and then death. The objective of this study was to describe the diagnostic and prognostic aspects, in order to enrich the limited literature concerning this pathology. *Patients and methods:* This was a descriptive retrospective study that ran from January 2019 to December 2021. It concerned patients admitted for emphysematous cholecystitis. *Results:* We collected 6 records of patients admitted for 6 emphysematous cholecystitis. They accounted for 1.8% of all cholecystectomies (n=278) and 4% of emergency cholecystectomies (n=112). These were 4 men (67%) and 2 women (33%). The mean age was 76.4 years. Patients generally had several histories, including the hypertension-diabetes couple, but 1 patient did not have diabetes. The average consultation time was 3 days. The clinical picture was acute generalized peritonitis in 1 patient and localized irritation to the right hypochondrium in 5 patients with septic shock. The diagnosis in all patients was made by abdominal CT scan. One patient had an ASA IV score, the other 5 patients had a score from ASA to III. In all cases, after intense resuscitation, cholecystectomy was performed, of which four (67%) were performed laparoscopically and 2 (33%) were performed by laparotomy. Bacteriology of bile fluid revealed gram-negative bacillia (*E. coli*, *Citrobacter koseri*) and gram-positive cocci (*staphylococcus aerus*) in 5 cases and 1 case of sterile fluid. The mean length of hospital stay was 5 days (range: 5-18 days). The morbidity was a case of parietal suppuration treated with local dressing. No deaths. *Conclusion:* Rare pathology. Diagnosis is essentially based on imaging, in this case abdominal CT scans. The prognosis depends on early and appropriate medical-surgical management.

Keywords: Emphysematous Cholecystitis, Abdominal CT Scan, Cholecystectomy, Emergency

1. Introduction

Emphysematous cholecystitis (EC) is a rare disease entity. It is secondary to ischemic necrosis of the gallbladder with translocation of gas-producing anaerobic germs to the vesicular wall, in its lumen or even in the perivesicular space, with high mortality, [1, 2] The pathophysiology and epidemiology of this condition differ from those of acute cholecystitis, which is related to gallstones [2].

We have collected cases at the Centre Hospitalier Intercommunal de Villeneuve Saint-Georges (France) with the aim of enriching the limited literature of this rare entity, while insisting on the diagnostic and therapeutic aspects.

2. Patients and Methods

This was a descriptive retrospective study that ran from January 2019 to December 2021. It concerned patients

admitted for emphysematous cholecystitis.

3. Results

We collected 6 records of patients admitted for emphysematous cholecystitis. They accounted for 1.8% of all cholecystectomies ($n=278$) and 4% of emergency cholecystectomies ($n=112$). These were 4 men (67%) and 2 women (37%). The mean age was 76.4 years [52 and 93 years]. The male/female ratio was 2.

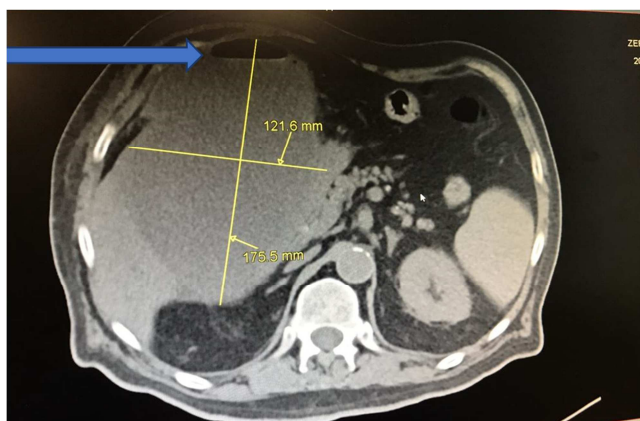


Figure 1. Axial cross-sectional abdominal CT scan showing a large gallbladder with air bubbles in the bladder wall.

Patients generally had several histories and comorbidities, including the hypertension and diabetes couple. One patient did not have diabetes. The average consultation time was 3 days. Patients were admitted for hypochondrial pain. The clinical picture was acute generalized peritonitis in one patient or localized pain without contracture or defense to the right hypochondrium in 5 patients with septic shock. There was no fever or jaundice. Tags: In biology, the mean white blood cell count was $18,000/\text{mm}^3$, predominantly neutrophils, and CRP was greater than 100. Liver work was normal. The diagnosis in all patients was made by abdominal CT scan which showed a large gallbladder with air bubbles in the wall and in the vesicular lumen suggestive of emphysematous cholecystitis (figures 1-3). The patients received an emergency pre-anesthetic consultation (APC). It led to the conclusion that one patient had an ASA IV score, the other 4 patients had an ASA III score. The mean time to care was 3 h [range: 2 and 6 h]. All patients underwent intensive pre- and post-operative medical resuscitation. She was followed by an emergency cholecystectomy, of which four (67%) were laparoscopic and 2 (33%) were laparotomy. Intraoperatively, the fluid had a purulent appearance in 2 cases, bilio-purulent in 4 cases, it was collected for cytobacteriological examination. The gallbladder was gangrenous in all cases and perforated in 1 patient. Cholecystectomy was associated with abdominal toileting and drainage in all patients. Broad-spectrum antibiotic therapy was systematically instituted postoperatively (cephalosporin + metronidazole \pm aminoglycoside). Bacteriological examination of the bile fluid revealed gram-negative *bacillia* (*E. coli*, *Citrobacter koseri*) ($n=4$) and gram-positive cocci

(*staphylococcus aerus*) ($n=1$) and in 1 liquid case was sterile. The result made it possible to adapt the susceptibility test. The mean length of hospital stay was 5 days [5 and 18 days]. The morbidity consisted of a case of parietal suppuration treated with local dressing. Mortality was zero.

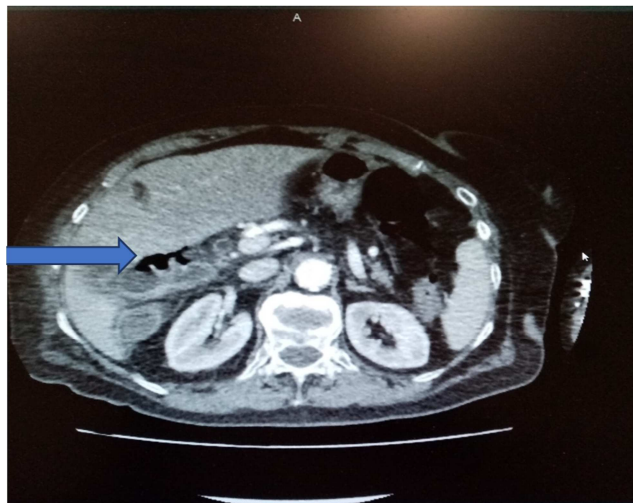


Figure 2. Axial cross-sectional abdominal CT scan showing air bubbles in the vesicular wall.

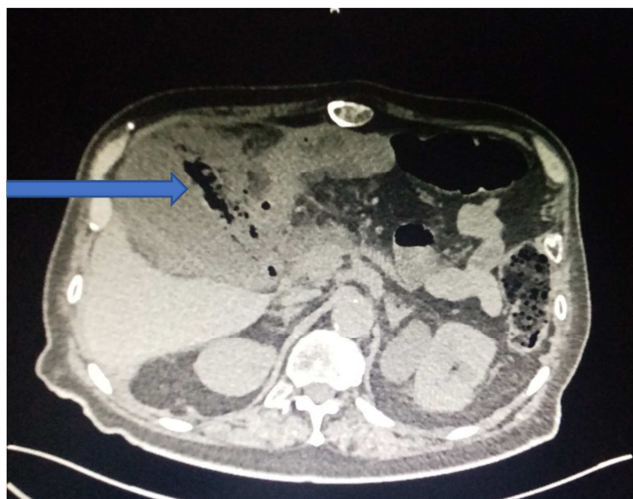


Figure 3. Axial cross-sectional abdominal CT scan showing air bubbles in the vesicular lumen.

4. Discussions

Emphysematous cholecystitis (EC) is a rare pathology as shown by several studies [2-5]. In the literature, it has not been demonstrated the presence of a clear cause but a predominance of the male subject, unlike acute cholecystitis [2, 6]. Four out of six of our patients are male, which corroborates this statement. They also differ in pathophysiology [1, 8]. In emphysematous cholecystitis, ischemia and gangrene of the gallbladder wall with gas encircling the gallbladder due to gas-producing microorganisms, namely *E. coli*, *Clostridium welchii*, *Clostridium Perfringens*, *Klebsiella*, and streptococci [9] which are the most frequently encountered germs [2, 9].

EC has always been defined as a pathology of the elderly with diabetes and also of the elderly with risk factors such as immunosuppression, peripheral vascular disease, liver disease [8-10]. In diabetics, it is thought to be due to the ischemic environment which reduces the mobility of phagocytes in the areas of infection and also further reduces antimicrobial activity [9, 10].

However, cases of young subjects without risk factors have been described in the literature [8, 9]. In our series, admittedly five (5) of our patients presented the typical picture of the elderly subject with metabolic and cardiovascular risk factors, but we also have a young patient. Clinical signs are non-specific [6, 7, 9]. It is therefore difficult to differentiate clinically from acute cholecystitis. Most often, the clinical picture is not alarming, with apyrexia in a third of cases [11], pain reduced by diabetic neuropathy. Signs of peritonitis are present in 40% of cases and septic shock in 10% of cases. Biologically, there is neutrophil polynuclear leucocytosis (absent in a third of cases) associated with an inflammatory syndrome [7].

Diagnosis is mainly based on imaging, mainly abdominal CT [2, 6]. Abdominal CT scan shows the presence of gas surrounding the gallbladder or gas in the gallbladder which is the typical presentation of emphysematous cholecystitis [7, 10].

It also eliminates differential diagnoses such as incompetence of the sphincter of Oddi, fistulous communication between the gastrointestinal tract and the biliary system, abscess due to gas formation infection caused by microorganisms originating outside the bile ducts, gas in the duodenal ampulla, perigastric or periduodenal abscesses, lipomatosis of the gallbladder [1].

But the diagnosis can also be made by ASP, which in the 70s was the only imaging technique [1], as shown by the case described in 1974 by Abengowe et al. There is a gaseous halo around the gallbladder and a level of liquid gas in the gallbladder. It can also sometimes be diagnosed by ultrasound with the effervescent vesicle image [6].

In our study, the diagnoses were all made by abdominal CT scan. Emphysematous cholecystitis is a medical-surgical emergency. As soon as the diagnosis is made, preoperative antibiotic therapy active on anaerobic germs is instituted quickly combined with emergency cholecystectomy [1, 2, 8].

This cholecystectomy, according to some authors, must be done laparoscopically. This approach is increasingly used nowadays unlike laparotomy, due to its multiple advantages [4, 8, 12]. But in emphysematous cholecystitis, laparotomy is still used because of the difficulty of dissection due to the anatomical distortion caused by acute inflammation and poor condition of patients [4, 8]. It is true that a study in the United States involving 18 patients carried out by Hazey et al demonstrated that laparoscopy gave good results with a low conversion rate [13]. Another method of treatment, involves an initial percutaneous cholecystotomy with a strict intravenous antibiotic regimen, followed by subsequent cholecystectomy for a second stage [1, 5].

In case of surgical contraindication, treatment is based on

percutaneous biliary drainage. Some authors discuss the value of hyperbaric oxygen therapy as an adjuvant treatment [6]. We operated on four patients laparoscopically without conversion and two laparotomy, it was an operator's choice. The results were satisfactory by any approach. As in the literature, the germs involved in our patients were gram-negative *E. coli*, *Citrobacter koseri* and gram-positive cocci *staphylococcus aerus* [6, 8]. One of the patients had sterile peritoneal fluid, a case of bile fluid was also described by Naouri et al. Postoperative outcomes are often favourable if antibiotic therapy is adapted to susceptibility testing [5, 8, 13].

5. Conclusion

Rare pathology. Diagnosis is essentially based on imaging, in this case abdominal CT scans. The prognosis depends on early and appropriate medical-surgical management.

ORCID

Leh Bi Kalou Ismaël:
<https://orcid.org/0000-0003-4197-9086>

Conflicts of Interest

Authors declare that they have no relationship of interest.

References

- [1] C. U. Abengowe, P. J. M. McManamon. Acute emphysematous cholecystitis. CMA JOURNAL 1974; 111: 1112-4.
- [2] Dossouvi Tamegnon, N'Timon Bidamin, Dagbe Massaga, Sorsy Eyram, Adabra Komlan, Elias Césaire et al. Emphysematous cholecystitis: about a case. Emphysematous cholecystitis. MALI MEDICAL 2015; VOLUME 30(2): 53-54.
- [3] C. Simon · J. Oliveira · X. Fountain. Biliary peritonitis on emphysematous cholecystitis and *Clostridium perfringens* hepatic abscess. Ann. Fr. Med. Emergency 2019; 9: 44-5.
- [4] George Bouras, Sorinel Lunca, Michel VixMD Jacques Marescaux. A Case of Emphysematous Cholecystitis Managed by Laparoscopic Surgery. JSLS. 2005; 9(4): 478-80.
- [5] Hiroyuki Miyahara, Dai Shida, Hiroki Matsunaga, Yukiko Takahama, Sachio Miyamoto. Emphysematous cholecystitis with massive gas in the abdominal cavity. *World J Gastroenterol* 2013; 19(4): 604-06.
- [6] D. Naouri, R. Rozenfeld, O. Ganansia. Cholecystitis emphysematous: a rare and underestimated emergency. Ann. Fr. Med. Emergency 2014; 4: 415-16.
- [7] O. Mercier, H. Kotobi, G. Godiris-Petit. Gallot. Emphysematous cholecystitis: a pathological entity. About a case. *Annals of Surgery* 128. 2003; 716-8.
- [8] Supreet Khare, Aswini K Pujahari. A rare case of emphysematous cholecystitis. J Clin Diagn Res 2015; 9 (9): 13-4.

- [9] Ming-Yu Chen, Chen Lu, Yi-fan Wang, Xiu-Jun Cai. Emphysematous cholecystitis in a young male without predisposing factors. *Medicine* 2016; 95(44): 1-4.
- [10] Asli Tanrivermis Sayit, Hediye Pinar Gunbey. Emphysematous Cholecystitis in 24-Year-old Male Without Predisposing Factors. *Journal of Clinical and Diagnostic Research*. 2015; 9(7): 1-2.
- [11] Lindsey I, Kitchen G, Leung D. Emphysematous cholecystitis. *Aust N Z J Surg* 1996; 66: 267–8.
- [12] Hideki Katagiri, Yasuo Yoshinaga, Yukihiro Wear, Ken Mizokami. Emphysematous Cholecystitis Successfully Treated by Laparoscopic Surgery. *Journal of Surgical Case RepLocation* 2014; 4: 1-2.
- [13] J. W. Hazey, F. J. Brody, S. M. Rosenblatt, J. Brodsky, J. Malm, J. L. Ponsky. Laparoscopic management and clinical outcome of emphysematous cholecystitis. *Surg Endosc* 2001; 15: 1217-20.