

Report

Acute Cholecystitis VS Fitz-Hugh-Curtis Syndrome: A Case Report and Literature Review

Rabia Ikram^{1,*}, Ali Hassan², Anam Waseem³¹General Surgery, District Head Quarter Hospital, Sahiwal, Pakistan²Anatomy, Sahiwal Medical College, Sahiwal, Pakistan³Department of Public Health, Cornell University, Ithaca, United States**Email address:**

rabiaikramch@hotmail.com (Rabia Ikram), alihasan60@hotmail.com (Ali Hassan), anam.waseem24@gmail.com (Anam Waseem)

*Corresponding author

To cite this article:Rabia Ikram, Ali Hassan, Anam Waseem. Acute Cholecystitis VS Fitz-Hugh-Curtis Syndrome: A Case Report and Literature Review. *Journal of Surgery*. Vol. 11, No. 1, 2023, pp. 1-4. doi: 10.11648/j.js.20231101.11**Received:** October 21, 2022; **Accepted:** February 1, 2023; **Published:** February 9, 2023

Abstract: A young married lady presented with right upper quadrant pain and after clinical assessment and investigations she was diagnosed with calculus cholecystitis. An elective laparoscopic cholecystectomy was planned, but on getting the entry in the peritoneal cavity an interesting view was encountered. There were dense adhesions in the right upper abdomen, liver adherent to the abdominal wall and a normal looking gallbladder with bluish hue and few tiny intraluminal stones. There was peri-hepatitis with bilateral inflamed fallopian tubes. The patient was diagnosed with Fitz-Hugh-Curtis syndrome (FHCS), a complication of pelvic inflammatory disease. Treatment is hence directed towards the underlying cause. FHCS is a diagnosis of exclusion and confirmed on laparoscopic exploration. Cervical swabs and samples of fluid taken from the peritoneum and liver surface can aid in diagnosis. The most common organisms are *Chlamydia trachomatis* and *Neisseria gonorrhoeae*. Although most of the patients are young women, there are case reports of this entity in men as well. Management is to treat the underlying PID. Laparoscopic release of peri-hepatic bands may aid in pain relief. Complications include sepsis, infertility, and adhesive bowel disease. This may not be a common disease, but it can leave permanent scars. The underlying PID should be treated urgently to minimize the collateral damage. Education and couple therapy is important as prevention is the best treatment.

Keywords: Perihepatitis, Fitz-Hugh-Curtis Syndrome, Pelvic Inflammatory Disease

1. Introduction

Carlos Stajano had first described the association of PID (pelvic inflammatory disease) and adhesion on the anterior surface of liver in 1920 to the Society of Obstetricians and Gynecologists of Montevideo in Uruguay. In 1930 and 1934, Arthur Curtis & Thomas Fitz-Hugh, respectively described unusual presentation of upper right quadrant abdominal pain and PID (pelvic inflammatory disease). They found peculiar “violin string” adhesion between the anterior surface of the liver and the abdominal wall on laparotomy of these patients. Of note were absent upper abdominal pathology, while symptomatic and non-symptomatic PID were present in all patients with positive organism isolation on taking fluid samples. Later,

A. Curtis observed that this pattern of adhesion is unique to PID induced peritonitis. Smears of fluid taken from high vaginal swab, cervix, fallopian tubes and from the liver capsule adhesion as well show gonococcal infection, but now it's known that, however this presentation is not exclusive to gonococcal infection. Fitz-Hugh Curtis syndrome is a diagnosis of exclusion (by excluding other abdominal pathology) and confirmed on laparoscopy [1-6].

2. Case Presentation

A 20-year-old, housewife presented in the OPD of the district headquarter hospital with a complaint of pain in the right upper abdomen along with mild nausea and one episode of vomiting for two weeks.

2.1. Clinical Examination

Apparently, a healthy looking female with mild tenderness in the right upper abdomen. No palpable mass or organomegaly.

2.2. Past History

The patient suffered from pulmonary tuberculosis in adolescence. No other known comorbidity.

2.3. Medication

She has taken ATT (anti-tuberculosis treatment) for 9 months in adolescence. Now she is seeking infertility treatment.

2.4. Investigation

Her ultrasound shows tiny stones in the gallbladder, with an accumulative size of 4mm, a wall thickness of 2mm, and a peri-cholecystic streak of fluid emphasizing acute inflammation. WBC 12.4, Hb 12.1, platelets 206,000, ALT 48, AST 41, ALP 348, Anti HCV, HBsAg and HIV non-reactive.

2.5. Management

After appropriate antibiotic cover and analgesics, the patient has been booked for elective laparoscopic cholecystectomy on 25th February, 2020.

The procedure has been carried out under general anesthesia, with the patient in reverse Trendelenburg's position. On insertion of the camera, a web of multiple perihepatic adhesion (perihepatitis) was found along with adhesion in the rest of the abdomen. The anterior surface of the liver is adherent to the abdominal wall. Pylorus of the stomach adherent to the liver with a band. Thin-walled, distended gallbladder and omentum stuck to it. What was particular in this patient was edematous and inflamed fallopian tubes. Difficult case due to adhesion and inflammation in Calot's triangle as well. We proceeded with cholecystectomy and release of peri-hepatic adhesion. Fluid samples were taken for culture and sensitivity.

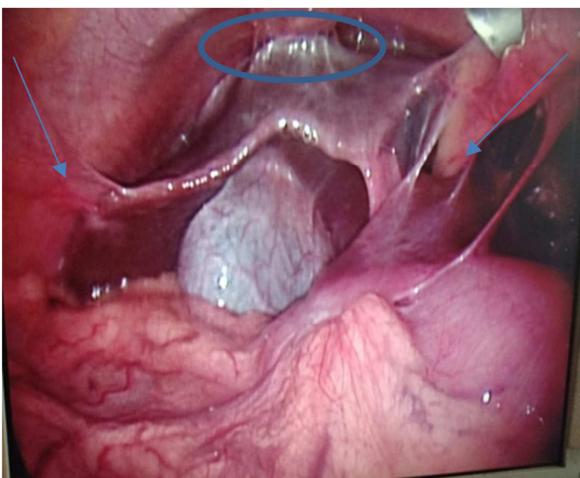


Figure 1. A laparoscopic view of the right hypochondrium shows typical violin string adhesion of the liver with the abdominal wall. (Picture of the screen taken as at that time we didn't have a recording facility available without laparoscopic apparatus).

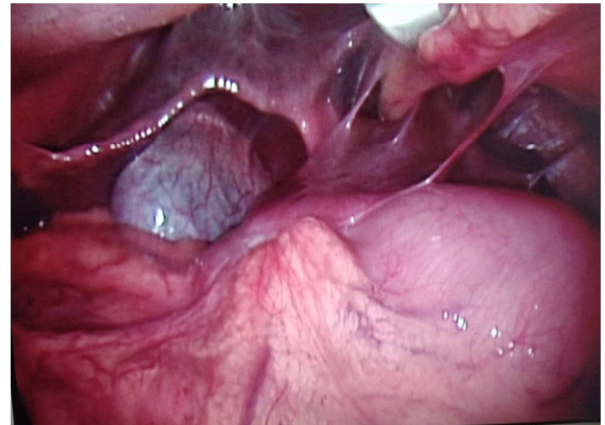


Figure 2. Web of adhesion on getting entry in the abdomen.

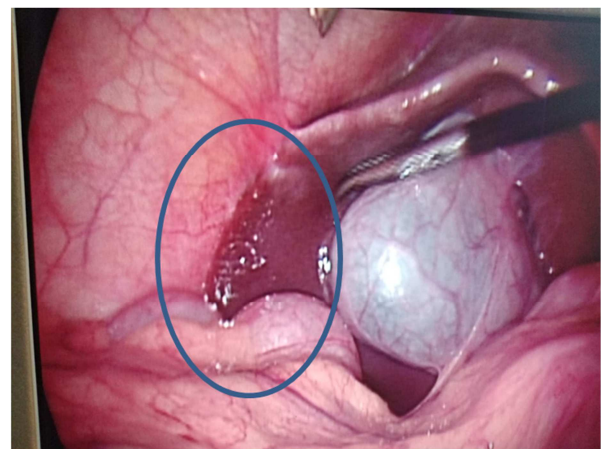


Figure 3. Lateral edge of the liver densely adherent to the abdominal wall.

2.6. Histopathology

Gallbladder, non-inflamed with tiny intra-luminal stones.

2.7. Culture and Sensitivity

Later on, high vaginal swab was taken and patient was treated for Neisseria gonorrhea as per the culture and sensitivity report. Smears of fluid taken from the peritoneal cavity were negative for acid-fast (Ziehl-Neelsen staining) considering the previous history of pulmonary tuberculosis.

2.8. Follow-up

We lost the follow-up of the patient at 1-year post-surgery. After 2 and half years she contacted me again, as she is still struggling with recurrent attacks of lower abdominal pain along with per vaginal discharge. She has been taking antibiotics on and off at different prescriptions and by herself over the counter. She is still struggling with infertility and wishes to conceive.

3. Discussion

A rare presentation of chronic PID (pelvic inflammatory disease) is Fitz-Hugh-Curtis syndrome (FHCS) or perihepatitis. It is an inflammation of the liver capsule, without the involvement of liver parenchyma. There is

extensive adhesion formation in the upper right quadrant resulting in pain arising in the upper right abdomen [7-9].

3.1. Differential Diagnosis

This is a diagnosis of exclusion, many abdominal pathologies present with the same set of presentation, cholecystitis, appendicitis, pancreatitis, acute viral hepatitis, liver abscess, GERD, duodenal ulcer, pyelonephritis, ectopic pregnancy, and many others. As well as lower right lobe pneumonia, herpes zoster, etc. [10-12].

3.2. Incidence

About 4-27% of women afflicted with PID can present with FHCS. This entity is more seen in adolescence and in younger women with early sexual activity [8, 13].

3.3. Presentation

Young sexually active women with pain in the right upper abdomen is the most common presentation. At times it is also associated with pain in the lower abdomen as well. Fever, malaise, nausea, vomiting, and vaginal discharge may or may not be a presentation [14, 15].

3.4. Pathogenesis

The pathogenesis of Fitz-Hugh-Curtis syndrome is still a dilemma. Many theories have been proposed over the years about the possible links between PID and perihepatitis. Some propose spillage of organisms through the fallopian tube and direct invasion of the peritoneal linings. While other theories support lymphatic spread; although the lymphatic drainage of the female reproductive organs is retroperitoneal. Suggestions of hematogenous spread of the disease are also found in the literature, presentation of this entity in males supports this mode of spread. There are also advocates of the unleashed immune response to these bugs as the culprit for this entity. [16-22].

3.5. Investigation

CBC and metabolic profile, HCV, HBV, and HIV screening along with pregnancy test. Cultures of the vaginal smears and of fluid obtained from the abdomen. Laparoscopy exploration of the abdomen is the most authentic way to confirm this diagnosis. But some studies show that ultrasound and CT (computed tomography) scans may aid in diagnosis before exploration [23-25].

3.6. Treatment

Treating the underlying pelvic inflammatory disease is the management of FHCS. In severe cases, one can start with empirical treatment directed toward more common bugs of *C. trachomatis* and *N. gonorrhea*, while getting culture and sensitivity reports of the taken fluid samples. WHO and CDC recommend regular screening of sexually active women and prompt urgent treatment of PID [26]. Laparoscopic release of adhesion, especially in the peripartetic area helps with pain relief [27].

4. Judicial Use of Antibiotics

Unfortunately, in Pakistan prescribing broad spectrum antibiotics without infectious disease and microbiology consultation is a norm. What makes it even worse is over the counter availability of antibiotics. This combined lead to multidrug resistant organisms. Hence a simple infection turns into a systemic disease and leaves a permanent scar.

5. STD

Sexually transmitted diseases are better prevented than treated. In Pakistan, we are still struggling with educating our youth about safe sex practices and couple therapies.

6. Complications

Sepsis, infertility, and adhesive bowel disease are the most common complications [28, 29].

7. Conclusion

Fitz-Hugh-Curtis syndrome is an uncommon complication of PID presenting in general surgery. It is difficult to diagnose, as symptoms overlap with many other surgical diseases. Imaging can help but laparoscopic exploration is the gold standard and saves patients for a conventional laparotomy. PID if not treated early can lead to sepsis and permanent damage. We recommend a multidisciplinary approach to the management of this disease.

Abbreviations

ATT: Anti-Tuberculosis Treatment
 CDC: Centers for Disease Control and Prevention
 FHCS: Fitz-Hugh-Curtis Syndrome
 PID: Pelvic Inflammatory Disease
 WHO: World Health Organization

References

- [1] Curtis A (1930) A cause of adhesions in the right upper quadrant. *JAMA* 94: 1221-1222.
- [2] Curtis A (1932) Adhesions of the anterior surface of the liver. *JAMA* 99: 2010-2012.
- [3] Fitz-Hugh TJ (1934) Acute gonococcal peritonitis of the right upper quadrant in women. *JAMA* 102: 2094-2096.
- [4] Muller-Schoop JW, Wang SP, Munzinger J, Schlapfer HU, Knoblauch M, Tammann RW (1978) Chlamydia trachomatis as possible cause of peritonitis and perihepatitis in young women. *Br Med J* 1: 1022-1024.
- [5] Dalaker K, Gjonnaess H, Kvile G, Urnes A, Anestad G, Bergan T (1981) Chlamydia trachomatis as a cause of acute perihepatitis associated with pelvic inflammatory disease. *Br J Vener Dis* 57: 41-43.
- [6] Shanahan D, Gau D (1986) Chlamydial Fitz-Hugh/Curtis syndrome. *Lancet* 1 (8491): 1216.

- [7] Stajano C (1920) La reaccion frenica en ginecologia. *Sem Med* 27: 243–248.
- [8] Basit H, Pop A, Malik A, et al. Fitz-Hugh-Curtis Syndrome. [Updated 2022 Jul 4]. In: StatPearls [Internet]. Treasure Island (FL): StatPearls Publishing; 2022 Jan-. Available from: <https://www.ncbi.nlm.nih.gov/books/NBK499950/>
- [9] Durastante V, Conte L, Cinque A, et al., Venereal perihepatitis: Fitz-Hugh-Curtis syndrome. *Minerva Chir.* 1995; 50: 793-8.
- [10] Kazama I, Nakajima T. A case of fitz-hugh-curtis syndrome complicated by appendicitis conservatively treated with antibiotics. *Clin Med Insights Case Rep.* 2013; 6: 35-40. doi: 10.4137/CCRep.S11522. Epub 2013 Mar 4. PMID: 23515004; PMCID: PMC3596056.
- [11] Katzman DK, Friedman IM, McDonald CA, Litt IF. Chlamydia trachomatis Fitz-Hugh-Curtis syndrome without salpingitis in female adolescents. *Am J Dis Child.* 1988; 142: 996-8.
- [12] Kaan JA, Branger J, van Ampting JM, Speelman P. Fitz-Hugh-Curtis syndrome: 2 patients with perihepatitis and sepsis. *Ned Tijdschr Geneesk.* 2002; 146: 954-7.
- [13] Wang PY, Zhang L, Wang X, Liu XJ, Chen L, Wang X, Wang B. Fitz-Hugh-Curtis syndrome: clinical diagnostic value of dynamic enhanced MSCT. *J Phys Ther Sci.* 2015 Jun; 27 (6): 1641-4. doi: 10.1589/jpts.27.1641. Epub 2015 Jun 30. PMID: 26180288; PMCID: PMC4499951.
- [14] Theofanakis, C. P., Kyriakidis, A. V. Fitz-Hugh–Curtis syndrome. *Gynecol Surg* 8, 129–134 (2011). <https://doi.org/10.1007/s10397-010-0642-8>
- [15] Peter NG, Clark LR, Jaeger JR. Fitz-Hugh-Curtis syndrome: a diagnosis to consider in women with right upper quadrant pain. *Cleve Clin J Med.* 2004; 71: 233-9.
- [16] Holm-Nielsen P (1953) Right upper quadrant pain in salpingitis and other abdominal diseases explained by adsorption of exudates from the peritoneal cavity through the diaphragm. *Acta Chir Scan* 104: 435–446.
- [17] Onsrud M (1979) Perihepatitis in salpingitis. Fitz-Hugh–Curtis syndrome. *Tidsskr Nor Laegeforen* 99 (33): 1705–1706.
- [18] Lopez-Zeno JA, Keith LG, Berger GS (1985) The Fitz-Hugh–Curtis syndrome revisited. Changing perspectives after half a century. *J Reprod Med* 30: 567–582.
- [19] Money DM, Hawes SE, Eschenbach DA, Peeling RW, Brunham R, Wolner-Hanssen P et al (1997) Antibodies to the chlamydial 60 kd heat-shock protein are associated with laparoscopically confirmed perihepatitis. *Am J Obstet Gynecol* 176 (4): 870–877.
- [20] Kwon OJ, Lee SW, Jang MS, Kim SC, Lee JH, Kim H. A rare case of miliary tuberculosis accompanying perihepatitis. *Clin Exp Emerg Med.* 2019 Sep; 6 (3): 264-267.
- [21] Coremans L, de Clerck F. Fitz-Hugh-Curtis syndrome associated with tuberculous salpingitis and peritonitis: a case presentation and review of literature. *BMC Gastroenterol.* 2018 Mar 20; 18 (1): 42.
- [22] Saurabh S, Unger E, Pavlides C. Fitz -Hugh-Curtis syndrome in a male patient. *J Surg Case Rep.* 2012 Mar 1; 2012 (3): 12. doi: 10.1093/jscr/2012.3.12. PMID: 24960816; PMCID: PMC3649509.
- [23] Wu HM, Lee CL, Yen CF, Wang CJ, Soong YK. Laparoscopic diagnosis and management of Fitz-Hugh-Curtis syndrome: report of three cases. *Chang Gung Med J.* 2001; 24: 388-92.
- [24] Wang C, Guo X, Yuan Z, Shi Q, Hu X, Fang L (2009) Radiologic diagnosis of Fitz-Hugh–Curtis syndrome. *Chin Med J* 122 (6): 741–744.
- [25] Sam JW, Jacobs JE, Birnbaum BA (2002) Spectrum of CT findings in acute pyogenic pelvic inflammatory disease. *Radiographics* 22: 1327–1334.
- [26] Workowski KA, Bolan GA; CDC. Sexually transmitted diseases treatment guidelines, 2015. *MMWR Recomm Rep* 2015; 64 (No. RR-3). PMID: 26042815.
- [27] Owens S, Yeko TR, Bloy R, Maroulis GB. Laparoscopic treatment of painful perihepatic adhesions in Fitz-Hugh-Curtis syndrome. *Obstet Gynecol.* 1991; 78: 542-3.
- [28] Onoh RC, Mgbafuru CC, Onubuogu SE, Ugwuoke I. Fitz-Hugh-Curtis syndrome: An incidental diagnostic finding in an infertility workup. *Niger J Clin Pract.* 2016 Nov-Dec; 19 (6): 834-836. [PubMed].
- [29] Al-Ghassab RA, Tanveer S, Al-Lababidi NH, Zakaria HM, Al-Mulhim AA. Adhesive Small Bowel Obstruction due to Pelvic Inflammatory Disease: A Case Report. *Saudi J Med Med Sci.* 2018 Jan-Apr; 6 (1): 40-42.