

A Giant Lipoblastoma in a 13-month-old Girl: A Case Report

Maamatou Wafa*, Trabelsi Fatma, Jarray Leila, Daib Aida, Ben Abdallah Rabiaa, Jabloun Asma, Hellel Youssef, Gharbi Youssef, Kaabar Nejieb

Paediatric Surgery Department, Habib Thameur Hospital, Tunis, Tunisia

Email address:

wafa.maamatou@hotmail.fr (Maamatou Wafa)

*Corresponding author

To cite this article:

Maamatou Wafa, Trabelsi Fatma, Jarray Leila, Daib Aida, Ben Abdallah Rabiaa, Jabloun Asma, Hellel Youssef, Gharbi Youssef, Kaabar Nejieb. A Giant Lipoblastoma in a 13-month-old Girl: A Case Report. *Journal of Surgery*. Vol. 10, No. 5, 2022, pp. 180-183. doi: 10.11648/j.js.20221005.17

Received: February 14, 2022; **Accepted:** October 11, 2022; **Published:** October 28, 2022

Abstract: Lipoblastoma is a relatively rare benign soft tissue tumor. It most often occurs in the small child, less than 3 years old. There is a male predominance with a sex ratio of 3/1. Lipoblastoma usually present as a rapidly growing mass most often located in the trunk and extremities. It is extremely rare on the head and neck. Usually, this tumor is asymptomatic, but it can become so due to its size and location. The contribution of imaging is essential in the diagnostic approach of this tumor. Essentially, MRI confirms the fatty nature of the tumor and the heterogeneous aspect in relation to the enhancement of the fibrovascular septa. However, the definitive diagnosis is histopathological through a surgical biopsy, which eliminates a malignant tumor at the same time. The treatment of choice is complete surgical resection of the tumor. No malignant degeneration has been documented while a high recurrence rate has been described and is usually correlated to the diffuse-type lesions (lipoblastomatosis) and to incomplete excision. We report the case of a 13-month-old girl presented with a swelling of the left buttock that had been evolving for 4 months, with a very significant increase in size during the last month. The diagnosis of lipoblastoma was suspected clinically and on radiological explorations. This diagnosis confirmed histologically. The treatment was surgical. It consisted in a total resection of the mass. The postoperative evolution was simple with a current follow-up of one year.

Keywords: Lipoblastoma, Giant Tumor, Infant, Surgery

1. Introduction

Lipoblastoma, first described by Jaffe [1] in 1926, is an uncommon soft tissue tumor. It is a rare benign tumor of white fat of embryonic origin. Lipoblastomatous lesions contain a spectrum of fat cells ranging from immature lipoblasts to mature adipocytes [2]. It is important to understand the pathology and differential diagnosis of a lipoblastoma that may resemble a liposarcoma [3]. It appears almost exclusively in small children (under 3 years old). There is a male predominance. About 70% of these tumors occur in the extremities, trunk, head and neck.

We report a case of lipoblastoma in a 13-month-old girl, who presented a swelling of the left buttock evolving since the age of 9 months.

2. Case Report

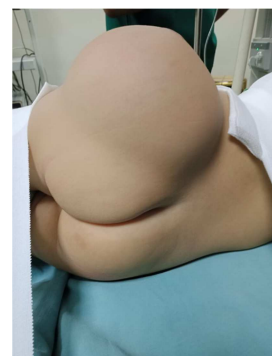


Figure 1. Swelling of the left buttock, without local inflammatory signs, measuring 13 cm of long axis.

A 13-month-old girl presented with a swelling of the left buttock that had progressed for 4 months, with a very significant increase in size in the last month. There was no pathological history. On local examination, a swelling of the left buttock 13 cm long. It was soft, painless on palpation and without local inflammatory signs (Figure 1).

Radiological explorations (ultrasound and MRI) (Figures 2, 3) were in favour of a lipomatous-like formation of 7 to 8 cm in diameter, embedded in hypodermic cellulo-fatty tissue, encapsulated. This formation is the seat of large spans more or less thick, these show a contrast enhancement.

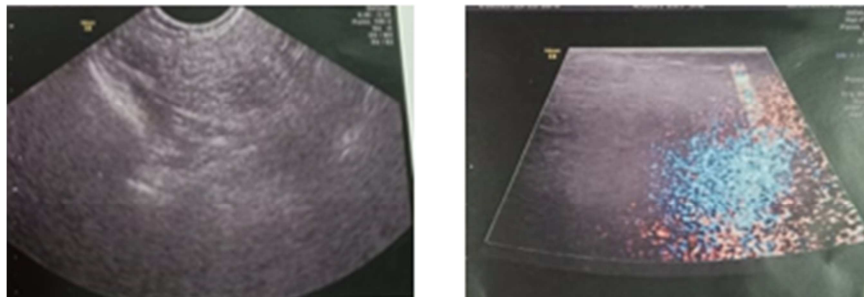


Figure 2. Lipomatous-like formation of 7 cm long axis, circumscribed intrahypodermal, without vascularization on color Doppler.

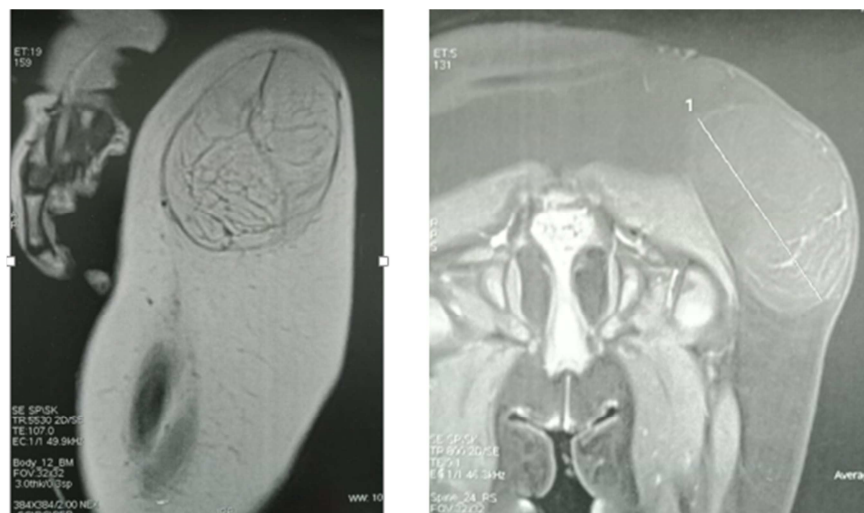


Figure 3. Voluminous formation of lipomatous appearance, well encapsulated, measuring 8 cm long axis, seat of broad spans more or less thick showing a contrast enhancement.

In the face of diagnostic doubt, a biopsy is indicated before surgery. This last was in favour of a lipoblastoma of the buttock. A complete resection of the tumor (Figures 4, 5) is made with simple suites.

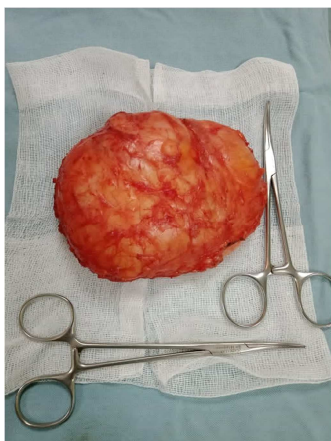

Figure 4. Macroscopic aspect of the mass.

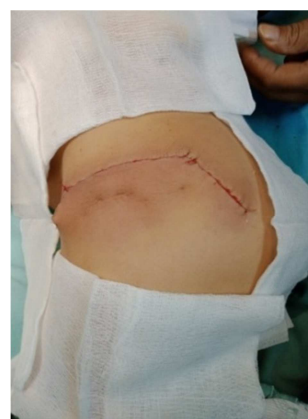

Figure 5. Postoperative aspect of the left buttock after complete resection of the tumor.

The final histological examination concluded to a lipoblastoma with complete excision.

The patient was followed up regularly. The postoperative clinical checks did not show any recurrence of the tumor.

3. Discussion

Lipoblastoma is a relatively rare tumor, which almost exclusively affects infants and children under 3 years old with an average age of 12 months [4, 5]; as was the case in our reported observation (a 13-month-old girl).

There is a male predominance with a sex ratio of 3/1 [5, 6]. On the other hand, we report the case of a girl.

The majority of these tumors affect the subcutaneous tissues of the extremities and trunk [4, 7]. They are extremely rare on the head and neck: a total of 48 cases of head and neck lipoblastoma have been reported in the English literature [8]. Intrascrotal lipoblastoma is even rarer, and only 11 cases have been reported [9]. For our patient, the location was at the level of the left buttock.

Usually, lipoblastoma is asymptomatic, but it can become so due to its size and location [5, 10]. Progressive hypertrophy and painless swelling dominate the clinical picture [7]. Our patient was asymptomatic despite the size of the tumor was quite large.

This tumor comes in two forms, either a well-defined, encapsulated tumor (benign lipoblastoma), or non-encapsulated, infiltrating and diffuse (lipoblastomatosis). Lipoblastoma, the focal circumscribed form, tends to occur superficially and macroscopically it seems to be a lipoma while lipoblastomatosis, the diffuse and infiltrative form, tends to occur in deeper tissue and has a higher recurrence rate [5, 11, 12].

The contribution of imaging is essential in the diagnostic approach of these tumors. Ultrasound may reveal a heterogeneously structured mass, lobulated, that may contain cystic formations within it. MRI, by its non-invasive and non-irradiating nature, is often preferred to computed tomography. It confirms the fatty nature of the tumor and the heterogeneous appearance in relation to the enhancement of the fibrovascular septa. It also allows the analysis in the three planes of space of the relations of the tumor with the adjacent organs and the vasculo-nervous structures. The lipoblastoma presents a very limited appearance with T1 hypersignal, intermediate signal or T2 hypersignal and signal cancellation on fat suppression sequences [6, 9, 13, 14]. The aspect of the MRI of our patient is comparable to that described in the literature.

The definitive diagnosis is histopathological through a surgical biopsy, which eliminates a malignant tumor at the same time, this is the attitude taken in our case.

The treatment of choice for lipoblastoma is complete surgical resection [14]. The local recurrence rate is 14 to 25%, especially when the resection is incomplete [15]. For our observation, the resection was complete with a current follow-up of one year.

Prognosis is excellent after complete excision even in large tumors. However, close follow up for minimum of 5 years is recommended.

4. Conclusion

Lipoblastoma is a rare, benign and encapsulated tumor.

MRI guides the diagnosis.

Diagnostic confirmation is always histological. The standard treatment is complete surgical excision to avoid leaving residual tumor and to prevent recurrences. This tumor has an excellent prognosis. Metastases have never been described.

Disclosure

The authors declared no conflicts of interest.

Acknowledgements

The authors would like to thank all the participants for their time and valuable input.

References

- [1] Jaffe RH. Recurrent lipomatous tumor of the groin: liposarcoma and lipoma pseudomixomatodes. *AMA Arch Pathol* 1926; 1: 381-7.
- [2] Aea Tommaso. Lipoblastoma in infant: our experience. *J Pediatric Surg Case Rep*, 3 (2015), pp. 63-64.
- [3] Austin Lunney, Karla Leal, John Fitzwater. "Supraclavicular lipoblastoma", *J Pediatric Surg Case Rep*, 41 (2019), pp 24-26.
- [4] Al-Salem A H, Al-Nazer M. Mesenteric lipoblastoma in a 2-year-old child. *Pediatric Surg Int*. 2003; 19 (1-2): 115-7. PubMed | Google Schola.
- [5] Besouw MT, Verlinde PF, Uyttebroeck AM, Renard MM. Lipoblastoma and lipoblastomatosis: especially in children. *Ned Tijdschr Geneesk*. 2011; 155 (33): A3467.
- [6] Kriaa S, Moussa A, Nouri A et al. Lipoblastoma omental: à propos d'un cas. *J Radiol*. 2005; 86: 1808-9. PubMed | Google Scholar.
- [7] Kerkeni Y, Sahnoun L, Ksia A et al. Lipoblastoma in childhood: about 10 cases. *Afr J Paediatr Surg*. 2014; 11 (1): 32-4.
- [8] Nguyen S, Pham A, Brian Poirier B et al. Pediatric lipoblastoma in the head and neck: a systematic review of 48 reported cases. *International Journal of Pediatric Otorhinolaryngology*. 2010; 74 (7): 723-728. PubMed | Google Scholar.
- [9] Yada K, Ishibashi H, Mori H, Shimada M. Intrascrotal lipoblastoma: report of a case and the review of literature. *Surg Case Rep*. 2016 Dec; 2 (1): 34. PubMed | Google Scholar.
- [10] Mognato G, Cecchetto G, Carli M et al. Is Surgical Treatment of lipoblastoma always necessary? *J Pediatr Surg*. 2000; 35 (10): 1511-13. PubMed | Google Schola.
- [11] Fallon SC, Brandt ML, Rodriguez JR, et al. Cytogenetic analysis in the diagnosis and management of lipoblastomas: result from a single institution. *J Surg Res* 2013; 184 (1): 341- 6.
- [12] Adnani A, Chellaoui M, Chat L et Dafiri. Aspect inhabituel d'un lipoblastome axillaire chez un nourrisson. *J Radiol*. 2005; 86 (9): 1043-5. PubMed | Google Scholar.

- [13] Susam-Sen H, Yalcin B, Kutluk T, et al. Lipoblastoma in children: review of 12 cases. *Pediatr Int.* 2017; 59 (5): 545–50.
- [14] Nam-Yong Do, Sung-Il Cho, Jun Hee Park et al. Lipoblastoma arising from the submandibular region. *Journal of Pediatric Surgery.* 2008; 43 (11): E13-E15. PubMed | Google Scholar.
- [15] Abdul Ghafar J, Ahmad Z, Tariq MU, Naila Kayani N and Uddin N. Lipoblastoma: a Clinicopathologic review of 23 cases from a major tertiary care center plus detailed review of literature. *BMC Res Notes* (2018) 11: 42.