

# Complicated Evolution of Superior Vena Cava Syndrome Post Cardiac Surgery

Adrian Fernando Narváez Muñoz<sup>1, \*</sup>, Javier Aristides Rodriguez Herrera<sup>2</sup>,  
Daniela Albina Ibarra Vargas<sup>2</sup>, Carlos Ivan Soledispa Suarez<sup>3</sup>, Maxwell Ruben Velasco Salazar<sup>1</sup>,  
Carlos Alfredo Venegas Arteaga<sup>1</sup>

<sup>1</sup>Department of Cardiovascular Surgery, Hospital de Especialidades Dr. Abel Gilbert Pontón, Guayaquil, Ecuador

<sup>2</sup>Department of Cardiology, Hospital de Especialidades Dr. Abel Gilbert Pontón, Guayaquil, Ecuador

<sup>3</sup>Department of Interventional Cardiology, Hospital de Especialidades Dr. Abel Gilbert Pontón, Guayaquil, Ecuador

## Email address:

adrianfnn@hotmail.com (A. F. N. Muñoz)

\*Corresponding author

## To cite this article:

Adrian Fernando Narváez Muñoz, Javier Aristides Rodriguez Herrera, Daniela Albina Ibarra Vargas, Carlos Ivan Soledispa Suarez, Maxwell Ruben Velasco Salazar, Carlos Alfredo Venegas Arteaga. Complicated Evolution of Superior Vena Cava Syndrome Post Cardiac Surgery. *Journal of Surgery*. Vol. 6, No. 6, 2018, pp. 173-177. doi: 10.11648/j.js.20180606.16

**Received:** December 2, 2018; **Accepted:** December 17, 2018; **Published:** January 22, 2019

---

**Abstract:** Introduction: Superior vena cava syndrome (SVCS) is the clinical manifestation of superior vena cava (SVC) obstruction, with a severe reduction in venous backflow to the right atrium. Symptoms classically include neck, facial and upper limb swelling, development of swollen collateral veins on the front of the chest wall, shortness of breath, coughing, headache, stridor and other neurological complaints, which may all be exacerbated by different postures. CASE REPORT: A 31-year-old man, with a sinus venosus atrial septal defect (SVASD) and partial anomalous pulmonary venous return (PAPVC), was undergone to surgery, in the postoperative course showed a superior vena cava syndrome (SVCS). A second surgery to solve this complication was performed nevertheless, some days after this intervention, the patient developed SVCS symptom's once again. A new strategy with a large stent implantation in the superior vena cava had acceptable results. The patient kept asymptomatic during four months. Discussion: This syndrome is a rare complication after cardiac surgery; it is associated mostly with bicaval cannulation; various causes such as localized hematoma, swollen absorbable hemostat, and narrowing of the SVC by surgical sutures have been reported. There are no exact guidelines for the clinical management of SVCS. The treatments include long-term anticoagulation, thrombolysis, percutaneous transluminal balloon angioplasty, stent implantation, and open surgical reconstruction. CONCLUSION: This article highlights the importance of bear in mind the potential risk of SVCS during cardiac surgery with bicaval cannulation, whereby the proper precautions must be taken into account. Another outstanding fact of this case report shows the value of working with interventional cardiology department as a team to reach successful results in the benefit of the patients.

**Keywords:** Vena Cava Superior, Superior Vena Cava Syndrome, Angiography, Stent, Surgical, Tomography, Sinus Venosus Atrial Septal Defect

---

## 1. Introduction

SVCS is the clinical manifestation of superior vena cava (SVC) obstruction, with a severe reduction in venous backflow to the right atrium [1]. William Hunter in 1757 described the first case of SVCS. In the past benign pathology was the prime cause of this syndrome; currently, this severe disease is caused mainly by tumors which

compress, or develop inside the superior vena cava [1-7]. In recent reports, benign diseases accounted for 10% of SVCS [2].

Iatrogenic causes of SVCS from intravascular devices (catheters, cardiac defibrillators, and pacemaker wires) are becoming recognized increasingly [3-6, 8].

Symptoms classically include neck, facial and upper limb swelling, development of swollen collateral veins on the front of the chest wall, shortness of breath, coughing, headache, stridor and other neurological complaints, which may all be exacerbated by different postures [3, 5, 7, 9, 10]. Onset can be gradual or sudden, and symptoms can be extremely debilitating. The severity of SVC syndrome depends mainly on the rate of progression of SVC obstruction and the degree of development of venous drainage [10].

This paper describes a particular case of a patient with a superior vena cava syndrome after cardiac surgery. This pathology has been described more frequently in malignant instances; however, there are some reports about this complication at the cardiac surgery setting.

## 2. Case Report

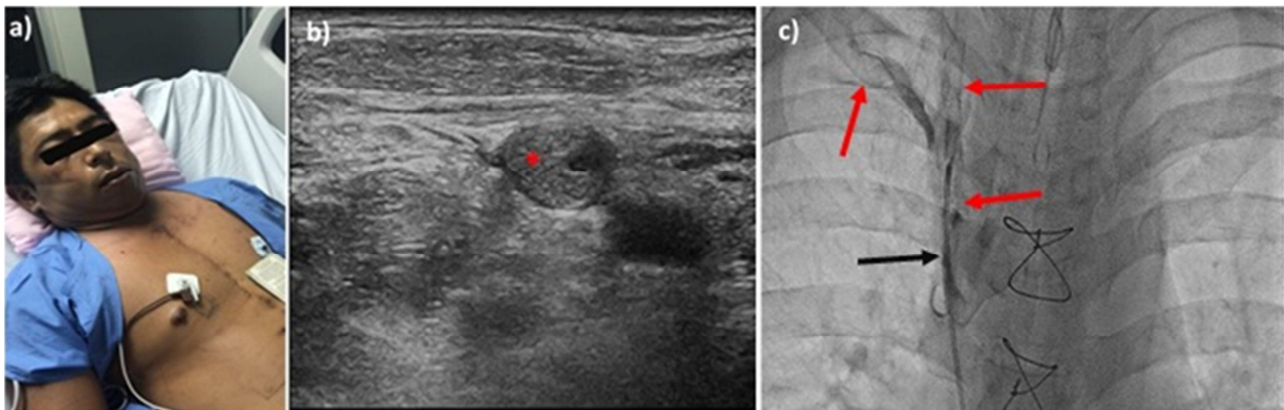
A 31-year-old man, with a sinus venosus atrial septal defect (SVASD) and partial anomalous pulmonary venous return (PAPVC), was undergone to surgical intervention. Cardiopulmonary bypass (CPB) with aortic and bicaval cannulation was established; a wide right atriotomy until superior vena cava (SVC) was performed, the localization of PAPVC was near to the cavo-atrial junction; so the double patch technique (autologous pericardium) was used; baffling

of the pulmonary veins through the sinus venosus defect and additional SVC patch enlargement. The superior vena cava purse string presented a massive bleeding, whereby several surgical stitches were necessary to control this trouble.

The patient presented an uncomplicated postoperative period, being discharged ten days post-surgery, anticoagulated with Warfarin, trying to keep an International normalized ratio (INR) between 2-3.

Five days after medical discharge, the patient presented minimal effort dyspnea, headache on the occipital region, edema and facial cyanosis. At physical examination, the patient had 120 beats per minute, oxygen saturation 67%, cyanosis and edema on the face and upper limbs and jugular venous regurgitation at 45 degrees (Figure 1a); the laboratory test showed a INR value of 2.5. A SVCS was suspected; then, a doppler ultrasound of neck veins displayed a subacute thrombus in the right and left internal jugular vein (IJV); an additional thrombus with similar characteristics was founded in the right subclavian jugular system (Figure 1b)

An angiography showed a bilateral thrombosis of jugular veins, right subclavian vein (SV) and SVC (Figure 1c). Computed tomography angiography (CTA) confirmed the thrombosis in the superior venous system; included SVC, the medial portion of the right subclavian vein and right IJV (Figure 2a).

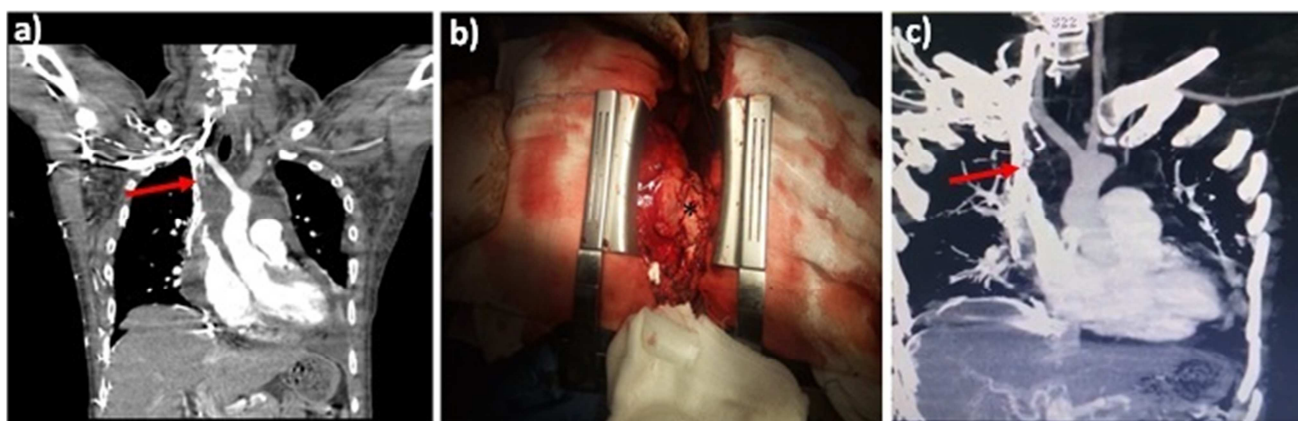


**Figure 1.** Superior vena cava syndrome, physical and image findings: a) Facial and neck swelling with central cyanosis. b) Ultrasound shows thrombus in right internal jugular vein (red asterisk). c) Angiography: the catheter is localized at the superior vena cava (black arrow), we can see a lack of contrast filling of superior vena cava, right subclavian vein and right jugular vein (red arrows).

A surgical approach was performed; the implantation of a stent in superior vena cava was discarded due to the high risk of pulmonary embolism. At the surgical field, the SVC was extensively fibrotic; a right atriotomy until SVC and thrombectomy with a 3-mm Fogarty catheter were carried out. A moderate amount of clots was obtained with a considerable improvement of venous return in the SVC, the cavotomy was prolonged, and a patch angioplasty was performed with a bovine pericardium patch (Figure 2b).

The patient's immediate postoperative course was uneventful being discharged after five days without edema or cyanosis. The patient received Warfarin according to INR (2-3) and antiplatelet therapy with Aspirin 100 mg.

A new CTA was performed one-week post-surgery, evidencing an improvement of SVC anatomy and blood flow, with just a small stenotic area (Figure 2c). Conservative management was decided due the absence of symptoms.



**Figure 2.** Pre, intra and postoperative images: a) Preoperative CTA Stenotic SVC and thrombotic area (red arrow). b) Repair of SVC with patch angioplasty technique (black asterisk). c) Postoperative CTA shows a good result of surgery, there is only a small stenotic area (red arrow).

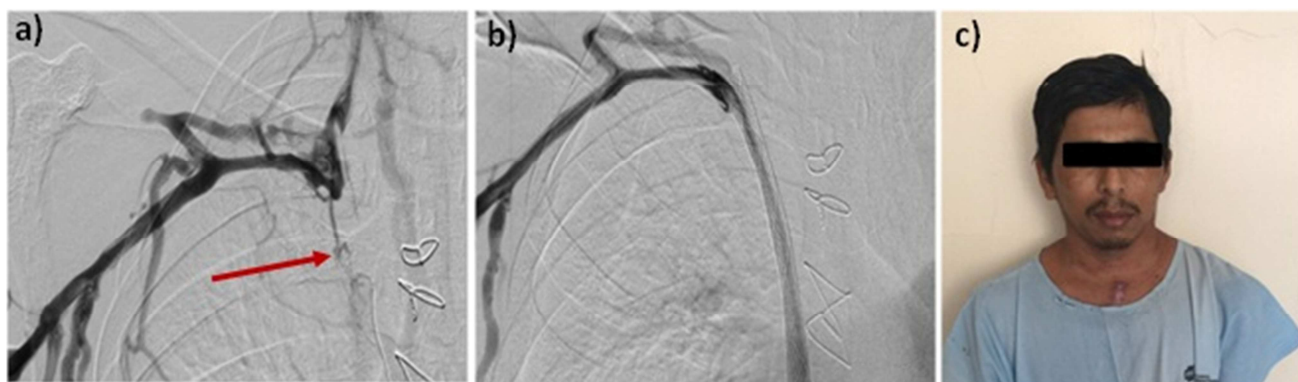
CTA: Computed Tomography Angiography  
SVC: superior vena cava

Some weeks after the surgery, the patient showed a mild headache, which was becoming worse with the time. A new angiography showed a complete absence of SVC; a giant dilated azygos vein and the presence of multiple collateral circulation (Figure 3a). After a harsh effort to cross out the occluded superior vena cava with a rigid guide wire, an angioplasty was performed with balloons of different gauge. The final result was a reestablishment of circulation throughout the SVC. The patient was discharged at home with double antiplatelet therapy (Aspirin and Clopidogrel).

Two weeks after the primary angioplasty a new

angiography was performed; surprisingly the SVC had a complete occlusion again, then a new angioplasty with placement of a large stent (Wallgraft 12x70mm) was achieved successfully (Figure 3b).

The postoperative evolution was complicated with a retroperitoneal hematoma due to inferior vena cava injury during the interventional procedure; the patient was undergone at two surgical procedures. At the second week, the patient was discharged; the patient kept asymptomatic for 4 months since the last surgery (Figure 3c).



**Figure 3.** Angiography findings and interventional treatment: a) Angiography shows a complete absence of SVC (red arrow). b) Post large stent implantation, the blood flow was restored in the SVC. c) Physical appearance of patient post resolution of SVCS.

SVC: superior vena cava  
SVCS: superior vena cava syndrome

### 3. Discussion

In 90% of cases, the SVC syndrome is caused by extrinsic compression from an intrathoracic cancer (malignant cause). Benign causes (10%) can result in extrinsic vascular compression secondary to mediastinitis, benign tumor, or intrinsic obstruction from thrombosis caused by long-term indwelling catheters in patients receiving hemodialysis or wires in patients with endocardial pacemakers [4].

SVCS is classified in four groups, depending on whether venous return azygos is compromised or not. When the return azygos is functional: the type 1 includes obstructions <90%; type 2 includes obstructions > 90%. When the azygos return is no functional, type 3 includes obstructions > 90%, the type 4 includes complete obstructions affecting one of two innominate venous trunks and the azygos system [5].

This syndrome is a rare complication after cardiac surgery; it is associated mostly with bicaval cannulation; various causes such as localized hematoma, swollen absorbable

hemostat, and narrowing of the SVC by surgical sutures have been reported [10].

The potential cause of SVCS in our patient could be the result of multiple hemostatic stitches on SVC, which provoked a partial obstruction and thrombosis of this structure. Another probable reason for this syndrome could be a narrowing at the cavoatrial junction beside the double patch technique, provoking the obstruction of blood flow into the right atrium.

There are no exact guidelines for the clinical management of SVCS. The treatments include long-term anticoagulation, thrombolysis, percutaneous transluminal balloon angioplasty, stent implantation, and open surgical reconstruction. The angioplasty and stenting is the first line in the treatment of SVCS with a benign etiology because it is less invasive and is associated with lower morbidity by thrombosis [1, 5, 8, 9, 12], if this treatment fails, surgical intervention (if the prognosis is auspicious) is the next step to fix the problem out [2, 4, 6, 9, 12]. These interventions are similarly effective for the short-term and mid-term, whereas surgical repair is most useful for obtaining a long-term effect [1, 10].

Sfyroeras et al, performed an extensive review of both treatments, finding that the effectiveness, the relief of symptoms and mid-term patency was comparable between them; however, the rate of secondary interventions was significant in both cases [13].

Complications of stent placement have been reported in 3–7% of patients with SVCS, including occlusion, infection, pulmonary embolus, stent migration, haematoma at the insertion site, bleeding and, very rarely, perforation. Late complications include bleeding (1–14%) and death (1–2%) due to anticoagulation [11].

There are some surgical techniques developed to improve the venous return to the right atrium [1, 2, 4-6, 9-11]. For instance, thrombectomy or vegectomy with primary closure of superior vena cava in patients with SVC syndrome due to pacemaker leads thrombosis or infection, has shown good results [5]; an angioplasty patch in some focalized stenotic area in the SVC has had favorable results in some publications [6, 9]. When the stenotic area is more extensive, the bypass of jugular veins to the right atrium is preferable, it can be reached either autologous grafts (spiral saphenous vein graft, femoropopliteal vein, and pericardial patch) or polytetrafluoroethylene (PTFE) or polyester (Dacron®) grafts [4, 10-12].

Some case series indicate an operative mortality of 5% and patency rates of 80–90%. It is recommended that monitoring of graft patency be done semiannually or sooner if symptoms should arise. Short-term anticoagulation is often recommended after stent placement, but it is uncertain whether long-term anticoagulation necessary. There are also no data upon which to form an evidence-based recommendation for anticoagulation after surgical bypass grafting [6].

The potential thrombosis of the stent in our case is latent, being imperative to keep proper anticoagulation or double antiplatelet therapy for a long-term and annually CTA

controls. If a subsequent thrombosis of the stent would occur, an atrium-jugular bypass might be done, which has been performed in some reports [10-12].

## 4. Conclusion

There is small experience in the management of SVCS as a complication of a cardiac surgery due to its very low incidence. The primary target of the treatment is relief the symptoms and restores the blood flow to the right atrium. The first line of treatment usually is the stent implantation; however, sometimes the surgical approach can be performed as the first option because surgical reconstruction of SVC has better results than stent angioplasty in the long term and the risk of thromboembolism post angioplasty. In our case report, unfortunately, the surgical treatment had not the desired results, whereby a stent angioplasty was realized with the proper restoration of blood flow to the right atrium.

This article highlights the importance of bear in mind the potential risk of SVCS during cardiac surgery with bicaval cannulation, whereby the proper precautions must be taken into account. Another outstanding fact of this case report shows the value of working with interventional cardiology department as a team to reach successful results in the benefit of the patients.

## References

- [1] Li H, Jiang X, Sun T. Open surgery repair for superior vena cava syndrome after failed endovascular stenting. *Annals of Thoracic Surgery*. 2014; 97 (4):1445-7.
- [2] Dedeilias P, Nenekidis I, Hountis P, Prokakis C, Dolou P, Apostolakis E, Koletsis EN. Superior vena cava syndrome in a patient with previous cardiac surgery: what else should we suspect? *Diagnostic Pathology*. 2010; 5:43.
- [3] Diamantini G, Levi Sandri GB, Procaccianti F. Unexpected cause of superior vena cava syndrome. *Gland Surgery*. 2015; 4 (4):359-60.
- [4] Gallo M, Protos AN, Trivedi JR, Slaughter MS. Surgical Treatment of Benign Superior Vena Cava Syndrome. *Annals of Thoracic Surgery*. 2016; 102 (4):e369-71.
- [5] Kokotsakis J, Chaudhry UA, Tassopoulos D, Harling L, Ashrafi H, Vernandos M, et al. Surgical management of superior vena cava syndrome following pacemaker lead infection: a case report and review of the literature. *Journal of Cardiothoracic Surgery*. 2014; 9:107.
- [6] Fichelle JM, Baissas V, Salvi S, Fabiani JN. Superior vena cava thrombosis or stricture secondary to implanted central venous access: Six cases of endovascular and direct surgical treatment in cancer patients. *Journal de Médecine Vasculaire* 2018; 43 (1):20-28.
- [7] Heppel D, Grapow M, Reuthebuch O, Bolliger D, Fassl J. Superior Vena Cava Syndrome Following Mitral Valve Repair. *Journal of Cardiothoracic and Vascular Anesthesiology*. 2018; 32 (2):938-94128.

- [8] Salavitar A, Flyer JN, Torres AJ, Richmond ME, Crystal MA, Turner ME, et al. Transcatheter stenting of superior vena cava obstruction after pediatric heart transplantation: A single-center experience assessing risk factors and outcomes. *Pediatric Transplantation*. 2018; 11:e13267.
- [9] Kühn JP, Mensel B, Ewert R, Bollmann T. Interventional treatment of the acute and subacute vena cava superior syndrome. *Pneumologie*. 2013; 67 (10):573-9.
- [10] Picquet J1, Blin V, Dussaussoy C, Jousset Y, Papon X, Enon B. Surgical reconstruction of the superior vena cava system: indications and results. *Surgery*. 2009; 145 (1):93-9.
- [11] De Raet JM, Vos JA, Morshuis WJ, van Boven WJ. Surgical management of superior vena cava syndrome after failed endovascular stenting. *Interactive Cardiovascular and Thoracic Surgery*. 2012; 15 (5):915-7.
- [12] Zubair MM, Duran CA, Peden EK. Superior Vena Cava Reconstruction Using Femoropopliteal Vein as a Panel Graft. *Annals of Vascular Surgery*. 2017; 44:414. e15-414. e18.
- [13] Sfyroeras GS, Antonopoulos CN, Mantas G, Moulakakis KG, Kakisis JD, Brountzos EA, et al. Review of Open and Endovascular Treatment of Superior Vena Cava Syndrome of Benign Aetiology. *European Journal of Vascular and Endovascular Surgery*. 2017; 53 (2):238-254.