Science Journal of Clinical Medicine
2026, Vol. 15, No. 4, pp. 58–67
https://doi.org/10.11648/j.sjcm.20261504.11

Review Article

Topical Honey for Wound Healing in Women Treated for Breast Cancer, with a Focus on the Surgical Wound After Mastectomy with Axillary Dissection: A Systematic Review

Ouattara Adama[1, 2, *], Djoua Yowel Marilyne Laura Cathérine[1], Ouedraogo Charlemagne[1, 2]

[1]Training and Research Unit in Health Sciences (UFR/SDS), Joseph KI-ZERBO University, Ouagadougou, Burkina Faso

[2]Department of Gynaecology-Obstetrics and Reproductive Medicine, Bogodogo University Teaching Hospital, Ouagadougou, Burkina Faso

Abstract

Mastectomy with axillary lymph node dissection is the reference operation for locally advanced breast cancer in many low-resource settings, and its wound is frequently complicated. This systematic review aimed to synthesize the published evidence on the wound-healing and anti-infective effects of topical honey in women treated for breast cancer, with particular attention to the surgical wound after mastectomy with axillary dissection. Following the PRISMA 2020 statement, PubMed/MEDLINE, Google Scholar and Semantic Scholar were searched for clinical studies published in English or French between 1 January 2000 and 31 December 2025. Two reviewers independently screened records and full texts; risk of bias was assessed with the Cochrane RoB 2 tool for randomized trials, the Joanna Briggs Institute checklist for case series and the CASP checklist for systematic reviews, and levels of evidence were graded according to the French National Authority for Health. Because of marked heterogeneity, the results were synthesized narratively by wound type. Of 874 records identified, 611 were screened after removal of duplicates, 100 full texts were assessed and 10 reports were included. They corresponded to nine distinct studies with 368 patients in primary studies: six reports of five randomized trials, three case series and one systematic review, published between 2005 and 2021 mainly in high-income countries, with one study from North Africa and none from sub-Saharan Africa. Four studies concerned radiation dermatitis, three malignant fungating wounds, two chronic wounds in breast care and one oncology in general. No study evaluated honey on the surgical wound after mastectomy with axillary dissection, the closest evidence being a single breast surgical dehiscence healed in 35 days. The best-established benefits of honey were symptomatic, namely control of malodour and exudate and improved comfort, whereas in radiation dermatitis results were favourable but mostly non-significant, except when honey was added to pentoxifylline (complete healing at 12 weeks: 74% vs 54% vs 36%). Overall risk of bias was low in two reports, moderate in five and high in three. Honey therefore appears to be a safe, affordable and biologically plausible option for breast cancer-related wounds, but its effect on the post-mastectomy surgical wound has not been evaluated and no study has come from sub-Saharan Africa; well-designed randomized trials with standardized honey and objective, blindly assessed outcomes are required.

*Correspondence: Ouattara Adama (ouattzangaadama@yahoo.fr)

Received: 21 October 2026; **Accepted:** 31 October 2026; **Published:** 23 November 2026

Copyright: © The Author(s), 2026. Published by Science Publishing Group. This is an **Open Access** article, distributed under the terms of the Creative Commons Attribution 4.0 License (http://creativecommons.org/licenses/by/4.0/), which permits unrestricted use, distribution and reproduction in any medium, provided the original work is properly cited.

Keywords

Honey, Breast Cancer, Mastectomy, Axillary Dissection, Wound Healing, Radiation Dermatitis, Malignant Wound, Systematic Review

1. Introduction

Breast cancer is the most frequently diagnosed cancer and the leading cause of cancer death in women worldwide, with about 2.3 million new cases and more than 670,000 deaths in 2022 [1, 2]. In sub-Saharan Africa, it affects younger women than in high-income countries, and most patients present at a locally advanced stage, because of the absence of organized screening, socio-economic barriers and limited treatment capacity [3, 4]. In Burkina Faso, 1,372 new cases and 818 deaths were estimated in 2022, representing 15.3% of cancers in women [1]. More than 60% of patients are diagnosed at stage III or IV, which explains the frequent use of total or modified radical mastectomy with axillary lymph node dissection [5, 6].

Mastectomy with axillary dissection remains the reference procedure for locally advanced tumours, but its wound is frequently complicated by seroma, surgical site infection (SSI), skin flap necrosis, dehiscence and lymphoedema [7, 8]. These complications prolong hospital stay, delay adjuvant chemotherapy and radiotherapy, and impair the quality of life of patients [9]. In African settings, they are favoured by advanced disease, neoadjuvant chemotherapy, anaemia and undernutrition.

Honey, the natural sweet substance produced by *Apis mellifera* bees, has been used empirically as a wound remedy since Antiquity, and modern data provide a solid mechanistic basis for this use [10, 11]. Its high osmolarity has a debriding and antibacterial effect; its acidic pH, the release of hydrogen peroxide by glucose oxidase and, in Manuka honey (*Leptospermum scoparium*), non-peroxide activity due to methylglyoxal make it bactericidal, including against biofilms and methicillin-resistant *Staphylococcus aureus* [12, 13]. Honey also promotes autolytic debridement, granulation and re-epithelialization and modulates inflammation [14, 15].

Previous systematic reviews have shown the efficacy of honey on wounds in general and on burns [11, 16], and a recent meta-analysis found improved healing and less pain after episiotomy and caesarean section [17]. However, no systematic review had specifically analysed its effect on the surgical wound after mastectomy with axillary dissection. This context combines treatment-related immunosuppression, frequent undernutrition and complex bacterial contamination.

The research question of this review was: according to the literature published between 2000 and 2025, what is the effect of topical honey, compared with usual wound care, on healing time and surgical site infection in women with breast cancer treated by mastectomy with axillary dissection? The specific objectives were to identify all studies on topical honey for wounds related to breast cancer treatment, to assess their level of evidence and risk of bias, to compare the effect of honey with that of usual treatments, and to identify research gaps.

2. Methodology

2.1. Protocol and Reporting

This systematic review with narrative thematic synthesis was conducted and reported according to the Preferred Reporting Items for Systematic Reviews and Meta-Analyses (PRISMA) 2020 statement [18] and the standards of the Institute of Medicine for systematic reviews [19]. It covered studies published from 1 January 2000 to 31 December 2025.

2.2. Eligibility Criteria

Eligibility criteria were defined using the PICOS (Population, Intervention, Comparator, Outcomes, Study design) framework (Table 1). The primary target population was adult women operated on for histologically proven breast cancer by mastectomy (total, modified radical) or breast-conserving surgery with axillary dissection. Because a preliminary search found no study restricted to this population, studies of topical honey on other wounds related to breast cancer or its treatment (malignant fungating wounds, radiation dermatitis, chronic or dehiscent wounds after breast surgery) were also included, as the closest available evidence.

Table 1. *Eligibility criteria (PICOS).*

Element	Inclusion criteria	Exclusion criteria
Population	Women with breast cancer; primary target: surgical wound after mastectomy or breast-conserving surgery with axillary dissection; also malignant,	Wounds unrelated to breast cancer (venous ulcers, burns) without a breast

Element	Inclusion criteria	Exclusion criteria
	radiation-induced or chronic wounds related to breast cancer	cancer subgroup
Intervention	Topical honey in any form (raw, purified, medical-grade, honey-impregnated dressings such as Medihoney® or L-Mesitran®), alone or combined with other local care	Oral or systemic use of honey
Comparator	Standard local care (antiseptics, moist dressings, silver, alginate, aqueous cream, placebo), another active treatment, or no comparator	–
Outcomes	At least one of: healing time, complete healing, infectious complications, pain, odour, exudate, quality of life, tolerance	Studies without extractable clinical outcome
Study design	Randomized or non-randomized trials, cohort and case–control studies, case series, systematic reviews	Isolated case reports, narrative reviews, editorials, letters, qualitative studies, preclinical studies
Other	English or French; published 2000–2025; full text available	Full text unavailable

2.3. Information Sources and Search Strategy

Three databases were searched: PubMed/MEDLINE, Google Scholar and Semantic Scholar, supplemented by grey literature (conference abstracts, theses and trial registries). Keywords combined "honey", "manuka honey", "medical grade honey", "breast cancer", "breast neoplasms", "mastectomy", "axillary dissection", "wound healing", "cicatrization", "surgical wound", "radiation dermatitis" and "malignant wound". The PubMed equation was: (honey OR manuka honey) AND (breast cancer OR breast neoplasms OR mastectomy) AND (wound healing OR radiation dermatitis OR surgical wound). Equivalent equations were adapted to Google Scholar and Semantic Scholar. References were managed with Zotero version 9.0.5.

2.4. Study Selection

Records retrieved from the three databases and from grey literature were imported into Zotero, and duplicates were removed. Selection was then performed in two stages by two independent reviewers (Djoua Yowel Marilyne Laura Cathérine and Ouattara Adama): first, titles and abstracts were screened against the eligibility criteria; second, the full texts of potentially relevant reports were assessed, and the reason for each exclusion was recorded. Disagreements were resolved by discussion until consensus. The number of records at each stage is shown in the PRISMA flow diagram (Figure 1). Companion publications of the same study were identified and linked, so that the number of distinct studies and of patients could be reported without double counting.

2.5. Data Extraction

Data were extracted by one reviewer (Djoua Yowel Marilyne Laura Cathérine) into a standardized Excel form, piloted on the first included reports, and checked by a second reviewer (Ouattara Adama). The form recorded: author, year, country and design; participants (age, stage, histological type, prior chemotherapy or radiotherapy, comorbidities, nutritional status); intervention (type and origin of honey, frequency of dressing change, duration); comparator; outcomes (time to complete healing, infection, pain, odour, exudate, quality of life) with their effect measures and p values; and missing data. When data were reported only in abstracts or short reports, this was noted, and no assumption was made about unreported results.

2.6. Risk of Bias and Level of Evidence

Risk of bias was assessed with tools adapted to each design: the Cochrane RoB 2 tool for randomized trials [20], ROBINS-I for non-randomized comparative studies [21], the Joanna Briggs Institute (JBI) checklist for case series [22] and the Critical Appraisal Skills Programme (CASP) checklist for systematic reviews [23]. Each domain was rated as low risk, some concerns or high risk. Levels of evidence were assigned according to the classification of the French National Authority for Health (Haute Autorité de Santé, HAS) [24], and overall methodological quality was graded as high, moderate or low.

2.7. Synthesis

Heterogeneity was assessed qualitatively. It was clinical (types of wounds: surgical, malignant fungating, radiation-induced or chronic; populations; honey preparations, doses and frequency of application; comparators), methodological (randomized trials, case series and a systematic review, with different durations of follow-up and risks of bias) and related to outcomes (healing, symptom scores, dermatitis grading scales and bacteriology measured with different instruments). Be-

cause of this heterogeneity and the small number of comparable studies, no meta-analysis was performed and no pooled estimate or statistical test of heterogeneity was computed. Results were summarized descriptively (numbers and proportions of studies, without statistical tests) and synthesized narratively by wound type (thematic synthesis), taking into account the design, level of evidence and risk of bias of each study.

2.8. Ethical Considerations

As a review of published data, this study did not require ethical approval or patient consent.

3. Results

3.1. Study Selection

The search identified 874 records (PubMed/MEDLINE 119, Google Scholar 505, Semantic Scholar 250). After removal of 263 duplicates, 611 titles and abstracts were screened and 511 records were excluded: preclinical studies (n = 61), mastectomy with or without axillary dissection without honey (n = 350), honey on other wounds (n = 75) and oral use of honey (n = 25). Of the 100 full-text reports assessed, 90 were excluded as not relevant to the review question. Ten reports were included (Figure 1). Two of them were companion publications of the same randomized trial by Lund-Nielsen et al., one reporting clinical outcomes and the other bacteriological outcomes [25, 26]; the ten reports therefore correspond to nine distinct studies.

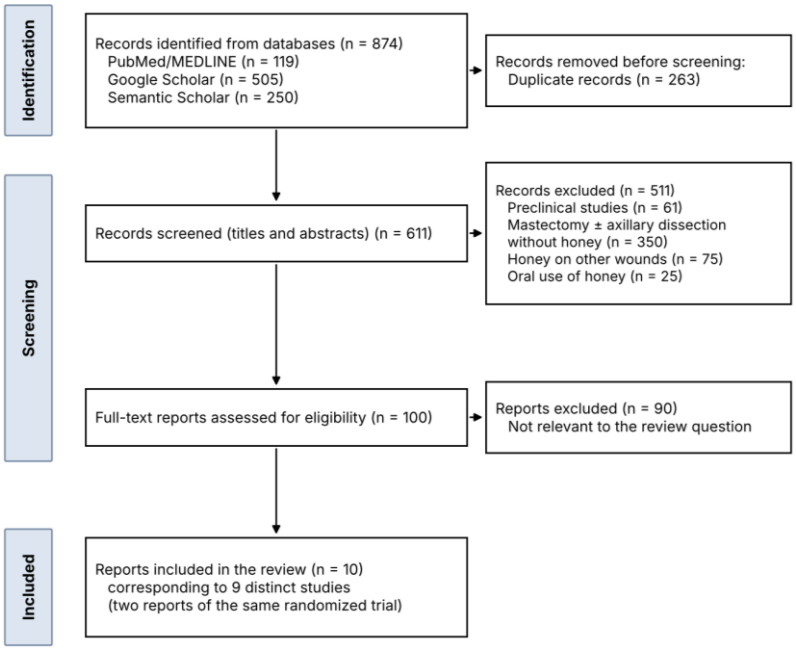

Figure 1. *PRISMA 2020 flow diagram of study selection.*

3.2. Characteristics of the Included Studies

The included reports were published between 2005 and 2021, with a peak of three publications in 2011. They comprised six reports of five randomized controlled trials (60% of reports) [25-30], three case series (30%) [31-33] and one systematic review (10%) [34]. Seven countries were represented: Denmark, the United Kingdom and the United States (two reports each), and the Netherlands, Egypt, the Czech Republic and New Zealand (one each). Europe contributed six reports (60%), North America two (20%), Africa one (Egypt, North Africa; 10%) and Oceania one (10%). No study was conducted in sub-Saharan Africa. The eight primary studies included 368 patients in total, with sample sizes ranging from 2 to 150.

Honey was used alone in nine reports and combined with another active agent (pentoxifylline) in one. Medical-grade honey was used in eight reports, mostly Manuka or *Leptospermum* honey (Medihoney®, L-Mesitran®, Honeysoft®), purified honey in one and an unspecified honey in one. Comparators were silver dressings, paraffin or conventional care, aqueous cream, standard skin care (Hydrophor), pentoxifylline, or no comparator. The main characteristics of the included studies are summarized in Table 2.

Table 2. *Characteristics and main results of the included studies.*

Study (country)	Design; HAS level; n	Population / wound	Honey vs comparator	Main results
Lund-Nielsen 2011, clinical report (Denmark)	RCT; level 2; 69	Malignant wounds, mostly breast	Manuka honey dressings vs silver dressings, 4 weeks	Odour ($p = 0.007$) and exudate ($p < 0.0001$) improved in both arms, no difference between them; wound size reduction 15 vs 8 cm^2 ($p = 0.63$)
Lund-Nielsen 2011, bacteriology report (Denmark)	Same RCT; level 2; 69	Malignant wounds, mostly breast	Manuka honey vs silver dressings	At least one pathogen in almost all wounds; no qualitative difference between arms or over time
Moolenaar 2006 (Netherlands)	RCT; level 2; 21 patients (24 skin reactions)	Radiation dermatitis, breast cancer	Medical honey (Honeysoft®) vs paraffin	Trend towards faster healing of grade ≥ 3 dermatitis; higher patient satisfaction; underpowered
Shoma 2010 (Egypt)	RCT, 3 arms; level 2; 150 (3 × 50)	Radiation burn after breast-conserving surgery	A: standard care; B: + pentoxifylline 400 mg twice daily; C: B + topical purified honey	Complete healing at 12 weeks: C 74% vs B 54% vs A 36% ($p < 0.0001$); marked analgesic effect of honey
Kwok 2015 (USA)	Pilot RCT (abstract); level 2; 34	Adjuvant radiotherapy, including after modified radical mastectomy	Medihoney® twice daily vs standard skin care (Hydrophor)	Trend in favour of Medihoney®; full data unpublished
Naidoo 2011 (New Zealand)	Phase II RCT (abstract); level 2; 81	Prophylaxis of radiation dermatitis	Manuka honey twice daily vs aqueous cream	Grade ≥ 2 dermatitis 37.2% vs 57.8% ($p = 0.08$); trend to shorter duration
Robson 2005 (UK)	Case series; level 4; 2	Chronic wounds in breast care (dehiscence after breast reduction, post-radiotherapy necrosis)	*Leptospermum* honey; no comparator	Healing and symptom control; good tolerance
Holubová 2021 (Czech Republic)	Prospective case series; level 4; 9 (1 breast case)	Non-healing infected wounds, including one breast surgical dehiscence	Medical-grade honey (L-Mesitran®); before–after	Breast dehiscence healed at day 35; pain VAS 2 at day 20; odour and exudate resolved in all cases
Segovia 2010 (USA)	Case report series (congress, news report); level 4; 2	Fungating breast tumour wounds	Medihoney® dressings every 3 days; no comparator	Rapid debridement, elimination of malodour; healing from the third dressing change in one case
Bardy 2008 (UK)	Systematic review; 43 studies	Uses of honey in oncology (wounds, mucositis)	Various	Low overall methodological quality; possible value for fungating and post-excision wounds; insufficient evidence

RCT: randomized controlled trial; VAS: visual analogue scale. HAS: French National Authority for Health.

3.3. Thematic Synthesis

Malignant fungating breast wounds. In the randomized trial of Lund-Nielsen et al. in Denmark (69 patients with malignant wounds, mostly of breast origin), Manuka honey-coated dressings were compared with silver-coated dressings for four weeks [25]. Odour ($p = 0.007$) and exudate ($p < 0.0001$) improved significantly in both arms, without difference between them, and the reduction in wound size was not significant ($p = 0.63$). The bacteriological report of the same trial found at least one pathogen in almost all wounds, without qualitative difference between dressings or over time; the authors concluded that routine bacteriological sampling was not justified

[26]. A congress report described rapid debridement and elimination of malodour with Medihoney® dressings [33]. These results matter for women with fungating tumours, for whom malodour, exudate and bleeding cause distress and social isolation [35, 36].

Radiation dermatitis. The three-arm randomized trial of Shoma et al. in Egypt (150 women after breast-conserving surgery) evaluated pentoxifylline alone and combined with topical purified honey for radiation-induced burns [28]. Complete healing at 12 weeks was highest when honey was added (74% vs 54% with pentoxifylline alone and 36% with standard care), with a marked analgesic effect. In the phase II trial of Naidoo et al., grade ≥ 2 radiation dermatitis occurred in 37.2% of women using Manuka honey and 57.8% of those using aqueous cream, a clinically notable but non-significant difference ($p = 0.08$) [30]. The randomized trial of Moolenaar et al. (21 patients) [27] and the pilot trial of Kwok et al. (34 patients) [29] pointed in the same direction without providing definitive evidence. Several of these trials were available only as abstracts or short reports, which limited their full methodological assessment.

Chronic and surgical wounds in breast care. Robson, Martin and Cooper reported the use of *Leptospermum* honey on chronic and radiation-induced wounds in breast care, with complete healing within a few weeks, pain relief and no adverse effects [31]. In the prospective case series of Holubová et al., one breast surgical wound dehiscence healed in 35 days with medical-grade honey, with resolution of pain, odour and exudate [32]. This isolated observation is the published evidence closest to the post-mastectomy surgical wound.

Evidence related to breast surgery. No included study evaluated honey on the incision after mastectomy with axillary dissection. Three elements approach this question: the trial of Shoma et al., the only randomized trial whose population was explicitly post-surgical (breast-conserving surgery), although the target wound was a radiation burn [28]; the breast surgical dehiscence of Holubová et al. [32]; and the trial of Moolenaar et al. on radiation-induced lesions of the chest wall in breast cancer patients [27]. The systematic review of Bardy et al. concluded that the evidence on honey in oncology was of low quality, while suggesting a possible value for fungating and post-excision wounds [34].

3.4. Level of Evidence and Risk of Bias

According to the HAS classification, the six reports of randomized trials were level 2, the three case series level 4, and the systematic review was classified as a level 1 synthesis that concluded that evidence was insufficient. RoB 2 was used for six reports (60%), the JBI checklist for three (30%) and CASP for one (10%) (Table 3).

Table 3. *Risk of bias of the included reports.*

Study	Tool	Domain ratings	Overall	Main source of bias
Lund-Nielsen 2011, clinical	RoB 2	D1 !, D2 +, D3 +, D4 !, D5 !	Some concerns	Outcome measurement (D4): subjective outcomes, blinding impossible
Lund-Nielsen 2011, bacteriology	RoB 2	D1 !, D2 +, D3 +, D4 !, D5 !	Some concerns	Outcome measurement (D4): unblinded clinical assessment
Moolenaar 2006	RoB 2	D1 !, D2 !, D3 +, D4 !, D5 !	Some concerns	D4: unblinded grading; small sample (n = 21)
Shoma 2010	RoB 2	D1 !, D2 +, D3 +, D4 +, D5 +	Low	Randomization (D1) not described; objective primary outcome (burn area)
Kwok 2015	RoB 2	D1 –, D2 !, D3 !, D4 –, D5 –	High	Randomization and blinding not reported (abstract)
Naidoo 2011	RoB 2	D1 !, D2 !, D3 +, D4 !, D5 !	Some concerns	D4: open-label trial; RTOG grading sensitive to knowledge of treatment
Robson 2005	JBI	Q1 !, Q2 +, Q3 !, Q4 –, Q5 –	High	Selection and follow-up: two cases, no standardized follow-up
Holubová 2021	JBI	Q1 +, Q2 +, Q3 +, Q4 !, Q5 +	Some concerns	Unblinded assessment of healing
Segovia 2010	JBI	Q1 !, Q2 !, Q3 –, Q4 –, Q5 +	High	Incomplete description, no standardized follow-up
Bardy 2008	CASP	C1 +, C2 +, C3 !, C4 +, C5 !	Low	Low quality of the primary studies available

+ low risk; ! some concerns; – high risk. RoB 2 domains: D1 randomization; D2 deviations from intended interventions; D3 missing outcome data; D4 measurement of the outcome; D5 selection of the reported result. JBI items: Q1 clear inclusion criteria; Q2 valid measurement of the condition and intervention; Q3 complete and consecutive inclusion; Q4 complete follow-up; Q5 clear reporting of results.

Overall, two reports were at low risk of bias (20%: Shoma, Bardy), five raised some concerns (50%: both Lund-Nielsen reports, Moolenaar, Naidoo, Holubov â) and three were at high risk (30%: Robson, Kwok, Segovia). The most frequent main source of bias was the measurement of the outcome (D4), present in five reports. It stems from a single, irreducible cause, the impossibility of blinding honey (colour, smell, texture), combined with subjective outcomes such as odour, pain, exudate and dermatitis grade. The trial of Shoma et al. avoided this bias by using an objective primary outcome (burn surface area).

4. Discussion

4.1. Summary of the Evidence

This review, conducted according to PRISMA 2020 and including ten reports published between 2005 and 2021, is to our knowledge the first to synthesize specifically the evidence on the wound-healing effect of honey in breast cancer while addressing the post-mastectomy wound. It reveals a gap between a solid biological rationale and limited clinical evidence [12, 14, 37]. The best-documented benefit of honey is symptomatic: control of malodour, inflammation and exudate in fungating tumour wounds [25, 33], which is often the legitimate goal of care in palliative situations [35]. For objective healing outcomes and the prevention of radiation dermatitis, results are heterogeneous and, when formally tested, mostly non-significant [27, 30]. The positive result of Shoma et al. concerns honey combined with pentoxifylline, and its own contribution cannot be fully separated from that of the drug [28]. Honey should therefore be regarded as a promising, safe but insufficiently evaluated option rather than a proven treatment.

4.2. Complementarity with the Antitumour Data

A companion systematic review conducted in our department examined the antitumour and systemic effects of honey in malignant breast tumours [38]. Mostly preclinical data showed inhibition of cell proliferation, induction of apoptosis and reduced migration and invasion, together with adjuvant benefits on mucositis, fatigue and quality of life during chemotherapy and radiotherapy [38, 39]. The present review complements that work: the antitumour effect concerns honey mostly given orally, whereas this review documents its local wound-healing action. These are two distinct but complementary dimensions of the same natural resource.

4.3. Honey Compared with Conventional Care

Conventional care of the post-mastectomy wound relies on asepsis, drainage and standard dressings (povidone-iodine and other antiseptics, saline, alginate, hydrocolloids), whereas the prevention of seroma and flap necrosis relies on quilting sutures, flap fixation or corticosteroids, with inconsistent efficacy [7, 40]. None of these studies evaluated honey. Honey combines a broad antibacterial and antibiofilm activity, including against methicillin-resistant Staphylococcus aureus (MRSA) [12, 13]; an anti-inflammatory action through inhibition of the release of tumour necrosis factor alpha (TNF-α), interleukin-1 beta (IL-1β) and interleukin-6 (IL-6) and stimulation of fibroblasts [14]; stimulation of angiogenesis and re-epithelialization; and maintenance of a moist environment that favours cell migration and autolytic debridement [10, 15]. These properties target precisely the main mechanisms of post-mastectomy wound complications: infection, often superimposed on seroma, is the main pathway to dehiscence and flap necrosis [7, 8].

This coherence is consistent with observations in other surgical settings. A meta-analysis of randomized trials showed that topical honey improves healing and reduces pain after episiotomy and caesarean section [17], a cohort of 766 women in Mali found faster healing of caesarean wounds with medical-grade honey [41], and the Cochrane review of Jull et al. concluded that honey heals infected postoperative wounds faster than antiseptics and gauze [16]. These data are transferable but indirect: they strengthen the plausibility of a benefit on the breast surgical wound without demonstrating it.

The safety of honey depends on its quality. Manuka honey owes its antiseptic properties to its high methylglyoxal content, and caution has been suggested regarding chronic exposure to very high doses [37]. As early as 1980, a letter in the Lancet warned of the microbiological risk of non-sterilized honey applied to breast ulcers [3]. Honey for clinical use must therefore be standardized, microbiologically controlled, compliant with the Codex Alimentarius and preferably gamma-sterilized; its enzymatic activity is degraded by heat and prolonged storage [10, 41].

4.4. Relevance to the Post-Mastectomy Wound and the African Context

The central result of this review is negative: none of the included studies evaluated honey on the incision after mastectomy with axillary dissection, although this surgery is common in our context because of late diagnosis and carries high wound morbidity [5, 7]. The single breast surgical dehiscence healed with honey only illustrates plausibility [32]. A second gap adds to the first: no study was conducted in sub-Saharan Africa and none used local honey, although this region combines a high frequency of locally advanced breast cancer [3, 4] with immediate availability of honey. This double gap justifies a randomized trial in Burkina Faso comparing a standardized local honey with conventional care, with healing time as the primary outcome and 30-day SSI, seroma, dehiscence, pain and cost as secondary outcomes, assessed by an independent, blinded evaluator.

4.5. Strengths and Limitations

The strengths of this review are its explicit question, its adherence to PRISMA 2020, double independent selection, and the use of design-specific risk-of-bias tools.

It also has limitations. First, the heterogeneity of designs, honey preparations and outcomes precluded meta-analysis and limits the strength of conclusions. Second, the absence of any trial on the post-mastectomy surgical wound is the main gap, and the included evidence is therefore indirect. Third, several trials were available only as abstracts or short reports, with incomplete data. Fourth, sample sizes were small and follow-up often short. Fifth, the search was limited to three databases (without Embase, CINAHL or the Cochrane Library) and to English and French, and Google Scholar searches are not fully reproducible; relevant studies may have been missed. Sixth, the protocol was not registered, and two reports of the same trial and a non-peer-reviewed congress report were counted among the ten included reports. Finally, the certainty of the evidence was graded with the HAS classification rather than with the GRADE approach, publication bias could not be assessed formally because of the small number of studies, and some of the included evidence (case series and reports of only two patients) carries a high risk of selection bias.

4.6. Implications and Research Agenda

In the current state of knowledge, honey cannot be formally recommended as the reference treatment for breast oncological wounds. It nevertheless has real logistical and economic advantages: it is locally produced, abundant, cheap, easy to obtain, culturally accepted and safe. Its integration into practice requires standardization and clinical validation. Priorities are: (i) randomized trials with standardized honey and objective outcomes assessed blindly by a third party (microbiologically defined SSI at 30 days, seroma volume, wound area measured by planimetry on photographs); (ii) harmonized designs and outcomes to allow future meta-analyses; (iii) galenic development and stability testing of quality-controlled local medical-grade honey; and (iv) pharmacovigilance in African settings.

5. Conclusion

This systematic review of ten reports shows that honey has a coherent therapeutic profile and excellent tolerance in breast cancer-related wounds. Its best-established benefit is symptomatic, with control of malodour, inflammation and exudate in fungating tumour wounds; in radiation dermatitis, results are encouraging but mostly non-significant. No study evaluated honey on the surgical wound after mastectomy with axillary dissection, and none came from sub-Saharan Africa. The current evidence, dominated by low-level studies, does not support grade A recommendations. Given the low cost, availability, acceptability and safety of honey, its rigorous evaluation with standardized preparations and relevant comparators in sub-Saharan Africa is an original, relevant and feasible research priority.

Abbreviations

CASP	Critical Appraisal Skills Programme
HAS	Haute Autorite de Sante (French National Authority for Health)
IL-1β	Interleukin-1 Beta
IL-6	Interleukin-6
JBI	Joanna Briggs Institute
MRSA	Methicillin-Resistant Staphylococcus Aureus
PICOS	Population, Intervention, Comparator, Outcomes, Study design
PRISMA	Preferred Reporting Items for Systematic Reviews and Meta-Analyses
RCT	Randomized Controlled Trial
RoB 2	Cochrane Risk of Bias 2 tool
ROBINS-I	Risk Of Bias In Non-randomised Studies of Interventions
RTOG	Radiation Therapy Oncology Group
SSI	Surgical Site Infection
TNF-α	Tumour Necrosis Factor Alpha
VAS	Visual Analogue Scale

Author Contributions

Ouattara Adama: Conceptualization, Investigation, Methodology, Supervision, Validation, Writing – review & editing

Djoua Yowel Marilyne Laura Cathérine: Data curation, Formal Analysis, Investigation, Methodology, Visualization, Writing – original draft

Ouedraogo Charlemagne: Formal Analysis, Validation, Writing – review & editing

Conflicts of Interest

The authors declare no conflicts of interest.

References

[1] Bray F, Laversanne M, Sung H, Ferlay J, Siegel RL, Soerjomataram I, et al. Global cancer statistics 2022: GLOBOCAN estimates of incidence and mortality worldwide for 36 cancers in 185 countries. CA Cancer J Clin. 2024; 74(3): 229-63.

[2] World Health Organization. Breast cancer [Internet]. Geneva: WHO; 2024. Available: https://www.who.int/news-room/fact-sheets/detail/breast-cancer

[3] Jedy-Agba E, McCormack V, Adebamowo C, dos-Santos-Silva I. Stage at diagnosis of breast cancer in sub-Saharan Africa: a systematic review and meta-analysis. Lancet Glob Health. 2016; 4(12): e 923-35.

[4] Ly M, Antoine M, Andr é F, Callard P, Bernaudin JF, Diallo DA. Breast cancer in sub-Saharan African women: current state of knowledge. Bull Cancer. 2011; 98(7): 797-806.

[5] Zongo N, Millogo-Traor éTFD, Bagr éSC, Bagu éAH, Ouangr é E, Zida M, et al. The role of surgery in the management of breast cancer in women at the Yalgado Ou édraogo University Hospital Center: a study of 81 cases. Pan Afr Med J. 2015; 22: 117.

[6] Crestani A, et al. Prevention of lymphocele or seroma after mastectomy and axillary lymphadenectomy for breast cancer: systematic review and meta-analysis. Sci Rep. 2022; 12(1): 10016.

[7] Kuroi K, Shimozuma K, Taguchi T, Imai H, Yamashiro H, Ohsumi S, et al. Evidence-based risk factors for seroma formation in breast surgery. Jpn J Clin Oncol. 2006; 36(4): 197-206.

[8] Cardoso F, Kyriakides S, Ohno S, Penault-Llorca F, Poortmans P, Rubio IT, et al. Early breast cancer: ESMO Clinical Practice Guidelines for diagnosis, treatment and follow-up. Ann Oncol. 2019; 30(8): 1194-220.

[9] Molan P, Rhodes T. Honey: a biologic wound dressing. Wounds. 2015; 27(6): 141-51.

[10] Vandamme L, Heyneman A, Hoeksema H, Verbelen J, Monstrey S. Honey in modern wound care: a systematic review. Burns. 2013; 39(8): 1514-25.

[11] Cooper RA, Molan PC, Harding KG. The sensitivity to honey of Gram-positive cocci of clinical significance isolated from wounds. J Appl Microbiol. 2002; 93(5): 857-63.

[12] Jenkins R, Burton N, Cooper R. Manuka honey inhibits cell division in methicillin-resistant Staphylococcus aureus. J Antimicrob Chemother. 2011; 66(11): 2536-42.

[13] Majtan J. Honey: an immunomodulator in wound healing. Wound Repair Regen. 2014; 22(2): 187-92.

[14] Tashkandi H. Honey in wound healing: an updated review. Open Life Sci. 2021; 16(1): 1091-100.

[15] Jull AB, Cullum N, Dumville JC, Westby MJ, Deshpande S, Walker N. Honey as a topical treatment for wounds. Cochrane Database Syst Rev. 2015;(3): CD005083.

[16] Ferraz Barbosa B, de Moraes FCA, Araujo Alves da Silva B, Bordignon Barbosa C, Pereira da Silva I, da Silva ER, et al. The use of honey for cicatrization and pain control of obstetric wounds: a systematic review and meta-analysis of randomized controlled trials. Nutrients. 2024; 16(2): 185.

[17] Page MJ, McKenzie JE, Bossuyt PM, Boutron I, Hoffmann TC, Mulrow CD, et al. The PRISMA 2020 statement: an updated guideline for reporting systematic reviews. BMJ. 2021; 372: n71.

[18] Institute of Medicine (US) Committee on Standards for Systematic Reviews of Comparative Effectiveness Research. Finding what works in health care: standards for systematic reviews. Washington (DC): National Academies Press (US); 2011.

[19] Sterne JAC, Savović J, Page MJ, Elbers RG, Blencowe NS, Boutron I, et al. RoB 2: a revised tool for assessing risk of bias in randomised trials. BMJ. 2019; 366: l4898.

[20] Sterne JA, Hern án MA, Reeves BC, Savović J, Berkman ND, Viswanathan M, et al. ROBINS-I: a tool for assessing risk of bias in non-randomised studies of interventions. BMJ. 2016; 355: i4919.

[21] Munn Z, Barker TH, Moola S, Tufanaru C, Stern C, McArthur A, et al. Methodological quality of case series studies: an introduction to the JBI critical appraisal tool. JBI Evid Synth. 2020; 18(10): 2127-33.

[22] Critical Appraisal Skills Programme. CASP Systematic Review Checklist [Internet]. Oxford: CASP; 2018. Available: https://casp-uk.net/casp-tools-checklists/

[23] French National Authority for Health (Haute Autorit éde Sant é). Levels of evidence and grading of clinical practice guidelines: an overview. Saint-Denis La Plaine: HAS; 2013.

[24] Lund-Nielsen B, Adamsen L, Gottrup F, Rørth M, Tolver A, Kolmos HJ. Qualitative bacteriology in malignant wounds — a prospective, randomized, clinical study to compare the effect of honey and silver dressings. Ostomy Wound Manage. 2011; 57(7): 28-36.

[25] Moolenaar M, Poorter RL, van der Toorn PP, Lenderink AW, Poortmans P, Egberts AC. The effect of honey compared to conventional treatment on healing of radiotherapy-induced skin toxicity in breast cancer patients. Acta Oncol. 2006; 45(5): 623-4.

[26] Shoma A, Eldars W, Noman N, Saad M, Elzahaf E, AbdAlla M, et al. Pentoxifylline and local honey for radiation-induced burn following breast conservative surgery. Curr Clin Pharmacol. 2010; 5(4): 251-6.

[27] Kwok R, O'Brien S, Lunz L, Morgan M, Frassica DA, Cheston S, et al. Prospective randomized pilot study of standard skin care versus Medihoney in the prophylactic and acute management of radiation dermatitis in patients receiving adjuvant radiation therapy for breast cancer [abstract]. Int J Radiat Oncol Biol Phys. 2015; 93(3 Suppl): E468-9.

[28] Naidoo N, Molan P, Littler R, Mok G, Jameson M, Round G, et al. A phase II randomized controlled trial of Manuka honey as prophylaxis against radiation-induced dermatitis in breast cancer patients [abstract]. Eur J Cancer. 2011; 47(Suppl 1).

[29] Robson V, Martin L, Cooper R. The use of Leptospermum honey on chronic wounds in breast care. Honey: A Modern Wound Management Product. Aberdeen: Wounds UK Publishing; 2005:103-111.

[30] Holubová A, Chlupáčová L, Cetlová L, Cremers NAJ, Pokorná A. Medical-grade honey as an alternative treatment for antibiotics in non-healing wounds — a prospective case series. Antibiotics (Basel). 2021; 10(8): 918.

[31] Segovia D. Honey beneficial for treatment of fungating tumor wounds [Internet]. News-Medical; 2010 Apr 17. Available: https://www.news-medical.net/news/20100417/Honey-beneficial-for-treatment-of-fungating-tumor-wounds.aspx

[32] Bardy J, Slevin NJ, Mais KL, Molassiotis A. A systematic review of honey uses and its potential value within oncology care. J Clin Nurs. 2008; 17(19): 2604-23.

[33] Alexander S. Malignant fungating wounds: managing pain, bleeding and psychosocial issues. J Wound Care. 2009; 18(10): 418-25.

[34] Lund-Nielsen B, Müller K, Adamsen L. Malignant wounds in women with breast cancer: feminine and sexual perspectives. J Clin Nurs. 2005; 14(1): 56-64.

[35] Alhabsi AN, Al Lawati A, Al Hashmi L, Al-Isaii F, Alghammari A, Das S, et al. Clinical and postoperative applications of Manuka honey in wound healing: an evidence-based review. Int Wound J. 2026; 23: e70939.

[36] Ouédraogo I. Honey in the management of malignant breast tumours: a systematic review of the literature from 2001 to 2025. [Master's thesis No. 344]. Ouagadougou: Joseph KI-ZERBO University; 2026.

[37] Erejuwa OO, Sulaiman SA, Wahab MSA. Effects of honey and its mechanisms of action on the development and progression of cancer. Molecules. 2014; 19(2): 2497-522.

[38] Xiong X, Ou X, Wang L, Zheng X. Efficacy and safety of methylprednisolone in the prevention of seroma formation after mastectomy: systematic review and meta-analysis. Medicine (Baltimore). 2025; 104: e45353.

[39] Bocoum A, van Riel SJJM, Traoré SO, Ngo Oum II EF, Traoré Y, Thera AT, et al. Medical-grade honey enhances the healing of caesarean section wounds and is similarly effective to antibiotics combined with povidone-iodine in the prevention of infections — a prospective cohort study. Antibiotics (Basel). 2023; 12(1): 92.

[40] Mossel DA. Honey for necrotic breast ulcers. Lancet. 1980; 2(8203): 1091.

[41] Codex Alimentarius Commission (FAO/WHO). Standard for honey (CXS 12-1981, revised 2001). Rome: FAO/WHO; 2001.