

# Evaluation of Corneal Endothelial Changes in Eyes with Silicone Oil Tamponade After Pars Plana Vitrectomy with or Without Phacoemulsification

Mohamed A. M. R. Afify<sup>1</sup>, Ahmed H. Assaf<sup>2</sup>, Raafat Ali Rehan<sup>2</sup>, Hazem Abdallah Elnashar<sup>1</sup>, Marwa A. Karim<sup>2</sup>

<sup>1</sup>Memorial Institute for Ophthalmic Research (MIOR), Cairo, Egypt

<sup>2</sup>Ophthalmology Department, Faculty of Medicine, Ain Shams University, Cairo, Egypt

## Email address:

Mohamed.afify@med.asu.edu.eg (M. A. M. R. Afify), Assaf.ahmed@gmail.com (A. H. Assaf), Raafatrehan001@gmail.com (R. A. Rehan), Dr.hazemelnashar@gmail.com (H. A. Elnashar), marwa\_abdelkarim@med.asu.edu.eg (M. A. Karim), Dr\_mory2006@yahoo.com (M. A. Karim)

## To cite this article:

Mohamed A. M. R. Afify, Ahmed H. Assaf, Raafat Ali Rehan, Hazem Abdallah Elnashar, Marwa A. Karim. Evaluation of Corneal Endothelial Changes in Eyes with Silicone Oil Tamponade After Pars Plana Vitrectomy with or Without Phacoemulsification. *International Journal of Ophthalmology & Visual Science*. Vol. 7, No. 2, 2022, pp. 51-56. doi: 10.11648/j.ijovs.20220702.12

Received: April 7, 2022; Accepted: May 2, 2022; Published: May 7, 2022

**Abstract:** *Aim:* To assess corneal endothelium changes by non-contact specular microscopy in eyes underwent pars plana vitrectomy (PPV) with temporary silicone oil (SO) tamponade with or without phacoemulsification. *Methods:* We concluded 24 patients, divided to two groups: 12 patients had pars plana vitrectomy with SO injection (group 1) and 12 patients had combined phaco-vitrectomy with SO injection (group 2). All of them underwent full ophthalmological examination: best corrected visual acuity (BCVA), measurement of IOP, fundus examination and specular microscopy follow ups at the 1<sup>st</sup> week, 1<sup>st</sup> month and 3<sup>rd</sup> month visits. *Results:* The count of Endothelial cell density (ECD) in group 1 dropped from  $2543.58 \pm 759.62$  cell/mm<sup>2</sup>, to  $2299.33 \pm 729.87$  cell/mm<sup>2</sup>, while in group 2 was  $2621.08 \pm 514.50$ , dropped to  $2307.50 \pm 575.55$  respectively, and the mean cell density (MCD) decreased significantly in group 1 and group 2, at 3<sup>rd</sup> month than at 1<sup>st</sup> week. Three months after operation, CV (polymegathism) was  $34.58 \pm 4.29\%$  and  $35.75 \pm 4.16\%$ , hexagonality (pleomorphism) was  $46.83 \pm 8.67\%$  and  $47.83 \pm 10.50\%$ , while mean CCT was  $553.08 \pm 22.13$   $\mu$ m and  $548.17 \pm 33.12$  for group 1 and 2 respectively, and without corneal edema reported at the study end. *Conclusion:* pleomorphism (decreased HEX), polymegathism (increased CV) and endothelial cell (EC) loss were documented in all patients underwent pars plana vitrectomy (PPV) with silicone oil (SO) injection with a higher probability of polymegathism (CV increase) noted after adding phacoemulsification to the procedure. These findings strongly suggest early SO removal after reaching aimed tamponading action to avoid SO keratopathy.

**Keywords:** Keratopathy, Silicon Tamponade, Phacovitrectomy, Corneal Endothelial Cells

## 1. Introduction

ECD provides an insight on corneal endothelial viability. A natural number reduction of ECD is a physiological aging phenomenon. ECD counts of less than 800/mm<sup>2</sup> can cause corneal edema. Multiple risk factors attributed to accelerate the loss, e.g.: silicone oil keratopathy, intraocular surgery, diabetes mellitus, glaucoma and trauma [1].

Corneal endothelial cell lack ability to regenerate so any damage results in reduction in ECD [2].

Specular microscopy provides a noninvasive imaging technique for proper visualization and analysis of corneal endothelium, in an accurate way [3].

Silicone oils are major milestone in vitreoretinal surgery with different indications of vitrectomy [4]. They are basically needed as an intraocular tamponade for their capability to keep attachment between neurosensory retina and retinal pigment epithelium (RPE) [5]. Yet, it attributes to various side effects like glaucoma, progressive vascularization, corneal decompensation due to

endotheliopathy and glaucoma which are vision threatening [6]. Silicone oil keratopathy may proceed for corneal decompensation where keratoplasty is mandatory [7].

## 2. Aim of the Work

To assess changes in endothelial cells by non-contact specular microscopy in eyes that had pars plana vitrectomy (PPV) with temporary tamponade by silicone oil (SO), with or without phacoemulsification.

## 3. Patients and Methods

We included 24 patients in our prospective study at Memorial Institute for Ophthalmic Researches (MIOR) in the period from March 2021 to February 2022. We included patients undergoing pars plana vitrectomy with silicone oil tamponade with or without phacoemulsification, for a rhegmatogenous RD, tractional RD or a recurrent RRD and aged from 30 to 60 years. We excluded: Air or Gas tamponade, trauma, uveitis, corneal opacification, ocular surface diseases (e.g., moderate to severe dry eye), detachment under silicone oil tamponade within study duration, glaucoma patients and patients with anterior chamber silicone oil droplet. Included patients assigned to one of two groups: group 1 underwent pars plana vitrectomy and silicone oil injection and group 2 underwent combined phaco-vitrectomy & SO injection. The baseline endothelial cell count for both groups was taken after one week from operation to avoid the operation as a confounding factor. Postoperative follow-up complete examinations were performed at first month, third month postoperative and compared to baseline count. Complete ophthalmological examination was done for all patients: BCVA (Log MAR), slit lamp biomicroscopy, fundus examination, intraocular pressure (IOP) and non-contact specular microscopy (SP-1P; Topcon, Tokyo, Japan): mean endothelial cell density (MCD), central corneal thickness (CCT), coefficient of variation in cell size (CV%) and percentage of hexagonal cells (HEX%) values were measured and recorded.

This study followed the tenets of the Declaration of Helsinki on Ethical Principles for Medical Research Involving Humans. An ethical committee approval was obtained from AIN\_SHAMS UNIVERSITY medical ethical committee, ref approval. No. MS85/2021. Written informed consents were obtained from all patients.

Statistical Analysis: (IBM SPSS) version 23.

## 4. Results

Twenty-four patients were included in our study. They were 11 females (45.8%) and 13 males (54.2%) with age ranged from 31 – 60 years. 45.8% of them patients were diabetics. 54.2% were smokers. all patients have clear cornea preoperative in both groups.

### 4.1. Best Corrected Visual Acuity (BCVA) by logMAR

No statistically significant difference was noted between the two groups regarding BCVA preoperative, at the 1st week, 1<sup>st</sup> and 3rd month follow ups, with p-value = 0.722, 0.444, 0.112 and 0.064 respectively (Table 1). BCVA improved significantly in both groups at the 3rd month FU relative to preoperative. Also, the amount of change of BCVA increased significantly in group 1 than in group 2 at the 3rd month follow ups, with p-value = 0.005. Yet, no statistically significant difference, regarding the amount of change (mean difference) at the 1st week and 1st month follow ups.

### 4.2. IOP (mmHg)

IOP was not statistically different between the two groups at the 1st week, 1st and 3rd months postoperative follow ups, with p-value = 0.475, 0.391 and 0.243 respectively. Also, same finding in the amount of change in IOP at the 1st and 3rd month follow ups; with p-value = 0.688 and 0.679 respectively. On the other hand, IOP statistically increased in both groups at the 3rd month follow ups than at the 1st week follow up, with p-value = 0.019 and <0.001 respectively.

### 4.3. Mean Endothelial Cell Density (MCD)

Mean endothelial cell density did not differ significantly between the two studied groups at the 1st week, 1st and 3rd month postoperative follow ups, with p-value = 0.773, 0.998 and 0.976 respectively. MCD decreased significantly in group 1 and group 2 at the 3rd month follow ups than at the 1st week, with p-value < 0.001 and 0.007 respectively. The comparison between both groups regarding the reduction amount in MCD at the 1st month and 3rd month follow ups showed higher decrease in second group than the first one, but did not reach statistically significant difference, with p-value = 0.204 and 0.686 respectively. (Figure 1)

### 4.4. CCT (Central Corneal Thickness)

CCT did not differ significantly between the two studied groups at the 1st week, 1<sup>st</sup> and 3rd month postoperative follow ups. Yet, increased significantly in group 1 and group 2 at the 3rd month follow ups than at the 1st week follow ups. The comparison between both groups regarding the amount of change in CCT at the 1st and 3rd month follow ups, showed higher increase in group 2 than in group 1, but with statistically insignificant difference with p-value = 0.140 and 0.273 respectively. (Table 2)

### 4.5. Hexagonal Cell Percentage (HEX)

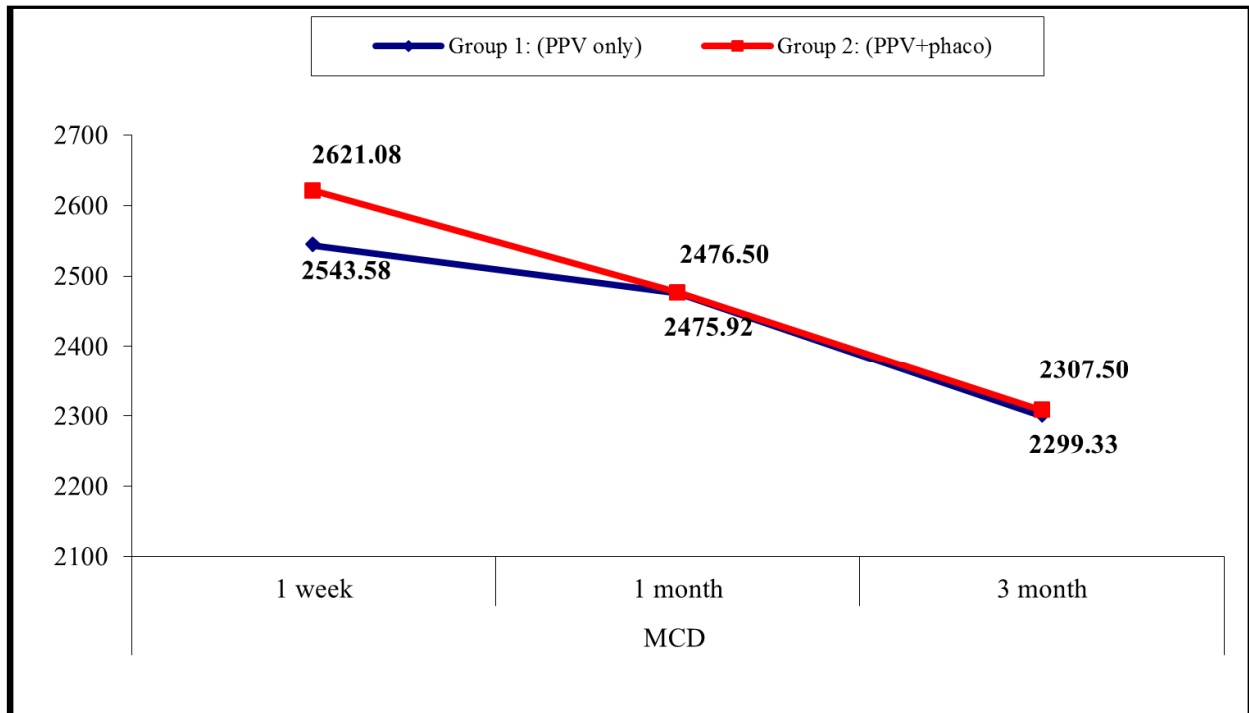
Hexagonal cell percentage did not differ significantly between the two studied groups at the 1st week, 1st month and 3rd month postoperative follow ups, with p-value = 0.249, 0.183 and 0.802 respectively. Also, HEX decreased significantly in group 1 and group 2 at the 3rd month follow ups than at the 1st week, with p-value = 0.010 and <0.001 respectively. The comparison between both groups regarding the amount of change in HEX at the 1st month and 3rd month

follow ups, showed higher decrease in group 2 than in group 1, but did not reach statistically significant difference with p-value = 0.383 and 0.147 respectively. (Figure 1)

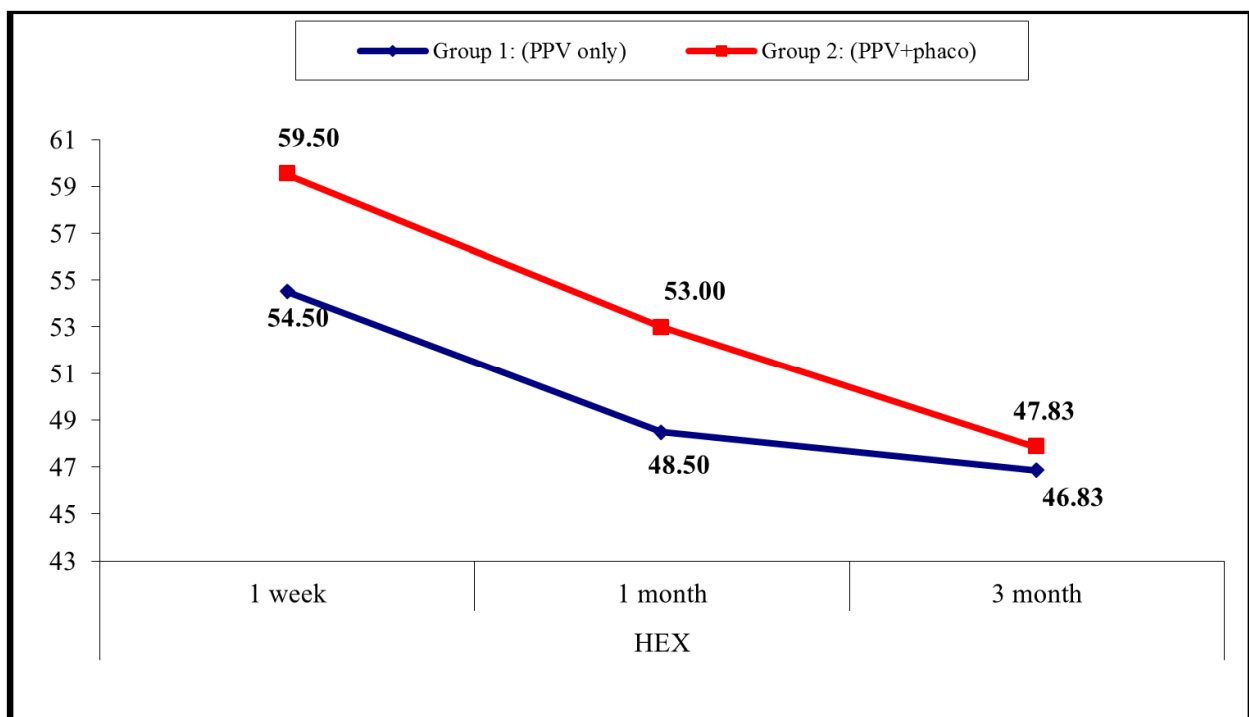
#### 4.6. Coefficient of Variation (CV)

Coefficient of variation did not differ significantly between the two groups at the 1st week, 1st and 3rd month

postoperative follow ups, yet there was statistically significant increase in the CV in group 1 and group 2 at the 3rd month follow ups than at the 1st week follow up. The comparison between both groups regarding the amount of change in CV at the 1st month and 3rd month follow ups, showed statistically significant higher increase in group 2 than in group 1, with p-value = 0.022 and 0.025 respectively. (Table 3).



**Figure 1.** Comparison between the two studied groups regarding MCD Mean endothelial cell density at postoperative follow up at 1 week, 1 month and 3 months.



**Figure 2.** Comparison between the two studied groups regarding HEX at postoperative follow up at 1 week, 1 month and 3 months.

**Table 1.** Comparison between the two studied groups regarding BCVA preoperative and postoperative follow up at 1 week, 1 month and 3 months.

BCVA (Log MAR)		Group 1: (PPV only) No. = 12	Group 2: (PPV+ phaco) No. = 12	Test value	P-value	Sig.
Pre-operative	Mean $\pm$ SD	1.81 $\pm$ 0.15	1.83 $\pm$ 0.19	-0.360•	0.722	NS
	Range	1.4 – 1.9	1.3 – 2			
1 week	Mean $\pm$ SD	1.63 $\pm$ 0.32	1.73 $\pm$ 0.26	-0.779•	0.444	NS
	Range	1 – 1.9	1 – 2			
1 month	Mean $\pm$ SD	1.49 $\pm$ 0.38	1.71 $\pm$ 0.25	-1.656•	0.112	NS
	Range	1 – 1.9	1 – 1.9			
3 months	Mean $\pm$ SD	1.25 $\pm$ 0.44	1.59 $\pm$ 0.42	-1.953•	0.064	NS
	Range	0.5 – 1.7	0.5 – 1.9			
Repeated Measure ANOVA test		21.283	8.704			
P-value		<0.001 (HS)	0.009 (HS)			
Difference from Pre						
1 week	Mean $\pm$ SD	-0.18 $\pm$ 0.20	-0.11 $\pm$ 0.09	-0.684‡	0.494	NS
	Range	-0.7 – 0	-0.3 – 0			
1 month	Mean $\pm$ SD	-0.32 $\pm$ 0.27	-0.13 $\pm$ 0.09	-1.916‡	0.055	NS
	Range	-0.8 – 0	-0.3 – 0			
3 months	Mean $\pm$ SD	-0.56 $\pm$ 0.32	-0.24 $\pm$ 0.25	-2.831‡	0.005	HS
	Range	-1.2 – -0.2	-0.8 – 0			

P-value >0.05: Non significant (NS); P-value <0.05: Significant (S); P-value < 0.01: highly significant (HS) •: Independent t-test; ‡: Mann Whitney test.

**Table 2.** Comparison between the two studied groups regarding CCT at postoperative follow up at 1 week, 1 month and 3 months.

CCT (um)		Group 1: (PPV only) No. = 12	Group 2: (PPV+ phaco) No. = 12	Test value	P-value	Sig.
1 week	Mean $\pm$ SD	522.50 $\pm$ 27.76	514.67 $\pm$ 26.95	0.701•	0.490	NS
	Range	496 – 565	480 – 550			
1 month	Mean $\pm$ SD	531.83 $\pm$ 33.81	537.58 $\pm$ 23.55	-0.483•	0.634	NS
	Range	470 – 570	497 – 570			
3 months	Mean $\pm$ SD	553.08 $\pm$ 22.13	548.17 $\pm$ 33.12	0.651•	0.522	NS
	Range	495 – 773	491 – 601			
Repeated Measure ANOVA test		4.795	8.599			
P-value		0.044 (S)	0.006 (HS)			
Difference from 1 week						
1 month	Mean $\pm$ SD	9.33 $\pm$ 17.47	22.92 $\pm$ 20.09	-1.475‡	0.140	NS
	Range	-26 – 42	2 – 63			
3 months	Mean $\pm$ SD	40.58 $\pm$ 56.86	33.50 $\pm$ 36.15	-1.097‡	0.273	NS
	Range	-7 – 208	-59 – 89			

P-value >0.05: Non significant (NS); P-value <0.05: Significant (S); P-value < 0.01: highly significant (HS) •: Independent t-test; ‡: Mann Whitney test.

**Table 3.** Comparison between the two studied groups regarding CV Coefficient of variation at postoperative follow up at 1 week, 1 month and 3 months.

CV		Group 1: (PPV only) No. = 12	Group 2: (PPV+phaco) No. = 12	Test value	P-value	Sig.
1 week	Mean $\pm$ SD	31.25 $\pm$ 4.49	29.25 $\pm$ 4.35	1.107•	0.280	NS
	Range	22 – 39	22 – 39			
1 month	Mean $\pm$ SD	32.83 $\pm$ 3.71	33.58 $\pm$ 4.70	-0.434•	0.669	NS
	Range	25 – 39	25 – 40			
3 months	Mean $\pm$ SD	34.58 $\pm$ 4.29	35.75 $\pm$ 4.16	-0.676•	0.506	NS
	Range	27 – 44	28 – 42			
Repeated Measure ANOVA test		6.928	45.82			
P-value		0.021 (S)	<0.001 (HS)			
Difference from 1 week						
1 month	Mean $\pm$ SD	1.58 $\pm$ 2.15	4.33 $\pm$ 2.96	-2.292‡	0.022	S
	Range	-4 – 5	1 – 10			
3 months	Mean $\pm$ SD	3.33 $\pm$ 4.31	6.50 $\pm$ 2.58	-2.235‡	0.025	S
	Range	-8 – 10	3 – 12			

P-value >0.05: Non significant (NS); P-value <0.05: Significant (S); P-value < 0.01: highly significant (HS) •: Independent t-test; ‡: Mann Whitney test.

## 5. Discussion

Specular microscopy allows proper clinical evaluation of corneal endothelial cell density and function, which is crucial

in validating endothelium functional reserve for patients before any intraocular surgery [8].

Loss of corneal endothelial cells (EC) out of SO keratopathy, cataract and glaucoma are variable anterior segment complications reported after vitreoretinal surgery [9,

10]. Silicone oil keratopathy may progress to corneal decompensation where a keratoplasty is mandatory [11]. In our study, we evaluated endothelial cell density (ECD) changes by means of non-contact specular microscopy in eyes that had PPV only (group 1) and in eyes had PPV with phaco (group 2).

We reported that log MAR BCVA did not differ significantly between the two studied groups preoperative at the 1st week, 1st and 3rd month follow ups, but decreased significantly in both groups at 3rd month follow ups relative to preoperative. This comes in agreement with *Tayyab et al., 2017* but in contradictory with *Koushan et al., 2017* and *Muslim et al., 2020*, where BCVA in phaco-PPV group was improved than the PPV only group and with statistically significant difference and this is explained by removal of the cataract that affect the phakic group [12-14].

In *Koushan et al., 2017*, they found log MAR BCVA change was more significant in combined phaco- vitrectomy group (- 56.6%±24.3%), in comparison to the PPV group (- 38.6%±45.5%) [13].

Also, in *Muslim et al., 2020* visual acuity did not differ between the two groups preoperatively and on first week follow-up. With a significantly better visual acuity in combined phaco- vitrectomy [14].

In our study, we reported non statistically significant difference between the two studied groups regarding IOP at the 1st week, 1st and 3rd months postoperative follow ups, in agreement with *Tayyab et al., 2017* and *Yorgun et al., 2016* [12, 15].

On the other hand, we found a statistically significant rise in the IOP in group 1 and group 2 at 3rd month follow ups than at 1st week follow up. This is explained by anterior chamber inflammation persistence, being steroid responder or a retained small SO droplets in anterior chamber angle. IOP increase didn't exceed the reading of 22 mmHg by Goldmann applanation tonometry in any of the studied patients. Thus, according to The European Glaucoma society and the linked Egyptian Glaucoma Society, did not require prescribing any antiglaucoma (below 24 mmHg) after assessing risk profile of the patient and decision is patient customized [16].

In *Tayyab et al., 2017* study, IOP did not show statistically significant difference in both groups Group A (phaco-vitrectomy) and Group B (PPV only) preoperatively (14.4±3.1 mm Hg versus 14.35±3.21 mm Hg in Group-B. On 1st post-operative day, the mean IOP in Group-A got higher reading than in Group-B. Yet, at 6 months follow-up, there was no significant difference in the mean IOP of both groups [12].

*Yorgun et al., 2016* retrospectively studied a total of 306 eyes (161 with phaco-vitrectomy and 145 with PPV alone). They found that the preoperative IOP was 15.4±4.1 mm Hg in vitrectomy alone and 15.1±2.4 mm Hg in phaco-vitrectomy group. Also Mean IOP did not differ significantly at the postoperative 1st week, 1st, 2nd, 4th, and 6th months [15].

As regards Mean endothelial cell density (MCD), did

not differ significantly between the two studied groups at the 1st week, 1st and 3rd month postoperative follow ups but decreased significantly in group 1 and group 2 at the 3rd month follow ups than at the 1st week. This concludes that less endothelial cell loss is noted in phakic patients, explained by avoiding the damaging effect of: ultrasound, lens fragments mechanical contact, thermal effects, the anterior chamber fluid dynamics and instruments direct trauma on endothelial cells and the barrier effect of the intact normal lens between silicon oil and the endothelium. Accordingly, eyes underwent combined phaco-vitrectomy were more liable to endothelial loss than eyes with phakic state. This goes with *Ibrahim et al., 2018*, but contradicts *Eom et al., 2013* study which found that there was a significantly higher mean endothelial cell loss in the combined phacovitrectomy than that in the PPV with fragmentation group both at 1 and 3 months postoperatively. They explained this in the fragmentation group by avoiding the risk factors for loss of the endothelial cells during phacoemulsification, as phaco power, the anterior capsule careful preservation till the final step of surgery and passive drainage of anterior chamber retained OVDs in the PPV with fragmentation group [17, 18].

As regards CCT, we had similar results with *Ibrahim et al., 2018*, did not differ significantly between the two studied groups at the 1st week, 1st and 3rd month postoperative follow ups [17].

As regards CV, we agreed with *Farrahi et al., 2014* and *Ibrahim et al., 2018* regarding the increase in CV at the 1st week, 1st and 3rd month postoperative follow ups in both groups,

Also, our results agreed with theirs, in finding no statistically significant difference between the 2 groups regarding the decrease in HEX. *Farrahi et al.* found that the presence of SO in phakic and pseudophakic eyes, proved to affect ECD non significantly, yet affected hexagonality significantly (P=0.004) and CV (P=0.003) [17, 19].

## 6. Conclusion

EC loss, polymegathism and pleomorphism were encountered in both groups with a statistically significant decrease in the MCD after PPV & SO injection with or without phacoemulsification. The postoperative change in MCD, CCT and HEX (pleomorphism) did not differ significantly between both groups. However, there was significant higher increase in CV (polymegathism) after combined phaco-vitrectomy than pars plana vitrectomy alone. So, whatever chosen for the patient: vitrectomy alone or phacovitrectomy, early SO removal after achieving the proposed tamponading, saves the cornea from SO keratopathy.

Our study had some limitations: limited number of patients, short follow up period of three months only. Further studies are needed overcoming these limitations.

## References

- [1] Anita Lyssek-Boroń, Katarzyna Krysiak, Magdalena Kijonka, Mateusz Osuch, Benjamin O. Grabarek, Dariusz Dobrowolski. "Changes in the Density of Corneal Endothelial Cells in Elderly Diabetic Patients After Combined Phacovitrectomy and Ex-PRESS Glaucoma Implants", *Current Pharmaceutical Biotechnology*, 2019.
- [2] Choi JY, Han YK. Long-Term ( $\geq 10$  Years) Results of corneal endothelial cell loss after cataract surgery. *Can. J. Ophthalmol.* 2018.
- [3] Corneal endothelial photography. Three-year revision. American Academy of Ophthalmology. *Ophthalmology* 1997; 104 (8): 1360-5.
- [4] Foster WJ. "Vitreous substitutes," *Expert Review of Ophthalmology*, 2008; 3 (2): 211–218.
- [5] Joussen AM and Wong D. "The concept of heavy tamponades—chances and limitations," *Graefe's Archive for Clinical and Experimental Ophthalmology*, 2008; 246 (9): 1217–1224.
- [6] Ryan JS. "Silicone oils: physicochemical properties," in *Retina*, vol. 3, pp. 2191–2210, Elsevier Mosby, 4th edition, 2006.
- [7] Beekhuis WH, van Rij G, Zivovnovic R. Silicone oil in the anterior chamber of the eye. *Arch Ophthalmol* 1986; 104: 793–794.
- [8] Huang J, Maram J, Tepelus TC, Modak C, Marion K, Sadda SR, Chopra V, Lee OL. Comparison of manual & automated analysis methods for corneal endothelial cell density measurements by specular microscopy. *Journal of optometry*. 2018; 11 (3): 182-91.
- [9] Toklu E, Altinisik M, Elbay A, Koytak A. Comparison of postoperative anterior segment changes associated with pars plana vitrectomy with and without vitreous base shaving. *International Journal of Ophthalmology*. 2020; 13 (11): 1745.
- [10] Goezinne, Fleur, Rudy M. Nuijts, Albert T. Liem, Igor J. Lundqvist, Tos J. Berendschot, Diana W. Cals, Fred Hendrikse, and Ellen C. La Heij. "Corneal Endothelial Cell Density After Vitrectomy With Silicone Oil for Complex Retinal Detachments" *Retina*, 2013.
- [11] Gupta K, Deng SX. Corneal Endothelial Decompensation. *Klinische Monatsblätter für Augenheilkunde*. 2020; 237 (06): 745-53.
- [12] Tayyab H, Khan AA, Javaid RM. Clinical outcome of 23g Trans-conjunctival pars plana vitrectomy-a prospective comparison of Phaco-Vitrectomy with only vitrectomy in phakic eyes. *Pakistan journal of medical sciences*. 2017; 33 (5): 1123.
- [13] Koushan K, Mikhail M, Beattie A, Ahuja N, Liszauer A, Kobetz L, Farrokhhyar F, Martin JA. Corneal endothelial cell loss after pars plana vitrectomy and combined phacoemulsification–vitrectomy surgeries. *Canadian Journal of Ophthalmology*. 2017; 52 (1): 4-8.
- [14] Muslim I, Khan AA, Chaudhry N. Anatomical and visual outcome of combined phaco-vitrectomy vs vitrectomy alone. *Pakistan Postgraduate Medical Journal*. 2020; 31 (04): 204-9.
- [15] Yorgun MA, Toklu Y, Mutlu M, Ozen U. Clinical outcomes of 25-gauge vitrectomy surgery for vitreoretinal diseases: comparison of vitrectomy alone and phaco-vitrectomy. *International journal of ophthalmology*. 2016; 9 (8): 1163.
- [16] Michael A. Kass, Dale K. Heuer, Eve J. Higginbotham, et al. The Ocular Hypertension Treatment Study Randomized Trial Determines That Topical Ocular Hypotensive Medication Delays or Prevents the Onset of Primary Open-Angle Glaucoma *Arch Ophthalmol*. 2002; 120 (6): 701-713.
- [17] Ibrahim SF, Zaki HA, Dabour SA, Eid AM. Evaluation of corneal endothelial cells after pars plana vitrectomy. 2018; 24: 7.
- [18] Eom Y, Kim SW, Ahn J, Kim JT, Huh K. Comparison of cornea endothelial cell counts after combined phacovitrectomy versus pars plana vitrectomy with fragmentation. *Graefe's Archive for Clinical and Experimental Ophthalmology*. 2013; 251 (9): 2187-93.
- [19] Farrahi F, Fegghi M, Ostadian F, Alivand A. Pars plana vitrectomy and silicone oil injection in phakic and pseudophakic eyes; corneal endothelial changes. *Journal of ophthalmic & vision research*. 2014; 9 (3): 310.