

## Case Report

# Optic Neuropathy and Scleritis as the Presenting Feature of Lepra Reaction

Nishikant Borse<sup>1,\*</sup>, Veena Borse<sup>1</sup>, Tanvi Borse<sup>2</sup>, Shiamak Cooper<sup>2</sup>

<sup>1</sup>Department of Vitreous & Retina, Insight Eye Clinic, Mumbai, India

<sup>2</sup>Seth Gordhandas Sunderdas Medical College & King Edward Memorial Hospital, Mumbai, India

### Email address:

nishikantborse@yahoo.com (N. Borse)

\*Corresponding author

### To cite this article:

Nishikant Borse, Veena Borse, Tanvi Borse, Shiamak Cooper. Optic Neuropathy and Scleritis as the Presenting Feature of Lepra Reaction. *International Journal of Ophthalmology & Visual Science*. Vol. 6, No. 2, 2021, pp. 108-114. doi: 10.11648/j.ijovs.20210602.18

Received: May 13, 2021; Accepted: June 1, 2021; Published: June 15, 2021

**Abstract:** A major problem in the management of leprosy patients is the occurrence of "reactions". These reactions are the consequences of the dynamic nature of the immune response to *Mycobacterium leprae* (*M. leprae*) that may occur before, during, or following the completion of multi-drug therapy (MDT). They can be of two types- Type 1 lepra reaction and Type 2 lepra reaction also known as Erythema Nodosum Leprosum (ENL). We report an unusual case of a 35 year old male patient who initially presented with complaints of a central scotoma. He neither had visible skin lesion suggestive of leprosy nor a history of either completion or concurrent anti leprosy drug treatment. He was diagnosed to be a case of anterior ischemic optic neuropathy for which he was treated with intravenous injections of methylprednisolone to which he significantly responded. Two months later, he complained of diminution of vision, redness and pain in the left eye which was diagnosed as scleritis. He was managed with topical prednisolone acetate eye drops. Within a week, the patient developed skin lesions over the cheekbones, ear lobules and the back of his hands. He was referred to a rheumatologist and a dermatologist for the same. The dermatologist suspected the lesions to be a manifestation of a Lepra Reaction. The presence of lepra bacilli was confirmed after taking a biopsy from the raised lesions and he turned out to be a case of undiagnosed lepromatous leprosy. He was subsequently treated with anti-leprosy drugs according to the WHO-MDT-MB along with a cover of steroids. After three months of initiation of this treatment, his ocular and dermatological lesions completely resolved. This is a unique case in which anterior ischemic optic neuropathy and scleritis preceded the symptom of leprosy, manifested as skin lesions.

**Keywords:** Optic Neuropathy, Scleritis, Uveitis, Leprosy, Lepra Reactions

## 1. Introduction

The occurrence of immunologically mediated episodes of acute or subacute inflammation known as "reactions", are major problem in the management of leprosy patients [1]. They can be of two types- Type 1 lepra reaction and Type 2 lepra reaction also known as Erythema Nodosum Leprosum (ENL).

Type 1 lepra reaction is a delayed hypersensitivity reaction occurring most frequently in patients of borderline leprosy. It often occurs after treatment for leprosy has been started, but it may also occur before treatment or after the end of the treatment. It can either be worsening of the current lesions or

formation of new skin lesions along with nerve involvement in severe cases. Type 2 lepra reaction is an acute immune-complex mediated vasculitis. ENL affects about 50% of patients with lepromatous leprosy (LL) and 10% of borderline lepromatous (BL) patients [2]. The usual lesions involve crops of inflamed subcutaneous nodules along with systemic manifestations such as fever, lymphadenopathy, arthralgias and neuritis.

In patients with leprosy, the eyes are frequently affected. The incidence of ocular involvement in leprosy has been variously quoted as 51% to 69% [3]. Ocular manifestations include madarosis, lagophthalmos, corneal exposure, keratitis, corneal ulceration and scarring, episcleritis and scleritis,

conjunctival and scleral lepromas, uveitis, uveal effusion, and retinal pearls and detachment [4-7]. Areas of infiltration become visible with thickening of the tissues. Nodules varying in size from a pinhead to large masses may be present. Optic nerve involvement in leprosy is very rare.

Here we report an unusual case of 35 years old male patient who presented with anterior ischemic optic neuropathy, with no visible skin lesion suggestive of leprosy and no history of either completion of or concurrent anti leprosy drug treatment, which eventually turned out to be a case of undiagnosed lepromatous leprosy.

## 2. Case Report

A 35 year old male presented in our clinic with the complaints of a central scotoma since 4 months. He had been

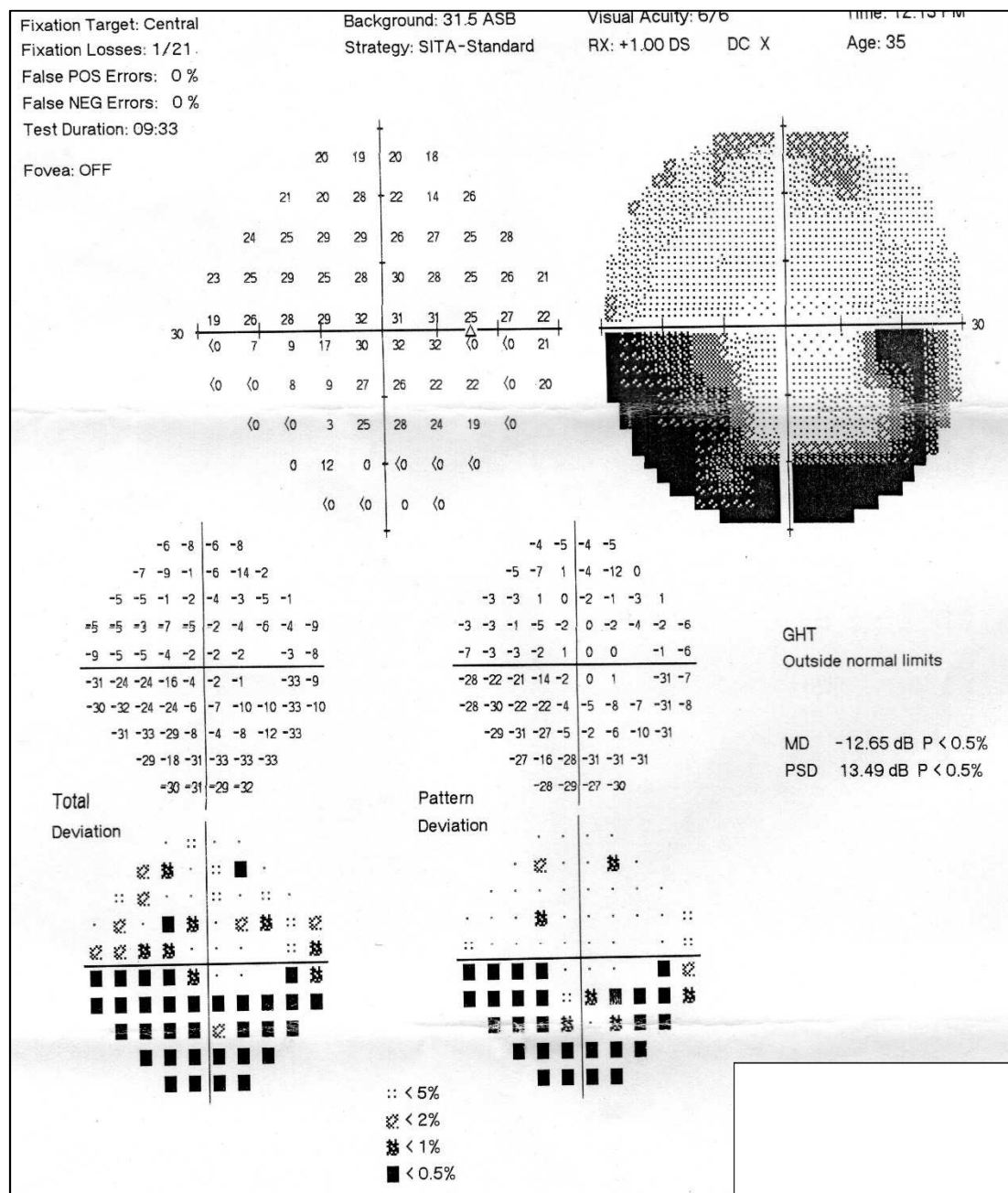
previously visiting for complaints of seeing black spots inferiorly with diminution of vision. He was diagnosed elsewhere to have a macular edema. There was no significant systemic history other than a history of psoriatic skin lesions for which he was on oral antihistaminics.

On ophthalmologic examination, the best corrected visual acuity in both the eyes was 20/20, N6. His intraocular pressure measured with Perkins tonometer was 16 mmHg.

On slit lamp bio microscopy he was found to have a normal anterior segment.

Fundus examination with indirect ophthalmoscope revealed an oedematous optic nerve. There were no haemorrhages around the disc.

An optical coherence tomography was done, A 30-2 perimetry showed inferior altitudinal defect in both the eyes (Figure 1).



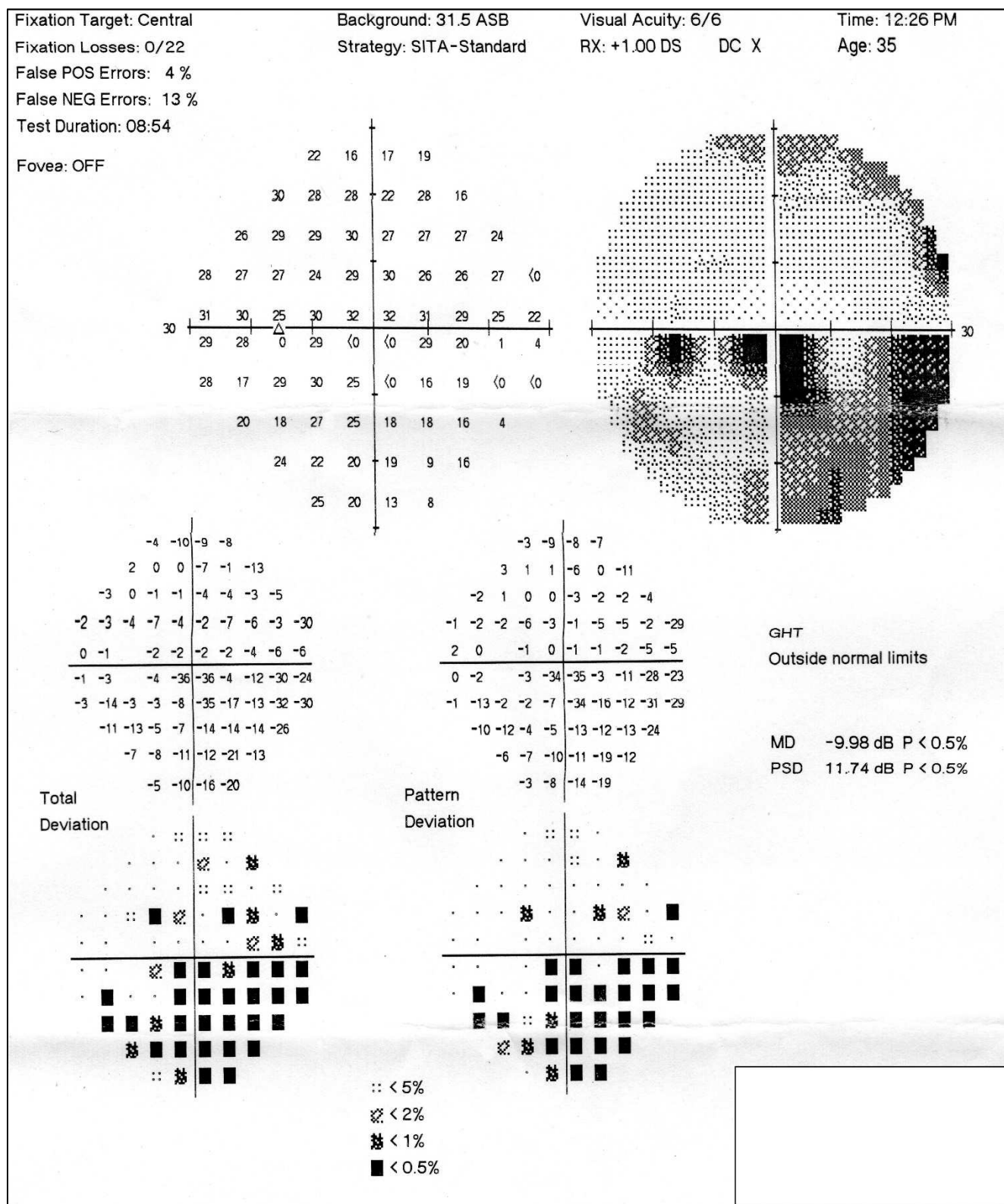


Figure 1. Perimetry field of the Right and left eye of the patient showed inferior altitudinal defect in both the eyes.

In view of his clinical findings and perimetry, he was diagnosed to have a non arteritic anterior optic neuropathy.

On consultation with his dermatologist, it was suggested that his skin lesions were due to vasculitis.

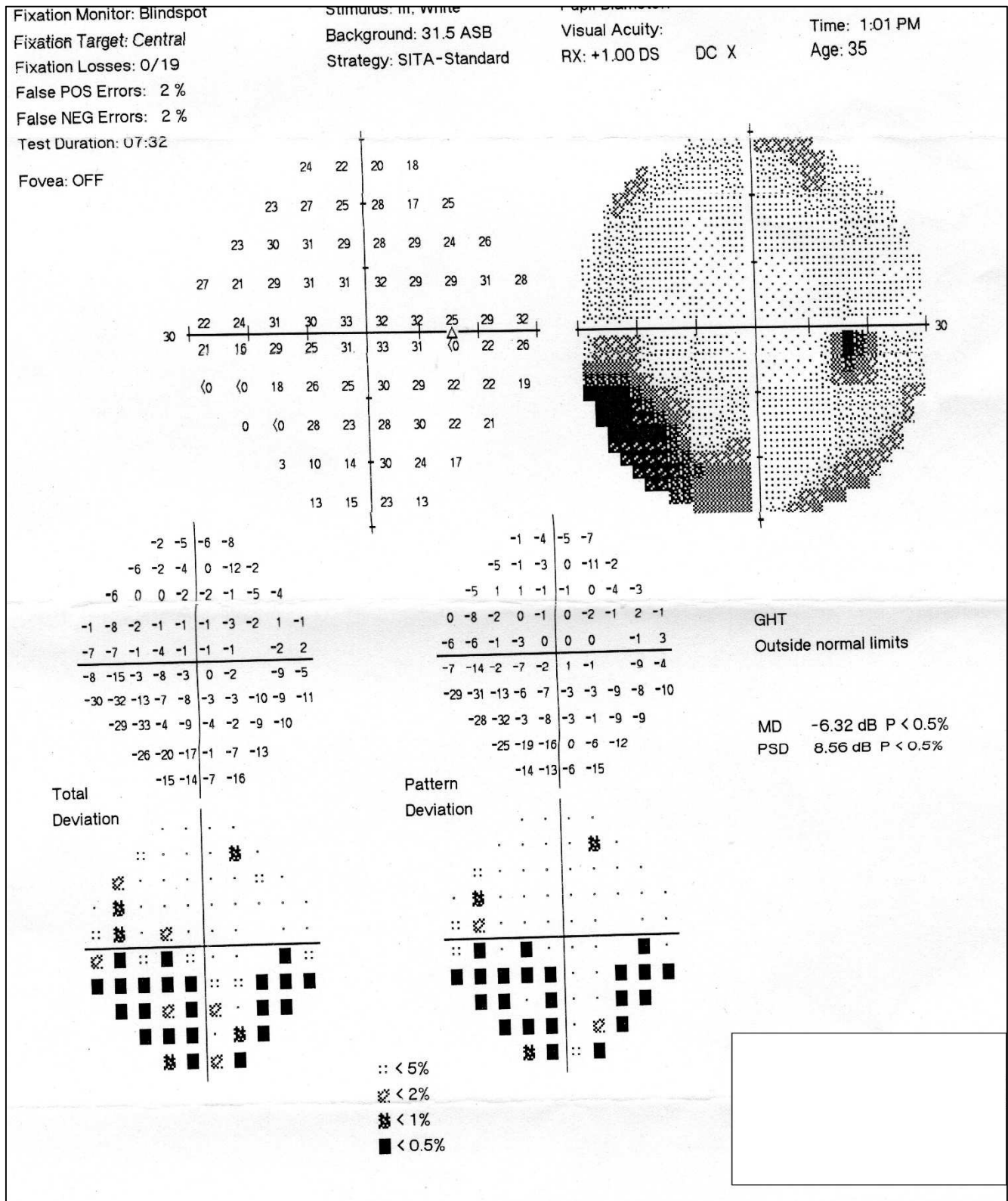
Patient was investigated systemically for routine blood

investigations and also the auto immune disorders workup. Other than an increased erythrocyte sedimentation rate there were no significant findings.

Patient was administered Injection Methylprednisolone 1 gram intravenously for 3 days. He had a significant resolution

of the optic nerve edema. Symptomatically the central scotoma resolved significantly. The perimetry was repeated

three weeks after the course of steroids, and showed a significant reduction in the altitudinal defect (Figure 2).



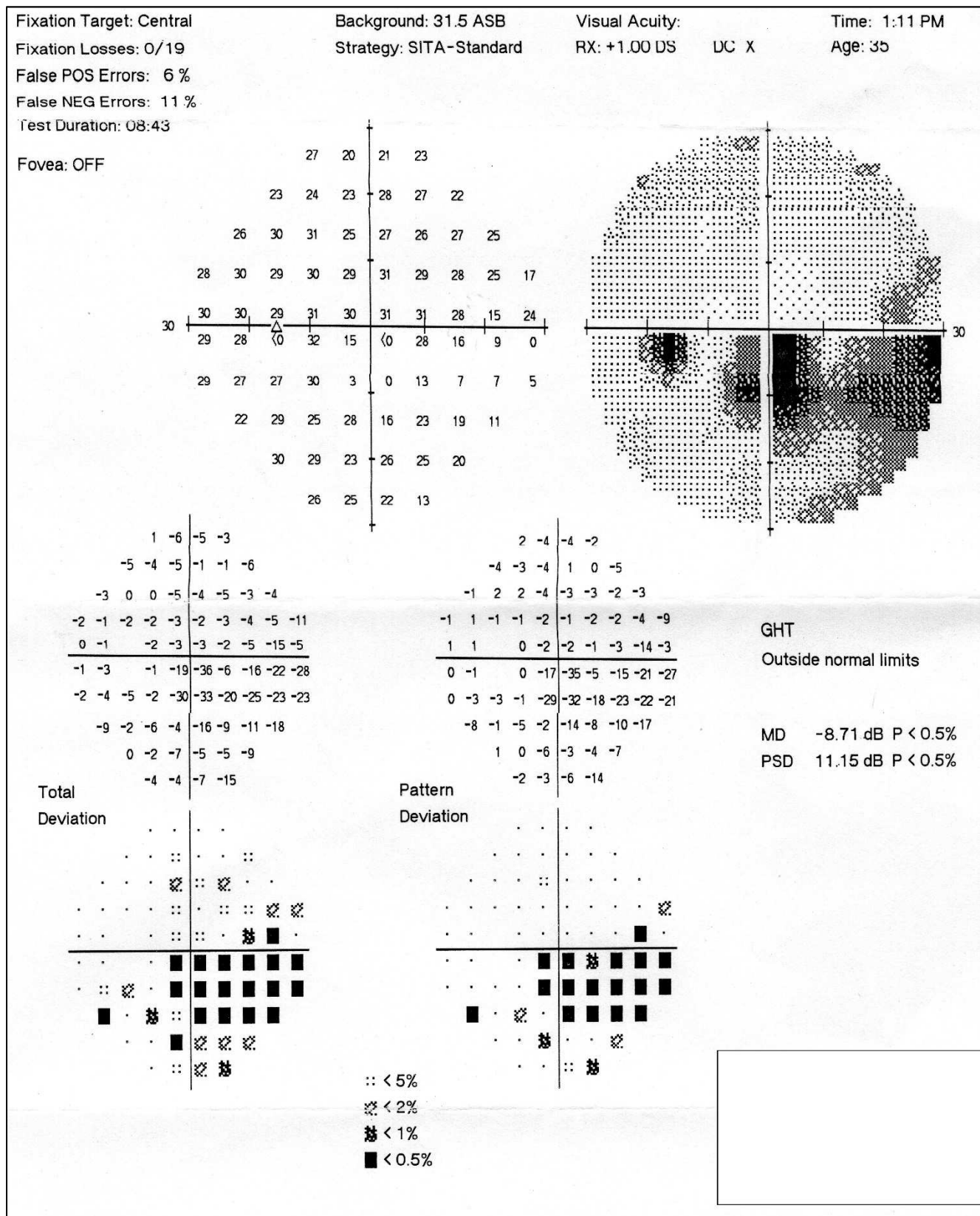
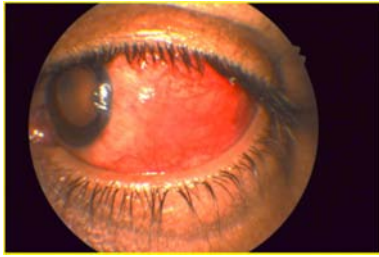

Figure 2. Perimetry field of the Right and left eye of the patient showed significant reduction in the altitudinal defects.

The patient presented again at the clinic two months later with complaints of diminution of vision, redness and pain, in the left eye. There was congestion which was localised in

nature on the temporal side of the left eye (Figure 3). It was diagnosed as scleritis and he was given topical prednisolone acetate eye drops.



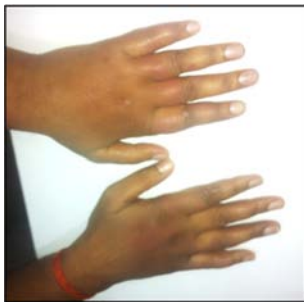

**Figure 3.** Redness and congestion in the left eye.

There were no other skin lesions, peripheral nerve thickening or sensory loss. However, within a week the patient also developed raised patches over the cheek bones bilaterally and also thickening over the ear lobules and swelling over the back of his hands. These dermal lesions were red, more prominent, swollen, shiny and warm, but not painful. (Figure 4)

Suspecting an autoimmune etiology he was referred to an immunologist. The immunologist took another opinion from a dermatologist for the skin lesions. The dermatologist suspected the lesions to be manifestation of a LR.

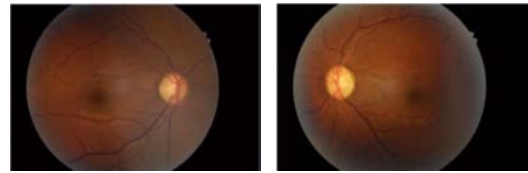
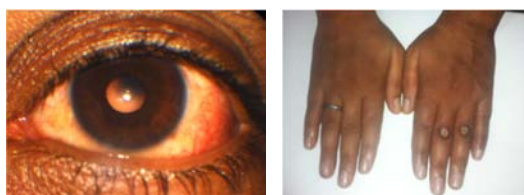The biopsy of specimen taken from the raised lesion confirmed presence of lepra bacilli.



**Figure 4.** Dermal Lesions on the hands.

### 3. Treatment

The patient was started on leprosy treatment (WHO-MDT-MB) and prescribed along with it a cover of steroids to reduce the inflammation. The initiation of anti-leprosy treatment caused mild fever and slight increase in the dermal lesions; he also developed breathlessness in the first week of the treatment. But these toxic symptoms gradually waned off. After one month of the treatment, ocular congestion regressed totally and skin lesions showed healing with ulceration and pigmentation. After three months of anti-lepra treatment with (WHO-MDT-MB, oral prednisolone) patient was totally free of the ophthalmic as well as dermal lesions. (Figure 5)



**Figure 5.** Three months of anti-lepra treatment cured ophthalmic and dermal lesions.

### 4. Discussion

Nerve involvement in leprosy occurs prior to any clinical manifestation. However, optic nerve involvement in leprosy is very rare. [8] The optic nerve escapes probably because it is devoid of Schwann cells. [9] Detailed search of medical databases like Medline, EMBASE, etc., failed to reveal any information about optic neuropathy and scleritis as the presenting feature of LR. To the best of our knowledge this is one of the first cases where eye is the primary site of the LR.

Leprosy is a disease with chronic and disabling complications, and ocular involvement can be permanent and may progress long after treatment has been completed. The global leprosy population is estimated to be around 12 million, and an ophthalmologist may be the first one to encounter such a patient. In such a scenario, suspicion and detection of ocular findings may lead to early treatment of the infection.[10] The isolation of lepra bacilli from the skin smear in patients and multidrug therapy completion highlights the potential role of bactericidal agents in the planned intraocular treatment. Leprea reactions need careful titration of oral steroids and appropriate antibacterial agents. [11]

In our case report, the patient presented with anterior optic neuropathy and scleritis. He was then investigated by a dermatologist for swelling in both hands and feet, with nodules and rashes over his body; especially in the malar region of his face. These lesions had appeared a week after he was prescribed and treated with topical prednisolone acetate eye drops as part of treatment protocol for scleritis. This is a unique case in which anterior ischemic optic neuropathy and scleritis preceded symptoms of leprosy, manifested as skin lesions.

The timely diagnosis and initiation of anti-leprosy treatment led to the resolution of these lesions. Also the treatment with topical prednisolone acetate 1%, resulted in improvement of the ocular condition. His scleral congestion pertaining to the scleritis reduced along with the pain.

A close and long follow-up is required in these cases, as these patients are at risk of significant ocular morbidity, despite completing the multidrug therapy. [12]

### 5. Conclusion

This case report highlights the importance of keeping differential diagnosis wider in terms of infectious diseases, even though the disease may have been deemed to be eliminated. Such atypical cases do spring up surprises, but patient's interests have to be put on the priority and earliest opinion of the physician should be asked in case of systemic

findings. While dealing with infectious diseases like leprosy, we also need to keep in mind the possibility of the occurrence of hypersensitivity reactions. The basis of autoimmune diseases can also be infective in nature to begin with.

## References

- [1] Pandhi D, Chhabra N. New insights in the pathogenesis of type 1 and type 2 lepra reaction. *Indian J Dermatol Venereol Leprol* 2013; 79: 739-49. <https://dermnetnz.org/topics/lepra-reactions/>
- [2] Pocaterra L, Jain S, Reddy R, Muzaffarullah S, Torres O, Suneetha S, *et al.* Clinical course of erythema nodosum leprosum: An 11-year cohort study in Hyderabad, India. *Am J Trop Med Hyg* 2006; 74: 868-79.
- [3] Mahendradas P, Avadhani K, Ramachandran S, Srinivas S, Naik M, Shetty KB. Anterior segment optical coherence tomography findings of iris granulomas in Hansen's disease: a case report. *J Ophthalmic Inflamm Infect*. 2013; 3: 36. doi: 10.1186/1869-5760-3-36.
- [4] Centers for Disease Control and Prevention. Hansen's disease Updated November 19, 2009. Available at [http://www.cdc.gov/nczved/divisions/dfbmd/diseases/hansens\\_disease/technical.html](http://www.cdc.gov/nczved/divisions/dfbmd/diseases/hansens_disease/technical.html). Accessed: May 26, 2011.
- [5] World Health Organization (WHO). WHO Expert Committee on Leprosy. 7th Report. Available at <http://www.who.int/lep/resources/Expert.pdf>. Accessed: May 26, 2011.
- [6] WHO. Leprosy: global situation. World Health Organization. Available at <http://www.who.int/lep/situation/en/>. Accessed: January 27, 2010.
- [7] Salem RA. Ocular complications of leprosy in yemen. *Sultan Qaboos Univ Med J*. 2012 Nov. 12 (4): 458-64. [Medline]. [Full Text].
- [8] Prabha N, Mahajan VK, Sharma SK, Sharma V, Chauhan PS, Mehta KS, *et al.* Optic nerve involvement in a borderline lepromatous leprosy patient on multidrug therapy. *Lepr Rev*. 2013; 84: 316-21.
- [9] Arora VK, Dhaliwal U, Singh N, Bhatia A. Tuberculous optic neuritis histologically resembling leprosy neuritis. *Int J Lepr Other Mycobact Dis*. 1995; 63: 454-6.
- [10] Chaudhry IA, Shamsi FA, Elzaridi E, Awad A, Al-Fraikh H, Al-Amry M, *et al.* Initial diagnosis of leprosy in patients treated by an ophthalmologist and confirmation by conventional analysis and polymerase chain reaction. *Ophthalmology*. 2007; 114: 1904-11.
- [11] Bala Murugan, Sivaraman; Mahendradas, Padmamalini; Dutta Majumder, Parthopratim; Kamath, Yogish. Ocular leprosy: from bench to bedside. *Current Opinion in Ophthalmology*: November 2020 - Volume 31 - Issue 6 - p 514-520.
- [12] KM Waddell, PR Saunderson. Is leprosy blindness avoidable? The effect of disease type, duration, and treatment on eye damage from leprosy in Uganda. *BJO* 1995; 79: 250-256.