

Infectious Scleritis: Clinicomicrobiological Review of Infectious Scleritis

Anjana Somanath¹, Raksheeth Rajgopal Nathan¹, Lalitha Prajna², Rathinam Sivakumar¹

¹Department of Uvea, Aravind Eye Care System, Madurai, India

²Department of Microbiology, Aravind Eye Care System, Madurai, India

Email address:

anjana471306@gmail.com (A. Somanath)

To cite this article:

Anjana Somanath, Raksheeth Rajgopal Nathan, Lalitha Prajna, Rathinam Sivakumar. Infectious Scleritis: Clinicomicrobiological Review of Infectious Scleritis. *International Journal of Ophthalmology & Visual Science*. Vol. 5, No. 2, 2020, pp. 61-65.

doi: 10.11648/j.ijovs.20200502.15

Received: April 5, 2020; Accepted: April 29, 2020; Published: May 27, 2020

Abstract: Infectious scleritis due to an infective etiology can occur following accidental trauma or surgery. However, the clinical manifestations of infectious scleritis may be similar to immune mediated scleritis. Infectious scleritis is treated with antibiotic therapy and surgical intervention if required. Treatment with corticosteroids and immunosuppressives may clinically worsen the infectious scleritis. Hence a careful clinical evaluation is necessary to rule out infectious etiology before treatment. Poor prognosis is due to delay in diagnosis and treatment. This study aimed to analyse the risk factors, clinical outcome and treatment in patients with infectious scleritis. A retrospective study was done from January 2013 to December 2018. This study includes 11 eyes. Microbiology analysis was done on the drained material. 11 eyes were culture positive. They were treated according to culture sensitivity. One eye worsened clinically and required enucleation. However, the other eyes improved and visual acuity was maintained in the 10 eyes. In our study, trauma was the most common cause of infectious scleritis. The common organisms were Nocardia, coagulase negative Staphylococcus aureus and fungi. To conclude, trauma was the most common cause of infectious scleritis in our study. Therefore, early diagnosis and treatment can lead to a reduced rate of complication.

Keywords: Fungus, Infectious Scleritis, Microbiological Profile of Scleritis, Scleral, Abscess, Trauma

1. Introduction

Infectious scleritis is a rare manifestation seen in 5-10% of cases [1-3]. It presents with redness, pain and subconjunctival abscess. This subconjunctival abscess can be multiple or solitary. Infectious scleritis is caused by bacteria, virus, parasites and fungi [5, 6, 7, 11]. *Pseudomonas aeruginosa* is the most common organism reported in the literature [8, 9, 10]. *Streptococcus pneumoniae*, *Staphylococcus aureus* and *Nocardia* are the other organisms reported in the literature [14, 15]. However, fungi are the most commonly reported pathogen in tropical countries like India [12, 13]. These microorganisms enter the scleral tissues following surgeries such as pterygium excision, retinal detachment surgeries and strabismus surgeries [10, 16, 17, 18]. Injuries such as trauma with a stick or vegetative matter would be another cause for microorganisms to enter the eye.

Scleritis due to systemic autoimmune disease is clinically

similar to infectious scleritis. Treatment with corticosteroids would worsen the infection. Hence a careful clinical evaluation is necessary [11]. The abscess in infectious scleritis should be drained with appropriate oral antibiotic cover. Surgical debridement will debulk the infected necrotic tissue and provide better penetration of antimicrobial agents [19]. Delay in treatment has invariably poor prognosis or if untreated would result in an invasion of the organism into the adjacent tissues leading to visual loss, perforation and phthisis bulbi. Retrospective case studies in the literature have reported cases of culture positive infectious scleritis with ocular surgery being the most common risk factor [4, 12]. However, in our population trauma was the risk factor for infectious scleritis. Our study aims to analyse a series of infectious scleritis for the risk factor, clinical outcome and treatment depending on their microbiological profile.

2. Materials and Methods

The clinicomicrobiological profile of patients with infectious scleritis was analysed from January 2013 to December 2018. This is a retrospective study conducted in a tertiary eye hospital. Approval from institution ethics committee of Aravind medical research foundation was taken. We searched the electronic database of medical record department and the microbiology department to find cases of infectious scleritis. Inclusion criteria included patients with infectious scleritis following history of trauma or surgery. Only patients who underwent surgical debridement or wound exploration were included. Microbiology testing was done on the drained material. All patients with positive culture status were included in the study. Exclusion criteria included patients with a definite proven systemic or ocular autoimmune disease and previous history of recurrent episodes of redness or pain. Scleritis secondary to dissemination of infection from another site were also excluded from the study.

The average duration of presentation to our hospital after the onset of symptoms was one month. A few patients had taken treatment from an ophthalmologist and presented to us due to worsening of symptoms. They were treated with topical medications. Details of these topical medications were not known to the patient.

All patients had redness and pain following trauma or surgery. X-ray and B scan of the eye was done for the presence of intraocular foreign body. Hence, infectious scleritis was suspected and they were initially treated with oral broad spectrum antimicrobial drugs or oral fluoroquinolones or oral antifungal and topical antimicrobial

drugs. They also underwent incision and drainage of the abscess. The procedure was repeated if there was a recurrence of abscess or worsening of the clinical condition along with wound exploration to look for a retained foreign body in case of trauma. The material collected from the drained abscess was processed in the microbiology lab for Gram's stain and potassium hydroxide wet mount preparation. The microbial culture was evaluated using blood agar and potato dextrose agar. Cases which were culture positive for any microorganisms were treated according to culture sensitivity. An oral steroid was later added after a duration of 2-3 weeks to reduce the ocular inflammation.

The retrospective data collected were analysed for patient's demography, predisposing factors, clinical features, organisms isolated, treatment and clinical outcome

3. Results

In this study we evaluated 11 eyes of 11 patients. 9 patients were males and 2 patients were females. Pain (96%) and redness (89%) was the most common presenting symptom. The mean age of presentation was 58.45 +/- 13 years (Range: 38-71 years). Trauma was the most common risk factor seen in 8 eyes (72.72%). One eye (9.09%) developed scleral abscess following vitreoretinal surgery. However, in two eyes (18.18%) there were no risk factors. Coagulase negative *Staphylococcus aureus* (2 cases), *Nocardia* and fungi (*Aspergillus niger* and dematiaceous fungi) were the common organism in our study. Table 1 describes the demographic data, risk factors, culture sensitivity and outcome of 11 eyes which were culture positive.

Table 1. The demographic data, risk factors, culture sensitivity and outcome of 11 eyes which were culture positive.

	Age	Sex	Eye	Initial visual acuity	History/duration	Findings	Culture
1	38	M	OS	6/9	Trauma with stone/15 days	AC exudates, sclera abscess	Nocardia
2	50	F	OD	6/12	Nil/7 days	Uveitis, scleral abscess	Nocardia
3	71	M	OS	6/18 (cataract)	Trauma with thorn/21 days	Scleral abscess	<i>Aspergillus flavus</i>
4	58	M	OS	6/9 (cataract)	Trauma with thorn/15 days	Scleral abscess	Dematiaceous fungus Coagulase negative <i>Staphylococcus aureus</i>
5	65	M	OD	6/18 (cataract)	Trauma with thorn/15 days	Nodular scleritis with abscess	(CONS)
6	65	M	OS	6/18	Trauma with thorn/90 days	Scleral abscess	CONS
7	59	F	OS	HM (Post retinal surgery)	Scleral buckling/1 year	Scleral abscess, infected suture	MRSA
8	60	M	OD	6/24	Nil	Scleral abscess, hypopyon	<i>Pseudomonas</i>
9	57	M	OD	6/36 (cataract)	Trauma with vegetative matter/20 days	Scleritis, sclera abscess	<i>Achromobacter xylosoxidans</i>
10	66	M	OD	6/36 (cataract)	Trauma with thorn/30 days	Scleral abscess	Unidentified gram negative bacillus
11	54	M	OS	6/12	Trauma with thorn/30 days	Scleral abscess	<i>Alcaligenes faecalis</i>

Table 1. Continued.

	Medical therapy and outcome	Surgical therapy	Final visual acuity	Complications
1	Topical amikacin, sulfacetamide, systemic bactrim. (improved)	I&D	6/6	-
2	Topical gentamycin, systemic cefixime, levofloxacin, bactrim (enucleation)	I&D	PL	Phthisis
3	Topical itraconazole, systemic ketoconazole, augmentin, systemic steroids (static)	I&D twice	6/18	Persistent reactive scleritis
4	Topical voriconazole, systemic fluconazole, steroids (improved)	I&D thrice	6/6 (post cataract surgery)	-
5	Topical moxifloxacin, systemic cefixime, levofloxacin (improved)	I&D twice	6/18 (cataract)	-

	Medical therapy and outcome	Surgical therapy	Final visual acuity	Complications
6	Topical moxifloxacin, systemic cefixime, levofloxacin, bactrim, steroids (improved)	I&D thrice	6/12	Persistent reactive scleritis
7	Topical moxifloxacin, systemic doxycycline (improved)	Suture removal	HM	-
8	Topical moxifloxacin, chloramphenicol, systemic ceftazidime (improved)	I&D	6/9	-
9	Topical moxifloxacin, azithromycin, ceftazidime, systemic augmentin, steroids (static)	I&D, wound exploration and FB removal	6/36	Persistent reactive scleritis
10	Topical chloramphenicol, systemic ceftazidime, cephalixin, steroids (improved)	I&D	6/36	-
11	Topical cefotaxime, systemic cephalixin, augmentin (static)	I&D	6/18	-lost to follow up at 1 month

Nocardia was isolated from 2 eyes. These 2 cases had a different clinical course and outcome. The first case presented with eye pain and redness 15 days after trauma with a stone. Incision and drainage was done. Based on the culture and sensitivity results, the patient was treated with topical amikacin. The abscess resolved by one month. The second case presented with redness and pain in the eye for 7 days. There was no significant history. The patient was started on topical steroids, topical and oral antibiotics. The eye worsened significantly in a matter of days and the topical steroids were stopped. Multiple systemic, oral and topical antibiotics along with antifungal drops were added. Intravenous amikacin was advised but the patient refused treatment. By the end of the 2nd week, the eye had perception of light and at one month enucleation was advised.

Fungi were detected in 2 eyes. Both patients gave a history of trauma with vegetative matter that occurred about 2-3 weeks before presenting to us. The first case was positive for *Aspergillus niger* and required a second incision and drainage procedure at 2 weeks. The patient received itraconazole eye ointment and oral ketoconazole in addition to topical and systemic antibiotics. The ocular symptoms and signs did not deteriorate. However, the reactive scleritis did not decrease after a course of oral steroids and the patient remained symptomatic at the last follow up visit (5 months).

The other case was infected with a dematiaceous fungus that required incision and drainage. The procedure was done twice, at the 1st and 8th month. The patient received oral fluconazole along with voriconazole drops, in addition to oral steroids started at the 2nd month. There was a complete recovery. There were no recurrences till the last follow up (18 months).

Coagulase negative staphylococcus species was isolated from 2 abscesses. Both patients recalled a history of trauma with vegetative matter and required multiple abscess drainage procedures. One case had complete resolution of reactive scleritis (3 months). While the other case required oral steroids for reactive scleritis, which had not completely resolved at the last follow up (6 months). Both patients had received topical moxifloxacin and oral levofloxacin and cefixime.

Methicillin Resistant *Staphylococcus Aureus* (MRSA) was isolated from 1 sample. There was a history of scleral buckle surgery done 1.5 years before the onset of symptoms. Abscess drainage was done along with the removal of an infected suture. Recovery was uneventful with moxifloxacin

eye drops and oral doxycycline.

Pseudomonas aeruginosa was isolated from 1 eye. Cataract surgery was done in the same eye 10 years before the onset of symptoms. There was intense anterior chamber inflammation and hypopyon. Post incision and drainage, the patient was treated with intravenous ceftazidime, moxifloxacin eye drops. Oral prednisolone was started after one month. The patient had complete recovery at the last follow up (9 months).

Gram negative bacilli (GNB) other than *Pseudomonas* were isolated in 3 eyes. All the patients gave a history of trauma with the vegetative matter. Incision and drainage were done in all, systemic and topical antibiotics were administered.

One patient with *Achromobacter xylosoxidans* isolate required multiple abscess drainage procedures and wound exploration with foreign body removal was done. The patient was administered with fortified ceftazidime 5%, topical moxifloxacin and oral amoxicillin-clavulanate. The reactive scleritis persisted despite oral prednisolone in tapering doses at the last follow up (6 months). Another patient with unidentified gram negative bacilli improved completely after abscess drainage, topical chloramphenicol, intramuscular ceftazidime, oral cephalixin and oral steroids was started after one month.

The last patient had an *Alcaligenes faecalis* isolate and was lost to follow up by the end of the 1st month.

Visual acuity at presentation was good in 10 patients. However, 1 patient worsened clinically and required enucleation. Visual acuity was maintained in other patients.

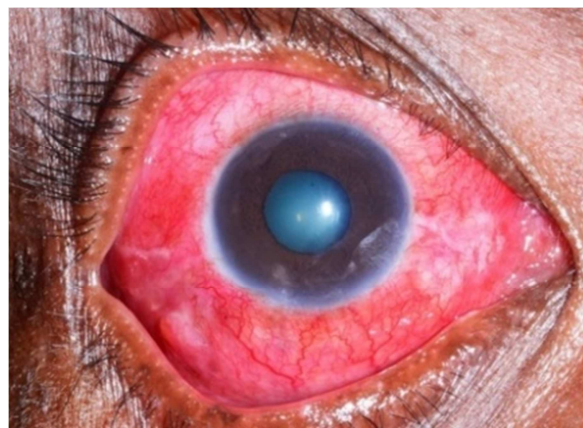


Figure 1. Digital photograph of the anterior segment of the right eye with infectious scleritis.

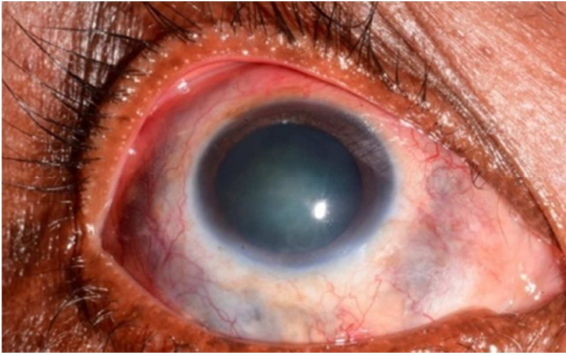


Figure 2. Digital photograph of the anterior segment of right eye with resolved infectious scleritis.

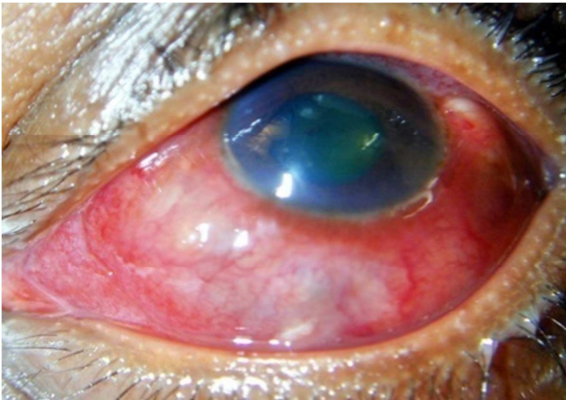


Figure 3. Digital photograph of the anterior segment of the left eye with infectious scleritis.

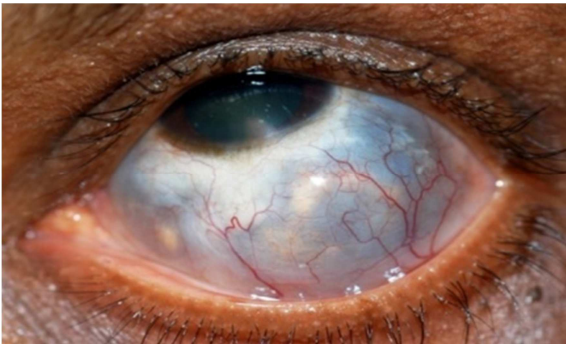

Figure 4. Digital photograph of the anterior segment of left eye with resolved infectious scleritis.

4. Discussion

Infectious scleritis should be diagnosed early and treatment should be initiated with oral and systemic antimicrobial drugs. Delayed treatment and diagnosis would lead to worsening of infectious scleritis. In this series of cases, trauma was the most common risk factor. Patients had responded well to topical and systemic antimicrobial drugs followed by oral steroids.

Trauma is the most common risk factor for infectious scleritis as reported in the literature [4, 12, 19]. Agriculture is the main occupation in India. Majority of the patients in our study were agricultural workers, who are prone to trauma with the vegetative matter. Hence redness and pain following

trauma, without previous ocular complaints, infectious scleritis should be suspected. X-ray, Computerised Tomography of orbit, B scan of the eye can be done for identifying the intraocular foreign body. In our study, the most common risk factor was trauma with the vegetative matter.

Pterygium excision is the most common surgical risk factor for infectious scleritis. [20] Use of beta irradiation and mitomycin C in pterygium surgery leads to prolonged inhibition of wound healing. [21] But in recent years, the use of an amniotic membrane to reconstruct the defect in the conjunctiva following pterygium excision may be the reason for the decline in pterygium surgery to be a risk factor for developing infective scleritis. [22] Due to the advancement in surgical techniques, the occurrence of infectious scleritis following amniotic membrane graft or fibrin glue in pterygium excision has reduced. Hence in our study, we do not have cases of infectious scleritis following pterygium excision. There are no reports in the literature of infectious scleritis following amniotic membrane graft or fibrin glue in pterygium excision.

Pseudomonas aeruginosa is the most common organism reported in the literature. [25] In our study *Nocardia*, coagulase negative *Staphylococcus*, methicillin resistant *Staphylococcus aureus* and fungi were isolated. In a tropical country like India where a large part of the population are agricultural workers and due to the hot and humid climate *Nocardia* and fungi are usually isolated. [5, 9, 10, 12, 23] Lin et al and Hso et al had reported only one case where fungal filaments were isolated [9, 23]. In infectious scleritis due to fungal etiology, other systemic foci of fungi has to be ruled out as haematogenous spread can lead to foci in the eye. Immunosuppressed conditions have to be ruled out. In our study our patients were immunocompetent and other systemic foci were ruled out.

Methicillin resistant *Staphylococcus aureus* can be a cause of infectious scleritis after ocular surgery despite good surgical prophylaxis. Feiz. Vet al has reported a case of infectious scleritis following pars plana vitrectomy. [26] However, in our retrospective study, one case had shown growth of Methicillin Resistant *Staphylococcus aureus* following vitreoretinal retinal surgery. Infectious scleritis developed 17 months after the surgery. Along with the abscess drainage, the infected suture was removed.

Cataract, glaucoma, panophthalmitis, perforation, exudative choroidal and retinal detachment can be seen as a consequence of infectious scleritis thereby leading to a poor visual outcome. Due to our early diagnosis and treatment, only 1 eye developed complication causing enucleation. The limitations of this study include a small sample size. We did not include eyes with other causes of infectious scleritis like tuberculosis.

5. Conclusion

To conclude, our results showed trauma to be the most

common predisposing factor for infectious scleritis. A careful clinical examination and early initiation of antimicrobial therapy resulted in good outcomes in our study. As infectious scleritis is a rare entity, it is not suspected at initial presentation. Therefore early diagnosis and prompt treatment can lead to a good clinical outcome with a reduced rate of complication.

References

- [1] Jabs DA, Mudun A, Dunn JP, Marsh MJ. Episcleritis and scleritis: clinical features and treatment results. *Am J Ophthalmol.* 2000; 130: 469–476.
- [2] Sainz de la Maza M, Jabbur NS, Foster CS. Severity of scleritis and episcleritis. *Ophthalmology.* 1994; 101: 389–396.
- [3] Tuft SJ, Watson PG. Progression of scleral disease. *Ophthalmology.* 1991; 98: 467–471.
- [4] Pradhan ZS, Jacob P. Infectious scleritis: clinical spectrum and management outcomes in India. *Indian J Ophthalmol.* 2013; 61: 590–593.
- [5] Reynolds MG, Alfonso E. Treatment of infectious scleritis and keratoscleritis. *Am J Ophthalmol.* 1991; 112: 543–547.
- [6] Loureiro M, Rothwell R, Fonseca S. Nodular Scleritis Associated with Herpes Zoster Virus: An Infectious and Immune-Mediated Process. *Case Rep Ophthalmol Med.* 2016; 2016: 8519394.
- [7] Reddy JC, Murthy SI, Reddy AK, Garg P. Risk factors and clinical outcomes of bacterial and fungal scleritis at a tertiary eye care hospital. *Middle East Afr J Ophthalmol.* 2015; 22: 203–211.
- [8] Hodson KL, Galor A, Karp CL, et al. Epidemiology and visual outcomes in patients with infectious scleritis. *Cornea.* 2013; 32: 466–472.
- [9] Hsiao CH, Chen JJ, Huang SC, Ma HK, Chen PY, Tsai RJ. Intrasceral dissemination of infectious scleritis following pterygium excision. *Br J Ophthalmol.* 1998; 82: 29–34.
- [10] Huang FC, Huang SP, Tseng SH. Management of infectious scleritis after pterygium excision. *Cornea.* 2000; 19: 34–39.
- [11] Sainz de la Maza M, Hemady RK, Foster CS. Infectious scleritis: report of four cases. *Doc Ophthalmol.* 1993; 83: 33–41.
- [12] Jain V, Garg P, Sharma S. Microbial scleritis-experience from a developing country. *Eye (Lond).* 2009; 23: 255–261.
- [13] Kumar Sahu S, Das S, Sharma S, Sahu K. Clinico-microbiological profile and treatment outcome of infectious scleritis: experience from a tertiary eye care center of India. *Int J Inflam.* 2012; 2012: 753560.
- [14] Cunningham MA, Alexander JK, Matoba AY, Jones DB, Wilhemus KR. Management and outcome of microbial anterior scleritis. *Cornea.* 2011; 30: 1020–1023.
- [15] Cunha LP da, Juncal V, Carvalhaes CG, Leão SC, Chimara E, Freitas D. Nocardialscleritis: A case report and a suggested algorithm for disease management based on a literature review. *Am J Ophthalmol Case Rep.* 2018; 10: 1–5.
- [16] Folk JC, Cutkomp J, Koontz FP. Bacterial scleral abscesses after retinal buckling operations. Pathogenesis, management, and laboratory investigations. *Ophthalmology.* 1987; 94: 1148–1154.
- [17] Chao DL, Albin TA, McKeown CA, Cavuoto KM. Infectious *Pseudomonas* scleritis after strabismus surgery. *J AAPOS.* 2013; 17: 423–425.
- [18] Kearney FM, Blaikie AJ, Gole GA. Anterior necrotizing scleritis after strabismus surgery in a child. *J AAPOS.* 2007; 11: 197–198.
- [19] Okhravi N, Oduduwa B, McCluskey P, Lightman S. Scleritis. *Surv Ophthalmol.* 2005; 50: 351–363.
- [20] Chaidaroon W, Supalaset S. *Pseudomonas* Scleritis following Pterygium Excision. *Case Rep Ophthalmol.* 2017; 8: 401–405.
- [21] Alsagoff Z, Tan DT, Chee SP. Necrotising scleritis after bare sclera excision of pterygium. *Br J Ophthalmol.* 2000; 84: 1050–1052.
- [22] Ma DH, See LC, Liao SB, Tsai RJ. Amniotic membrane graft for primary pterygium: comparison with conjunctival autograft and topical mitomycin C treatment. *Br J Ophthalmol.* 2000; 84: 973–978.
- [23] Lin CP, Shih MH, Tsai MC. Clinical experiences of infectious scleral ulceration: a complication of pterygium operation. *Br J Ophthalmol.* 1997; 81: 980–983.
- [24] O'Donoghue E, Lightman S, Tuft S, Watson P. Surgically induced necrotising sclerokeratitis (SINS)--precipitating factors and response to treatment. *Br J Ophthalmol.* 1992; 76: 17–21.
- [25] Foster CS, Maza MS de la. Infectious scleritis: the Massachusetts Eye and Ear Infirmary experiences. In: Foster CS, Maza MS de la. *The sclera.* New York: Springer Science & Business Media; 1994. p. 242–247.
- [26] Feiz V, Redline DE. Infectious scleritis after pars planavirectomy because of methicillin-resistant *Staphylococcus aureus* resistant to fourth-generation fluoroquinolones. *Cornea.* 2007; 26: 238–240.