

# Voluminous Solitary Neurofibroma of the Nasosinus Cavities in an Undermedicalized Context: Reflection on a Case Collected in Bamako

Kassim Diarra<sup>1</sup>, Nfaly Konate<sup>1</sup>, Yaya Dembele<sup>3</sup>, Harouna Sanogo<sup>2</sup>, Kalifa Coulibaly<sup>1</sup>, Fatogoma Issa Kone<sup>1</sup>, Cisse Naoma<sup>1</sup>, Boubacary Guindo<sup>1</sup>, Siaka Soumaoro<sup>1</sup>, Dombia Kadidiatou Singare<sup>1</sup>, Mohamed Amadou Keita<sup>1</sup>

<sup>1</sup>Department of Surgery, University Hospital Gabriel Toure, Bamako, Mali

<sup>2</sup>Reference Health Center Kalanbancoro, Bamako, Mali

<sup>3</sup>Army Polyclinic Kati, Bamako, Mali

## Email address:

diarrakassim84@yahoo.fr (K. Diarra)

## To cite this article:

Kassim Diarra, Nfaly Konate, Yaya Dembele, Harouna Sanogo, Kalifa Coulibaly, Fatogoma Issa Kone, Cisse Naoma, Boubacary Guindo, Siaka Soumaoro, Dombia Kadidiatou Singare, Mohamed Amadou Keita. Voluminous Solitary Neurofibroma of the Nasosinus Cavities in an Undermedicalized Context: Reflection on a Case Collected in Bamako. *International Journal of Otorhinolaryngology*. Vol. 8, No. 1, 2022, pp. 21-24. doi: 10.11648/j.ijo.20220801.14

**Received:** May 20, 2022; **Accepted:** June 7, 2022; **Published:** June 16, 2022

---

**Abstract:** Neurofibroma is a benign tumor of the connective tissue developed mainly at the expense of the endoneurium of the peripheral nerves. Histologically, there are two types of neurofibroma: plexiform and solitary. The objective of this work was to report a case of solitary nasosinus neurofibroma in order to discuss diagnostic and therapeutic difficulties in a developing country. BA aged 17, with no known pathological history, was admitted to the service for a left nasal obstruction which had been evolving for about 4 years. The endonasal examination found a congestive mass, not bleeding on contact, filling the entire left nasal fossa pushing back the nasal septum on the right. Computed tomography showed a heterogeneous dense tissue process with cystic areas, filling the left nasal fossa with extension to the posterior sinuses, left maxilla. The patient was operated under general anesthesia via the left paralateronasal route. The tumor was difficult to cleave but not friable and not bleeding. The histological examination concludes to a neurofibroma. Conclusion: Solitary neurofibromas are uncommon and remain poorly understood. Literature data, rare, do not answer all the questions.

**Keywords:** Neurofibroma, Nasosinus Cavities, ENT Surgery

---

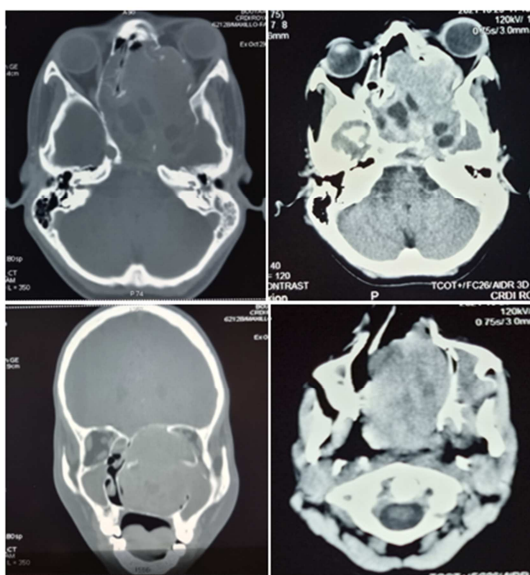
## 1. Introduction

Neurofibroma is a benign tumor of the connective tissue developed mainly at the expense of the endoneurium of the peripheral nerves [1]. Histologically, two types of neurofibroma are distinguished: plexiform and solitary [2, 3]. Plexiform neurofibromas associated with Von Recklinghausen disease are a more aggressive subtype of neurofibroma that infiltrate soft tissues to grow in multiple foci along the length of the affected nerve [3]. In contrast, solitary neurofibromas are well-demarcated, rubbery, firm, pearly-white lesions [2, 4]. Although the exact cause of solitary neurofibroma remains unclear, it is a hyperplastic

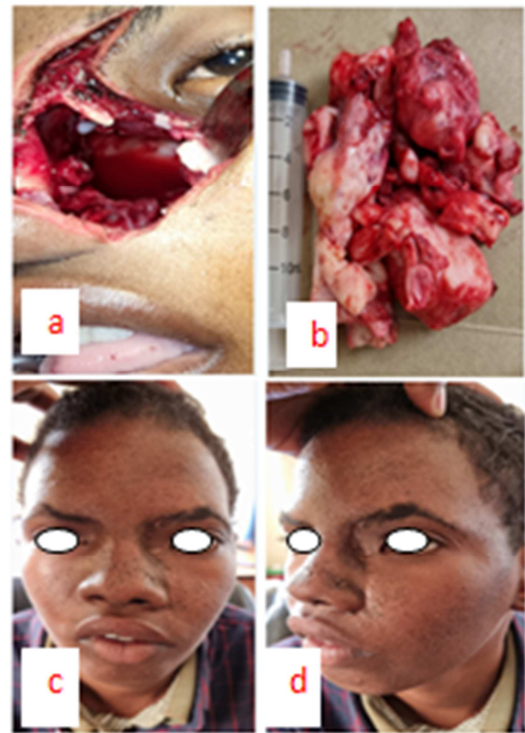
hamartomatous malformation rather than a neoplastic disease [1, 4]. Solitary location in the naso-sinus cavities is rare, estimated at 4% of locations in the head and neck [1]. This epidemiological rarity is increased by diagnostic difficulties. Large series are almost absent from the literature. The success of surgical treatment depends on an early diagnosis before the nerve fibers are damaged by compression [5]. The objective of this work was to report a case of solitary nasosinus neurofibroma in order to discuss diagnostic and therapeutic difficulties in a developing country.

## 2. Observation

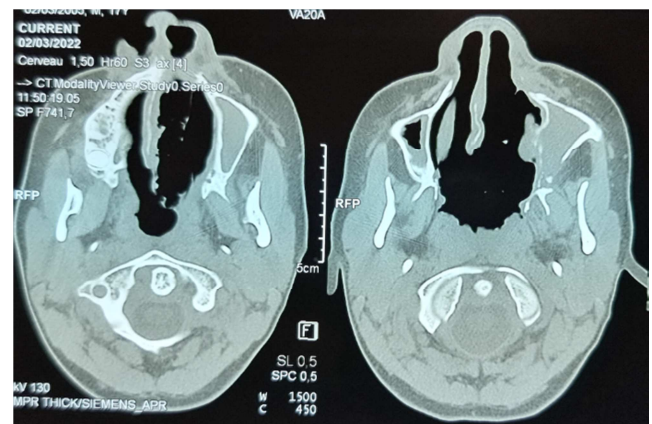
BA aged 17, with no known pathological history, was admitted to the service for a left nasal obstruction which had been evolving for about 4 years. It started gradually and continued to develop, then extended to the contralateral nasal cavity. The obstruction was associated with mucopurulent rhinorrhea, facial pain, and episodes of epistaxis. 2 months before the consultation, an ipsilateral unilateral proptosis was associated. The endonasal examination found a congestive mass, not bleeding on contact, filling the entire left nasal fossa pushing back the nasal septum on the right. The endobuccal examination objectified an upper left vestibular filling and a slight palatal curvature with healthy looking mucosa. There was no mobility or abnormal dental sensitivity. On ophthalmological examination, there was significant proptosis and limited abduction of the left eye. Elsewhere there was no particular “café au lait” skin lesion, palpable adenopathy or nerve abnormality. Computed tomography showed a heterogeneous dense tissue process with cystic areas, filling the left nasal fossa with extension to the posterior sinuses, left maxilla. It bulged the medial wall of the left orbit causing grade III proptosis, measuring 80x72x64 mm. In view of these clinical and radiological data, a malignant tumor process was strongly suspected. An endonasal biopsy showed signs of chronic inflammation. Given the inconclusive result of the biopsy, we opted for a direct approach to the tumour. The patient was operated under general anesthesia via the left paralateronasal route. The tumor was difficult to cleave but not friable and not bleeding. The histological examination concludes to a connective tissue tumor with a proliferation of regular spindle cells with wavy nuclei associated with collagen fibers. The whole produced a fasciculate architecture with myxoid zones, an aspect very evocative of neurofibroma. With a follow-up of 8 months, the patient shows no endoscopic or radiological signs of recurrence.



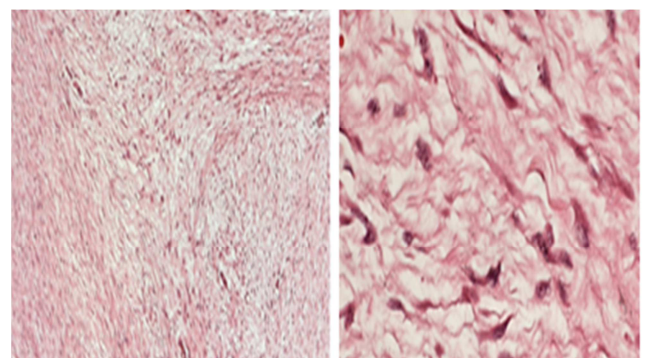
**Figure 1.** Heterogeneous dense tissue process with cystic areas, filling the pit left nasal with sinus extension posteriors, left maxilla. It bulged the medial wall of the left orbit causing grade III proptosis, measuring 80x72x64mm.



**Figure 2.** a) Intraoperative image; b) Image of the operating piece; c and d) Images of the patient 8 months after the operation.



**Figure 3.** CT Aspects Postoperative at 8 months. Axial section: voids nasosinus cavities and cavum. Presence of bilateral residual maxillary sinusitis.



**Figure 4.** Histopathological and immunohistochemical images Immuno-expression of the S-100 protein by neoplastic cells. Magnification x 100 and 400.

### 3. Discussion

We noted, in agreement with the literature that the neurofibroma of the nasosinusal cavities is a rare entity of nerve tumors of the head and the neck. Of the 900 hundred anatomopathological results of the last ten years of the service, this is the only case noted, i.e. 0.011% of the cases. Neurofibromas are benign, slow growing, and relatively circumscribed but not encapsulated peripheral to the nerve sheath arising from non-myelinating Schwann cells [5]. Involvement of the nasosinusal cavities is rare and found in 4% of cases [6]. The neurofibroma would develop from the 1st and 2nd dividing branches of the trigeminal nerve destined for different structures of the naso-sinus cavities, in particular the septum, the turbinates, the maxillary sinus. It belongs to a vast entity including schwannomas and neurogenic sarcomas. All these lesions come from Schwann and perineural cells derived from neuroectodermal tissue [1, 7, 8].

In the literature, the majority of cases have been reported in subjects between the 3rd and 6th decades and in women [1, 8, 9]. As for the age and sex of our clinical case, he was young, 17 years old and male with no other associated history.

Signs and symptoms depend on the anatomical site involved, the nerve of origin and the extent of the tumor. The signs are usually those of a tumor developing in the nasosinus cavities [10, 11]. One can find, among other things, mucopurulent rhinorrhea, nasal obstruction, epistaxis, anosmia, facial deformity, proptosis and facial pain. In our case, the symptomatology was rich due to the volume and the locoregional extension of the mass.

Our case appeared on computed tomography as reported in the literature as an irregular mass with images of bone lysis despite the benignity of the tumor. This aspect suggests a priori a malignant tumor. This testifies to the diagnostic difficulties [10]. Nuclear magnetic resonance imaging with gadolinium injection shows heterogeneous contrast enhancement that is suggestive of neurofibromas [11].

MRI with gadolinium contrast is indicated in areas with intraorbital or intracranial extension, and for more exact delineation of the tumor from the normal soft tissues. Furthermore, MRI is helpful in differentiating the neoplasm from retained secretions or inflammatory changes within the sinuses and nasal cavity [12]. In our context, the only MRI center available in the country remains too expensive and often breaks down. In our case, we did not have access.

In the literature the positive diagnosis is histological thanks to the characteristic findings of spindle cells with wavy nuclei, wavy collagen fibrils and scattered mast cells. In most cases, the pathologist will not experience difficulty in making the diagnosis of a neurofibroma or a benign schwannoma because these tumors do have a distinctive histologic appearance. Some problems may be encountered, however in differentiating between these two lesions, especially in small biopsy or curettage specimens.

Schwannomas have a capsule, neurofibromas generally do not. The myxoid changes as well as the highly cellular areas found in schwannomas may occur also in neurofibromas, although nuclear palisading usually is not a prominent feature in neurofibromas. Thus, these two neoplasms do exhibit overlapping histologic features. Since malignant change may develop in neurofibromas but not in schwannomas, the pathologist should attempt to differentiate between these tumors. In nose and paranasal sinuses [12]. In general, the differential diagnosis of neurofibroma of the nasosinusal tract must be made in order of frequency with schwannomas, protuberant dermatofibrosarcomas, fibrosarcomas, meningiomas, leiomyomas, solitary fibrous tumors, leiomyosarcomas [6]. Only immunohistochemistry is useful in this respect to avoid diagnostic errors. Positive immunoreactivity with S-100, NSE and vimentin confirms the diagnosis of neurofibroma [8, 12, 13].

Therapeutically, complete surgical excision is the treatment of choice [14, 15]. In this, we performed a total excision of the mass via the paralateronasal route, even if the current trend in the literature is surgical resection via the endonasal route. Recurrence is possible even if its frequency remains low and malignant transformation is rare [6, 14]. Indeed, only a few cases of malignant degeneration have been described in the literature [10, 14].

### 4. Conclusion

Solitary neurofibromas are uncommon and remain poorly understood. Literature data, rare, do not answer all the questions. This clinical case confirms the non-specific clinical and radiological characteristics of nasosinusal neurofibroma. Only positivity at the PS100 is contributory. It is therefore a diagnosis to be considered in the presence of any tumor with nasal sinus development. Monitoring must be regular and appropriate.

### Conflicts of Interest

All the authors do not have any possible conflicts of interest.

### References

- [1] A. Tall, C. N'diaye, E. S. Dioma, I. Thiamb. Neurofibrome solitaire à point de départ septal postérieur: exérèse par voie endoscopique endonasale. *Annales françaises d'oto-rhino-laryngologie et de pathologie cervico-faciale*. 2015; 132: 210-212.
- [2] H. J. Min, K. S. Kim / *Annales françaises d'oto-rhino-laryngologie et de pathologie cervico-faciale*. 2017; 134: 266-268.
- [3] Rameh C, Hussein S, Tawil A, et al. Solitary plexiform neurofibroma of the nasaltip: case report and review of the literature. *Int J Pediatr Otorhinolaryngol Extra*. 2007; 2: 116-9.

- [4] Khorgami Z, Nasiri S, Rezakhanlu F, et al. Malignant Schwannoma of anteriorabdominal wall: report of a case. *J Clin Med Res*. 2009; 1: 233-6.
- [5] Ndiaye M. M, Diop R, Zegbe N, Toure S, Crezoit Ge. *Revue Africaine et Malgache pour la Recherche Scientifique / Sciences de la Santé*. 2020; 2 (2): 62-66.
- [6] Darren Yap, Hannah Fox, and Julia Addams-Williams. Unusual Case of a Proptosed Eye: Isolated Right Maxillary Neurofibroma. *Case Reports in Pathology*. 2016, Article ID 4294729, 5 pages. <http://dx.doi.org/10.1155/2016/4294729>
- [7] M. D. Prakash, B. Viswanatha, and G. E. D'Souza, "A rare case of isolated nasal neurofibroma mimicking sinonasal polyp, *Research in Otolaryngology*, 2014; 3 (3): 49-51.
- [8] C. Adnane, T. Adouly, L. Elhani, and M. Mahtar, "Solitary neurofibroma ofmaxillary sinus a rare case report, *Journal of Head & Neck Physicians and Surgeons*, 2014; 2 (2): 136-141.
- [9] Kohli PS, Goel K. Endoscopic excision of solitary neurofibroma arising fromposterior nasal septum. *Clin Rhinol Int J* 2011; 4 (1): 43-6.
- [10] E. E. M. Nao, A. Tall, M. Ndiaye, C. Ndiaye, M. S. Diouf, A. Thiam, A. B. Djafarou, B. K. Diallo, I. C. Ndiaye, R. Diouf, E. M. Diop. Neurofibrome isolé du sinus maxillaire. *Annales d'oto-laryngologie et chirurgie cervico-faciale* 2009; 126: 256-258.
- [11] Józef Komorski, Łukasz Petz, Jan Nienartowicz, Łukasz Pałka. Neurofibroma of sinus maxillae. *otolaryngologia polska* 2014; 68: 94 -98.
- [12] Parvinderjit Singh Kohli, Kanu Goel. Endoscopic Excision of Solitary Neurofibroma Arising from Posterior Nasal Septum *Clinical Rhinology: An International Journal*, January-April 2011; 4 (1): 43-46.
- [13] Mylanahalli Doddarangiah Prakash, Borlingegowda Viswanatha, Glen Edwin D'Souza. A Rare Case of Isolated Nasal Neurofibroma Mimicking Sinonasal Polyp. *Research in Otolaryngology* 2014, 3 (3): 49-51 DOI: 10.5923/j.otolaryn.20140303.04.
- [14] Sudhir B. Sharma and Paul Hong. Solitary Neurofibroma of the Frontal Sinus. *Case Reports in Otolaryngology Volume* 2012, Article ID 373808, 4 pages doi: 10.1155/2012/373808.
- [15] Marina R. P. da Rosa, DDS, Andre Luis Ribeiro Ribeiro, DDS, MSc, Silvio A. F. de Menezes, DDS, MSc, Solitary Giant Neurofibroma of the Mental Nerve: A Trauma-Related Lesion? *The Journal of Craniofacial Surgery* 2013; 24 (3): 247-51.