

A Case Report of a *Microsporum gypseum* Tinea Capitis Diagnosed at the Laboratory of Parasitology-mycology of the Avicenne Military Hospital of Marrakech

Ilham Karrati, Ghita Elghouat, Mohamed Diakité, Fayrouz Debbagh, Mustapha Elmezouari, Redouane Moutaj

Department of Parasitology-mycology, Avicenne Military Hospital of Marrakech, Marrakesh, Morocco

Email address:

ilhamkarrati@gmail.com (I. Karrati)

To cite this article:

Ilham Karrati, Ghita Elghouat, Mohamed Diakité, Fayrouz Debbagh, Mustapha Elmezouari, Redouane Moutaj. A Case Report of a *Microsporum gypseum* Tinea Capitis Diagnosed at the Laboratory of Parasitology-mycology of the Avicenne Military Hospital of Marrakech. *International Journal of Infectious Diseases and Therapy*. Vol. 7, No. 1, 2022, pp. 13-16. doi: 10.11648/j.ijidt.20220701.13

Received: February 1, 2022; Accepted: February 21, 2022; Published: March 9, 2022

Abstract: Historically, tinea capitis has been a problem among the population in general and in Morocco in particular. It is still a significant reason for consultation in routine medical practice, particularly among the population living in poor hygienic conditions. It is an infection almost exclusively of preschool and school-age children, due to changes in sebaceous secretion and skin pH during puberty, affecting both sexes, with a female predominance. Inflammatory cases or Kerion are caused by zoophilic species such as *Trichophyton mentagrophytes*, *Trichophyton verrucosum*, *Microsporum canis*, and less frequently by *Microsporum gypseum*. The identification of the species makes it possible to pinpoint the source of contamination and to condition the prophylaxis. Aware of the rarity of inflammatory tinea capitis caused by *M. gypseum*, we thought it would be interesting to report a new case diagnosed in the Parasitology-Mycology laboratory of the Avicenne Military Hospital in Marrakech, while focusing on the epidemiological, clinical and mycological characteristics of this dermatophyte through a review of the literature.

Keywords: Tinea Capitis, *Microsporum gypseum*, Marrakech, Morocco

1. Introduction

Tinea capitis is the most common fungal infection in children. They are caused by keratinophilic filamentous fungi of the genus *Trichophyton* and/or *Microsporum*, of anthropophilic, zoophilic and geophilic types [2]. *Microsporum gypseum* (*M. gypseum*) is a very rare etiology. For this reason, it seemed appropriate to report the case of an 8 year old boy who consulted us for inflammatory tinea capitis and from whom a strain of *M. gypseum* was isolated by culture in the Parasitology-Mycology laboratory of the Avicenne Military Hospital in Marrakech.

2. Observation

The case in question refers to an 8-year-old boy, with no particular pathological history, who presented to a dermatology consultation for an abscessed scalp lesion that

had appeared for 21 days, treated with amoxicillin-clavulanic acid and fucidin for 10 days but without clinical improvement. The history did not reveal the presence of pets or similar cases in the surroundings. However, the notion of scalp trauma with telluric contact was revealed. Clinical examination revealed an erythematous squamous plaque measuring 4*3.5 cm, raised by a suppurated macaroon relief with pus discharge (Figure 1), without fever or satellite adenopathies, without associated cutaneous or nail involvement, and the wood's light examination was negative.

Direct microscopic examination of hair taken between slide and coverslip after lightening with 10% potash showed ecto-endothrix type hair parasitism. Culture on Sabouraud's media with added chloramphenicol and cycloheximide revealed, within five days, the growth of colonies with a powdery centre and downy peripheral extensions, light buff to beige in colour on both sides (Figures 2-3). Microscopic study of a colony sample revealed hyaline, septate and

regular mycelial filaments of moderate abundance, rare microconidia with numerous spindle-shaped or elliptical macroconidia, more or less thick-walled, with transverse partitions determining a maximum of 6 logettes reminiscent of *M. gypseum* (Figure 4). These cultural characteristics were the basis for the identification of a strain of *M. gypseum*.

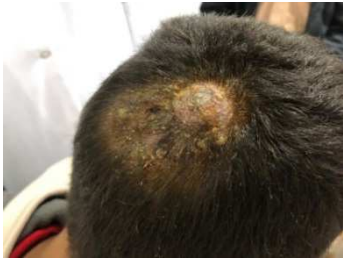

Figure 1. Inflammatory moth raised in macaron with pus output.



Figure 2. Culture in tube: plastery colonies of café au lait color.

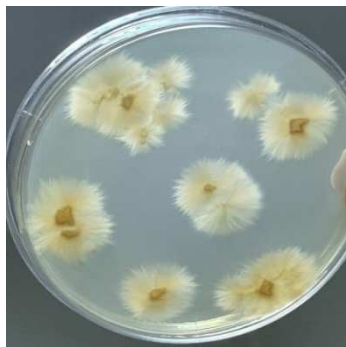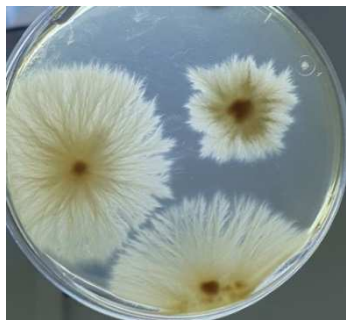


Figure 3. Petri dish culture: star-shaped fluffy appearance with a slightly protruding powdery center.

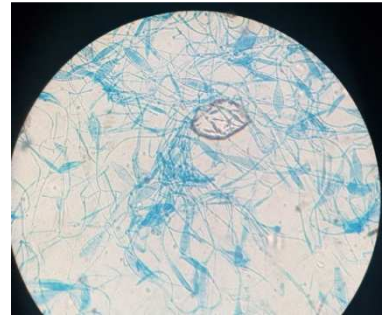


Figure 4. Spindle-shaped Macroconidia, with thin walls, with partitions determining 4 to 6 logettes.

3. Discussion

Tinea capitis involving *M. gypseum* are still rarely reported today. In Morocco, a recent consultation of mycology case registers over a period of 7 years between 2003 and 2009 revealed that *M. gypseum* is the cause of 0.3% of scalp ringworms [3]. Similarly, a retrospective study carried out over 3 years (2014-2016) at the University Hospital of Casablanca reported a single case out of 70 cases of TCC [4]. This epidemiological profile is shared by a large number of African, European, Asian and American countries where the frequency of scalp parasitism by this dermatophyte is between 0.1 and 4.5%, notably in Benin, Tunisia, Spain, China, Japan, Mexico and Brazil [2, 5-11].

Tinea capitis remains the most common fungal infection in children before puberty. It is still a public health problem in developing countries. It remains relatively frequent in Morocco where it has been the subject of several studies revealing quite variable frequencies ranging from 6.27 to 19.64% [12]. The various publications consulted on *M. gypseum* ringworm unanimously report cases diagnosed in a paediatric population aged between 1.5 and 13 years, as in the case of our 8 year old child, which strongly supports this observation.

M. gypseum is a cosmopolitan telluric dermatophyte with an established pathogenicity; the spores contained in the soil pass into the stratum corneum of the epidermis through a pre-existing skin lesion, and then grow into centrifugal filaments that form a circular lesion, with the active zone at the periphery [13].

Dermatophytosis caused by *M. gypseum* usually manifests as an inflammatory mycosis that usually affects the hairless skin and scalp, especially in children. Very rarely, it may present as onychomycosis [11]. The hair is affected from the stratum corneum of the epidermis, resulting in suppurated ringworms or kerions, which manifest as round placards several centimetres in diameter, usually isolated, inflammatory and raised; thus the pus formed at the follicular ostium of the affected hair causes both the fungus and the hair to be expelled, leaving a patch of alopecia in 7 to 10 days. This lesion is painful and may be accompanied by satellite adenopathy [11-13]. The dermatophytes involved in inflammatory processes (kerion, sycosis) are often zoophilic and not well adapted to human parasitism (*T. mentagrophytes*: pets, *T. verrucosum*:

cattle). Dermatophyte telluric infections are more anecdotal, but possible (*M. gypseum*). In our patient, the classical risk factors for dermatophytic disease were not present, however, a pre-existing scalp lesion with telluric contact was noted, which favoured the development of kerion [13].

Examination of the scalp with a Wood's lamp to look for the presence or absence of green fluorescence is essential and is negative in *M. gypseum* kerion, unlike *M. canis* lesions. The sample must be taken without any local therapy. The pathological hair is pulled out with tweezers, the pus is swabbed, and the scales are removed with a Brocq curette. Direct examination in 30% potassium under a light microscope is an essential step in the biological diagnosis of ringworm; on the one hand, it confirms the presence of the fungus in a parasitic state within the sampled area, and on the other hand, it allows the prescribing physician to obtain an initial result justifying the rapid implementation of specific treatment. In the case of *M. gypseum* ringworm, the type of hair parasitism varies: endothrix with large spores (4 µm) occupying the entire interior of the hair or ecto-endothrix of the megaspore type, with the presence of mycelial filaments inside the hair and large spores outside [13, 14], which can lead to confusion with inflammatory ringworm with *Trichophyton verrucosum*.

The culture of the samples is an essential step for the diagnosis of the species. As for *M. gypseum*, the growth period is rapid, i.e. five to six days, the colony reaches a diameter of 10 to 15 cm in a few days, it is plastery and coffee-coloured. The centre is slightly protruding, with discrete rays extending to the periphery. A white down sometimes appears on certain sectors indicating the birth of the pleomorphism. The underside of the colony is ochre. The powdery appearance is due to the presence of numerous macroconidia as shown by microscopic examination. In addition, ovoid microconidia are present, but in smaller proportions. The macroconidia are in the form of spindles of 10 to 15 µ X 30 to 50 µ, with a maximum of four to six logettes. Their walls are not very thick. The distal end is blunt. Microconidia are more rarely seen and seem to be more frequent in the downy parts. They are ovoid, about 3 µ X 5 µ, and have a sessile truncate base. Unlike macroconidia, they are easily detached from the filaments that carry them [15].

The biological diagnosis of dermatophytosis with the mycological identification of the fungus involved is of crucial interest, it allows to confirm not only the pathogenic character of the fungus but also to specify the origin of the contamination and thus to prevent a possible recurrence. In the case of ringworm, the study of the hair parasitism already provides precious and rapid information to the practitioner who can then start treatment without delay. In the case of suspected anthropophilic ringworm in a child (therefore a priori contagious), a school ban should be proposed until the antifungal treatment is implemented. For ringworm of animal or telluric origin, which is practically non-transmissible from human to human, school exclusion is unnecessary, a certificate of non-contagiousness can be proposed. If in doubt, the results of the culture should be awaited [14, 15].

4. Conclusion

The case of suppurative tinea reported in this work is a presentation of dermatophytic pathology, very different from the classical appearance of non-inflammatory Tinea capitis, which may be mistaken for a pyogenic bacterial abscess, highlighting the presence of an important correlation between the origin of the fungi incriminated in tinea and the intensity of the clinical manifestations. In general, zoophilic and geophilic dermatophytes give inflammatory reactions (kerion and folliculitis) whereas lesions due to anthropophilic dermatophytes result in discrete alopecia lesions.

Biological diagnosis of tinea capitis is essential before treatment can be started; direct examination of the hair confirms the diagnosis and culture remains an essential complement, insofar as it allows the causal agent to be identified, the source of infection to be determined and, consequently, the measures to be taken to prevent and control the dermatophytic infection.

References

- [1] H. Tligui et coll Profil actuel des teignes du cuir chevelu à Rabat Maroc Médical, tome 22 n°2, juin 2000.
- [2] Itzel A Flores Reyes et al Kerion celsi caused by *microsporum gypseum*: report of two cases and review J Dermat Cosmetol. 2018; 2 (3): 151-157.
- [3] A Romli, A Agoumi, H Tligui Trichophyton rubrum et teigne du cuir chevelu Maroc Médical, tome 32 n°2, juin 2010.
- [4] Rajae Abid Profil épidémiologique des teignes du cuir chevelu au CHU Ibn Rochd de Casablanca Journal de Mycologie Médicale Volume 27, n° 3 page e38 (septembre 2017).
- [5] Koudoukpo et al Profil mycologique des teignes du cuir chevelu en milieu scolaire à Parakou (Bénin 2018) Health Sci. Dis: Vol 20 (4) July – August 2019.
- [6] A. Kallel et al Les teignes du cuir chevelu en Tunisie: problème toujours d'actualité Journal de Mycologie Médicale Volume 26, Issue 2, June 2016, Page e34.
- [7] García-Agudo L. Espinosa-Ruiz JL. Tiña capitis por *Microsporum gypseum*, una especie infrecuente. Arch Argent Pediatr 2018; 116 (2): e296-e299.
- [8] Zhang et al. A case of kerion celsi caused by *Microsporum gypseum* in a boy following dermatoplasty for a scalp wound from a road accident Medical Mycology January 2011, 49, 90–93.
- [9] Mari Iwasawa et al A case of kerion celsi caused by *Microsporum gypseum* (*Arthroderma gypseum*) in a child Jpn. J. Med. Mycol, Vol. 50, 155-160, 2009 ISSN 0916- 4804.
- [10] Torres-Guerrero E, Martínez-Herrera E, Arroyo-Camarena S, Porras Kerion Celsi: A report of two cases due to *Microsporum gypseum* and *Trichophyton tonsurans*. Our Dermatol Online. 2015; 6 (4): 424-427.
- [11] Souza BS, Sartori DS, Andrade C, Weisheimer E, Kiszewski AE. Dermatophytosis caused by *Microsporum gypseum* in infants: report of four cases and review of the literature. An Bras Dermatol. 2016; 91 (6): 823-5.

- [12] El Mezouari et al. Teignes du cuir chevelu à l'hôpital militaire Avicenne de Marrakech (Maroc): bilan de 8 ans (2006—2013). Journal De Mycologie Médicale (2016) <http://dx.doi.org/10.1016/j.mycmed.2015.11.005>.
- [13] Kerion Celsi Caused by *Microsporum gypseum* The Journal of pediatrics, Medecine Tropicale, www.jpeds.com.
- [14] Dominique Chabasse, Claude Guiguen Dermatophytes: difficultés d'interprétation et pièges du diagnostic mycologique Revue francophone des laboratoires N° 510 MARS 2019.
- [15] G. Percebois et al Considérations à propos de l'isolement de *Microsporum gypseum* du sol, en Lorraine: Fréquence de ce Dermatophyte Annales de Parasitologie (Paris) t. 40, 1965, n° 3, pp. 371 a 382.