

Lingual Frenectomy in a Pediatric Patient: A Case Report

Daniela Chavez^{1,*}, Paul Pena², Constanza Sanchez¹, Ximena Navarrete¹

¹Department of Pediatric Dentistry, Dentistry Faculty, San Francisco University, Quito, Ecuador

²Department of Maxillofacial Surgery, Dentistry Faculty, San Francisco University, Quito, Ecuador

Email address:

danielchao@hotmail.com (D. Chavez)

*Corresponding author

To cite this article:

Daniela Chavez, Paul Pena, Constanza Sanchez, Ximena Navarrete. Lingual Frenectomy in a Pediatric Patient: A Case Report. *International Journal of Dental Medicine*. Vol. 8, No. 1, 2022, pp. 1-4. doi: 10.11648/j.ijdm.20220801.11

Received: October 8, 2021; **Accepted:** November 11, 2021; **Published:** March 23, 2022

Abstract: Ankyloglossia, commonly known as tongue-tie, is a congenital developmental anomaly caused by a short, thickened, or abnormally tight lingual frenulum that impedes the full protrusion and elevation of the tip of the tongue. Patients suffering this condition would present a range of symptoms as affected phonetic function, atypical swallowing, as well as malocclusion problems, gingival recession, mechanical problems such as inability to clean the oral cavity, social implications, lactation difficulties among others. Their effect on oral motor function have become themes of interest within health care professional. However, there is no consensus on the ideal treatment in each case. Thus, there are different surgical procedures to treat this pathology. Therefore, this report presents one of the treatment options in the case of moderate ankyloglossia. This article is a case study of incomplete tongue-tie in an 8-year-old pediatric patient, who presented problems in verbal articulation. The child received speech therapy at school, which resulted unsuccessful and derived in search for a solution through dental care. The diagnosis was ankyloglossia, and the cure procedure was a frenectomy by means of rhomboid technique. Conclusion: The surgical intervention using the technique of rhomboid lingual frenectomy reestablished a greater tongue mobility. The patient showed improvement in verbal articulation after a 12th month medical control.

Keywords: Ankyloglossia, Rhomboid Technique, Lingual Frenulum, Frenectomy

1. Introduction

This paper presents a case of a pediatric patient with Ankyloglossia, and the application of the rhomboid frenuloplasty technique, with follow-up at 12 months.

The lingual frenulum is an element that is located on the underside of the tongue. Depending upon the tissue constitution, the frenulum can be one of three types: 1. Fibrous frenulum 2. Muscular frenulum 3. Mixed or fibromuscular frenulum. Anatomical disorders appear when the frenulum is too short and hinders full mobility protrusion of the tip of the tongue. This condition is called ankyloglossia [1-3] and ranges in severity from mild obstruction to a full tongue mobility impediment, when the tongue may be fused to the floor of the mouth [4]. Ankyloglossia is of congenital nature, which could result from a mutation in the T gene box or appear in unborn children, when exposed to teratogenic substances during pregnancy [5]. Ankyloglossia cases are more frequent in men than in women [3].

When this pathology exists, and depending on the severity of the case, the signs are a visible hypertrophic lingual frenulum, and a reduced mobility of the tongue [2, 6, 7]. Therefore, implications such as difficulty in breastfeeding may happen, problems in verbal articulation can occur, among others [8, 9]. Verbal articulation is an obstructed enunciation clear, as the phonetic function is hindered and is especially noticeable the sounds with the letters t, d, n l, s, r, z. Further disorders resulted in atypical swallowing and incorrect support of the tongue, as ankyloglossia hinders the tongue from resting at the roof of the mouth [2]. Untreated or advanced cases of ankyloglossia also cause dental problems, as abnormal development of the mandible [2, 3, 7]. Typical subjects present a narrowing of the maxillary due to the lack of transverse growth, which causes cross bites to occur. In other cases, ankyloglossia can also present anterior open bite or both, because of the low position of the tongue. Several severe cases have presented a short and hypertrophic lingual frenulum, which can cause diastemas between the lower

central incisors or even a bilateral open bite. This phenomenon is correlated to an excessive work of the tongue needed to carry out its usual functions [2].

In the cases mentioned, excision of the lingual frenulum is the preferred procedure [5]. Which can be treated with total excision through one of the following techniques: Z-frenuloplasty, V-Y frenuloplasty, or rhomboid frenuloplasty as in this case study.

2. Clinical Case

The subject is an 8-year-old male patient, who was intervened in the dental clinic of the Universidad San Francisco de Quito, Ecuador. His intervention needed the full consent of his parents according to local regulations. The first entries in the subject's medical record describe his best traits as a cooperative and open behavior. Due to problems in pronunciation, the subject received speech therapy at school, but the treatment showed no improvement. The tutors linked the problem to a deficient tongue mobility and recommended to continue the treatment through dental assessment.

The full diagnosis after an intraoral clinical examination were ankyloglossia of lingual frenulum in a kotlow II category (moderate). The frenulum measured 10 mm. (Figure 5). In addition, the patient presented carious lesions on tooth pieces # 7.4, 7.5, 8.3, 8.4, 8.5. Also, tooth pieces # 7.5, 8.4, 8.5 had pulp involvement (Figure 2). Makeover, the patient presented deep grooves in pieces # 16, 26, 36, 46 (Figure 1).

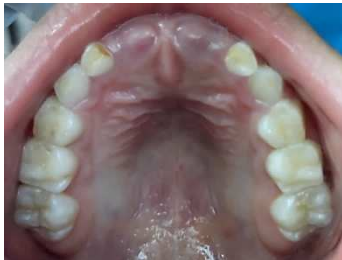

Figure 1. Maxillary occlusal view.

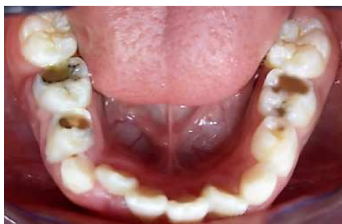

Figure 2. Mandibular occlusal view.

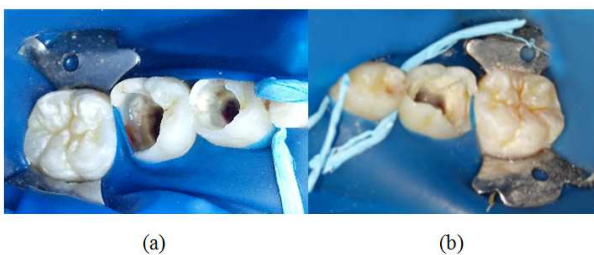

Figure 3. Pulpectomy treatments of (a) 74, 75 and (b) 85.

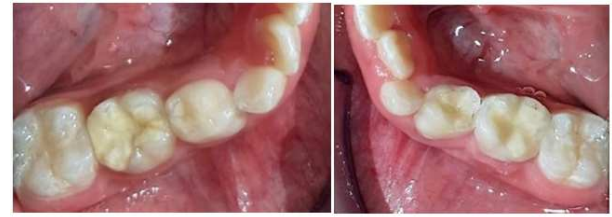

Figure 4. Restoration of (a) 74, 75, (b) 84, 85.

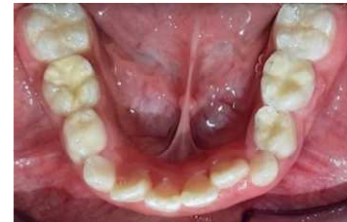

Figure 5. Lingual frenulum with kotlow's class II.

3. Procedure

The procedure was carried out in three stages. The preventive, restorative and surgical phase. Within the preventive phase, prophylaxis, placement of sealants on teeth # 16, 26, 36, 46 and placement of fluoride varnish were performed. Followed by the restorative phase, the pulp treatments and the restoration on teeth 7.4, 7.5, 8.3, 8.4, 8.5 were carried out (figures 3, 4). At a subsequent appointment, within the surgical phase, rhomboid frenuloplasty were performed at as follows:

Infiltrative local anesthesia was placed, using 2% lidocaine + 1: 80,000 epinephrine, infiltration was performed bilaterally to the frenulum and throughout its course, anesthesia was also placed on the tip of the tongue (Figure 6). Transfixation with 3-0 braided silk was performed on the tip of the tongue, thus avoiding mobilization of the tongue and allowing adequate visualization of the frenulum (Figure 7). The lingual frenulum was grasped with two mosquito forceps, both forceps were found in the depth of the frenulum. The lower forceps were used to protect the Wharton's duct, around the upper mosquito forceps, two incisions were made following the contour of the forceps in the upper and lower part, for this a handle No. 3 scalpel with a blade N ° 15 was used. (Figure 8). Thus, the frenulum was removed, obtaining a rhomboid shape (Figure 9). Next, additional debridement of the fibers was performed, later simple sutures were performed with resorbable vicryl thread (Figure 10). Subsequent, hemostasis was performed in the area, and a soft diet was indicated. In addition, it was recommended that 15 days after surgery the patient perform exercises at home, like: place the tongue towards the palate, stick the tongue outwards and squeeze an object with the tongue, this was recommended to repeat 10 times each one, 3 times a day. Likewise, it was recommended to continue with speech therapy. Finally, patient controls were carried out at 15 days, a month and 12 months later (due to the limited

availability of time of the patient). In his last control, satisfactory results were observed in the mobility of the tongue, as well as in the restoration of the phonation function.

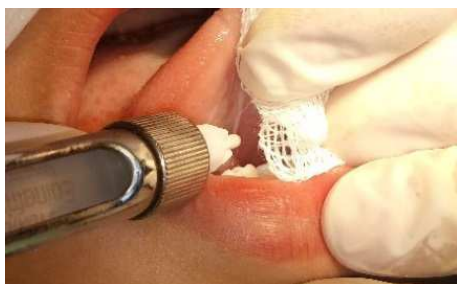

Figure 6. Lingual frenulum with kotlow's class II.

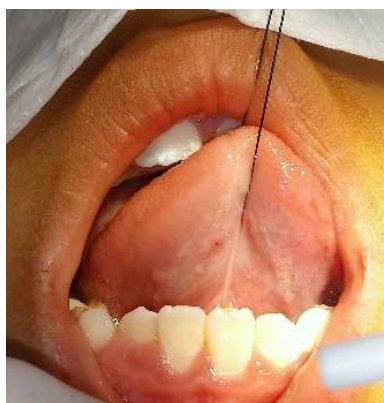


Figure 7. Lingual transfixing.

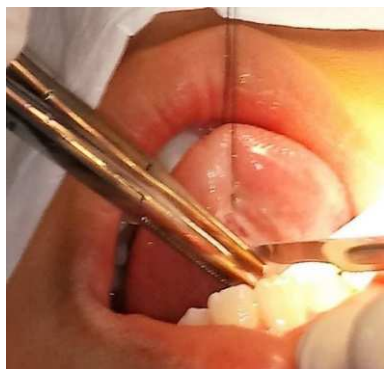

Figure 8. Hold the frenulum with two mosquito forceps and section the frenulum with a scalpel.

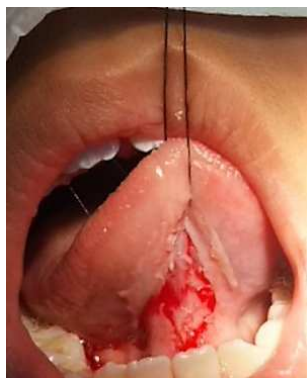

Figure 9. Lingual Frenuloplasty.

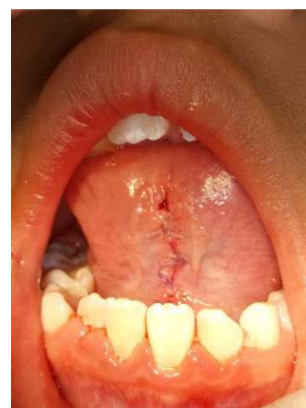

Figure 10. Suture.

4. Discussion

There is a controversy regarding the diagnosis and treatment of tongue-tie. It is important consider parameters such as: length, thickness of the lingual frenulum, and mobility of the tongue [8-11]. In this case study, the patient presented a short and thick frenulum, which did not allow adequate phonation.

It is necessary for the patient to receive speech therapy. If the therapy does not give satisfactory results, the oral cavity should be evaluated to verify the presence of ankyloglossia, and if required, perform surgical treatment [12]. There are different treatments such as rhomboid frenuloplasty, Z frenuloplasty, laser frenectomy, etc. These treatments can be performed in children and adults, and it is recommended to continue with speech therapy after surgical treatment [12, 13]. Thus, in this case it was also recommended to continue with post-surgical speech therapy.

In a case report of 2 patients aged 13 and 15 years, rhomboid frenuloplasty was performed, and it showed satisfactory results, although the author mentions that it is an invasive technique and difficult to perform in children; however, it has a low probability of recurrence [13]. In this case, the patient presented a collaborative behavior in all appointments prior to surgical treatment, so it was decided to perform the rhomboid technique, despite its difficulty. Taking into account that this technique according to the literature prevents the recurrence of the pathology.

Ideally, it is suggested to carry out this treatment at an early age, from birth, in this way the treatment is less invasive, with low risk [13-16]. It only requires the release of the frenulum with a small incision of 3 to 5 mm, which restores the mobility of the tongue. In this way, helping the child to feed properly [17-21], and in later ages the patient can even articulate words well and develop the maxilla and mandible in a better way [2]. Although, in this case study the patient could not access treatment dentistry at an early age due to the mother's inexperience about oral health. However, at 8 years old, as soon as the pathology was identified, it was determined necessary to carry out treatment immediately. Therefore, early treatment of this pathology by the multidisciplinary team is important, in which the pediatric

dentist, speech pathologist, speech therapist and surgeon can intervene.

5. Conclusion and Recommendation

The case study showed an abnormal insertion of the patient's tongue, which altered its mobility and restrained normal verbal articulation. Through surgical removal of the lingual frenulum, applying the rhomboid surgical technique to avoid recurrence. Through this procedure and with continuous language therapy, the mobility of the tongue was reestablished, and at the 12-month follow-up an adequate articulation of the words could be seen. Therefore, the importance of the intervention of the multidisciplinary team is emphasized.

Since, there is no current agreement on treatment between multidisciplinary health personnel such as: otorhinolaryngologists, speech therapists, general practitioners, pediatric dentists, surgeons; more studies and research should be published on the surgical treatments field, which have been performed in patients with ankyloglossia, in order to be able to create a standard protocol for treating these cases.

It is recommended to file descriptions of the techniques used, as well as the follow-up of the patients. Therefore, more information can be gathered to offer a wide and complete treatment in this field.

References

- [1] Gay Escoda, C., Berini, L. (1999). *Cirugía Bucal*. Ed Ergon. Madrid, 577-574.
- [2] Jamilian, A., Fattahi, FH., kootan, NG. (2014). *Ankyloglossia and tongue mobility*. European Archives of Paediatric Dentistry (Springer Science & Business Media B. V.). 1 (15): 33–35.
- [3] Ferrés-Amat, E., Pastor-Vera, T., Ferrés-Amat, E., Mareque-Bueno, J., Prats-Armengol, J., & Ferrés-Padró, E. (2016). Multidisciplinary management of ankyloglossia in childhood. Treatment of 101 cases. A protocol. *Medicina oral, patología oral y cirugía bucal*, 21 (1),
- [4] Gandevivala A. (2005). *Surgical correction of ankyloglossia with four-flap*. *Oral Surgery*. 54 (6): 38–40.
- [5] Tsaousoglou, P., Topouzelis, N., Vouros, I., & Sculean, A. (2016). Diagnosis and treatment of ankyloglossia: A narrative review and a report of three cases. *Quintessence international (Berlin, Germany: 1985)*, 47 (6), 523–534.
- [6] Bhowmik A. (2016). Tongue Tie/Ankyloglossia. *International Journal of Clinical & Medical Imaging*. 03 (10).
- [7] American Academy of Pediatric Dentistry. Policy on management of the frenulum in pediatric dental patients. The Reference Manual of Pediatric Dentistry. Chicago, Ill.: American Academy of Pediatric Dentistry; 2020: 74-8.
- [8] Messner, A. H., Walsh, J., Rosenfeld, R. M., Schwartz, S. R., Ishman, S. L., Baldassari, C., Brietzke, S. E., Darrow, D. H., Goldstein, N., Levi, J., Meyer, A. K., Parikh, S., Simons, J. P., Wohl, D. L., Lambie, E., & Satterfield, L. (2020). Clinical Consensus Statement: Ankyloglossia in Children. *Otolaryngology--head and neck surgery: official journal of American Academy of Otolaryngology-Head and Neck Surgery*, 162 (5), 597–611.
- [9] Francis, D. O., Krishnaswami, S., & McPheeters, M. (2015). Treatment of ankyloglossia and breastfeeding outcomes: a systematic review. *Pediatrics*, 135 (6), e1458–e1466.
- [10] Kotlow LA. (1999). Ankyloglossia (tongue-tie). A diagnostic and quandary. 30 (4): 259–62.
- [11] Belmehdi, A., Harti, K. E., & Wady, W. E. (2018). Ankyloglossia as an oral functional problem and its surgical management. *Dental and medical problems*, 55 (2), 213–216.
- [12] Brookes, A., & Bowley, D. M. (2014). Tongue tie: the evidence for frenotomy. *Early human development*, 90 (11), 765–768.
- [13] Khan, S., Sharma, S., & Sharma, V. K. (2017). Ankyloglossia: Surgical management and functional rehabilitation of tongue. *Indian journal of dental research: official publication of Indian Society for Dental Research*, 28 (5), 585–587.
- [14] Ghaheri B, Cole M, Mace J. Revision lingual frenotomy improves patient-reported breastfeeding outcomes: A prospective cohort study. *J Hum Lact* 2018; 34 (3): 566-74.
- [15] Ortiz, G., Gonzáles, F., Gonzáles, B. (2009). Anquiloglosia parcial (incompleta). Reporte de un caso y revisión de la literatura. *Órgano Oficial de la Asociación dental Mexicana*. (2): 42-47.
- [16] Khairnar, M., Pawar, B., & Khairnar, D. (2014). A Novel Surgical Pre-suturing Technique for the Management of Ankyloglossia. *Journal of surgical technique and case report*, 6 (2), 49–54.
- [17] Magaña M, Robles M, Guerrero. (2014). Alteraciones bucales del recién nacido. *ADM*. 71 (3): 115-119.
- [18] Chinnadurai, S., Francis, D. O., Epstein, R. A., Morad, A., Kohanim, S., & McPheeters, M. (2015). Treatment of ankyloglossia for reasons other than breastfeeding: a systematic review. *Pediatrics*, 135 (6), e1467–e1474.
- [19] Walsh, J., Tunkel, D. (2017). *Diagnosis and Treatment of Ankyloglossia in Newborns and Infants: A Review*. 143 (10): 1032-1039.