

# Adenocarcinoma of the Bladder in Exstrophy-Epispadias Complex in Adult Patients: About Two Cases

Babacar Sine<sup>1,2,\*</sup>, Mouhamed Feki<sup>1</sup>, Ndéye Aissatou Bagayogo<sup>2</sup>, Alioune Sarr<sup>1</sup>, Abdoulaye Ndiath<sup>1</sup>, Amath Thiam<sup>2</sup>, Ndiaga Seck Ndour<sup>1</sup>, Ousmane Sow<sup>1</sup>, El Hadji Malick Diaw<sup>1</sup>, Cyrille Ze Ondo<sup>1</sup>, Yaya Sow<sup>1</sup>, Alain Khassim Ndoeye<sup>1</sup>

<sup>1</sup>Urology Andrology Department, Aristide Le Dantec Hospital, Dakar, Senegal

<sup>2</sup>Urology Andrology Department, Ouakam Military Hospital, Dakar, Senegal

## Email address:

papesine@yahoo.fr (Babacar Sine)

\*Corresponding author

## To cite this article:

Babacar Sine, Mouhamed Feki, Ndéye Aissatou Bagayogo, Alioune Sarr, Abdoulaye Ndiath et al. (2024). Adenocarcinoma of the Bladder in Exstrophy-Epispadias Complex in Adult Patients: About Two Cases. *International Journal of Clinical Urology*, 8(1), 1-3.

<https://doi.org/10.11648/ijcu.20240801.11>

**Received:** December 4, 2023; **Accepted:** January 18, 2024; **Published:** February 1, 2024

---

**Abstract:** The primary mucinous adenocarcinoma of the bladder is an extremely rare urologic entity, which is found in less than 2% of all urinary bladder tumors and is often presented as metastatic. The authors report two cases of bladder adenocarcinoma with epispadias bladder exstrophy complex in two adults. The first case was about a 40-year-old patient referred for management of an EEC evolving since birth. The examination on admission revealed a deterioration in general condition and a bladder plate seat of an ulcero-necrotic tumefaction 3 x 2,5 cm with complete epispadias. The ureteral meatus were visible on each side at the lower part of the plate. Biopsy of the ulcero-necrotic mass revealed a well-differentiated bladder adenocarcinoma. Radical cystectomy and urinary diversion with an ileal conduit, and an expanded local lymphadenectomy was Indicated but the patient died before performing surgery. The second case is about a 28-year-old patient referred for management of an EEC evolving since birth associated with bilateral groin hernia. He had a good general condition, a bladder plate with complete epispadias. Treatment was cystectomy with Bricker urinary. Histo-pathological examination of the specimen reveled mucinous adenocarcinoma of the bladder. After review of the literature, it is a histological type with a poor prognosis and the role of surgery and adjuvant treatment remains to be defined.

**Keywords:** Exstrophy-Epispadias Complex, Adenocarcinoma, Cystectomy

---

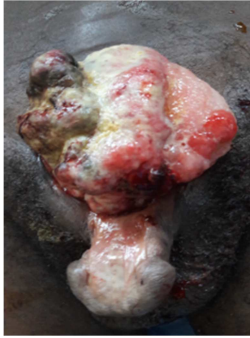## 1. Introduction

The exstrophy-epispadias complex (EEC) occurs in ~1/35,000 live births [1], and the risk of bladder carcinoma in the EEC population is 700-times higher compared with that of the age-matched general population [2]. It is a condition treated in the neonatal period and the risk of malignant transformation increases with age [3]. The occurrence of cancer on an EEC in an adult is an unusual situation which makes management even more difficult. we report two cases of bladder adenocarcinoma on EEC in two adults.

## 2. Case Presentation

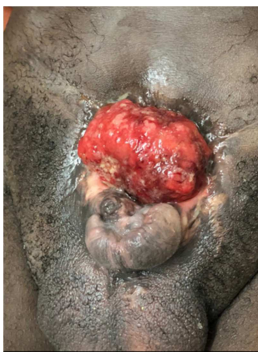Case 1: This was a 40-year-old patient referred for management of an EEC evolving since birth. There was no history, and he was married. The examination on admission revealed a deterioration in general condition with an ECOG score of 3, hypogastric protection using sachets as diapers, the ablation of which revealed a bladder plate seat of an ulcero-necrotic tumefaction 3 x 2,5 cm with complete epispadias (figure 1). The ureteral meatus were visible on each side at the lower part of the plate. Additional examinations had shown normal serum creatinine. The hemoglobin level was 11 g/dl and there was a non-specific biological inflammatory syndrome. Biopsy of the ulcero-necrotic mass revealed a

well-differentiated bladder adenocarcinoma. The thoraco-abdomino-pelvic CT scan revealed inguinal lymph nodes but there were no secondary visceral localizations. Radical cystectomy and urinary diversion with a ileal conduit, and an expanded local lymphadenectomy was Indicated. The patient died on day 8 of hospitalization before performing the surgery.

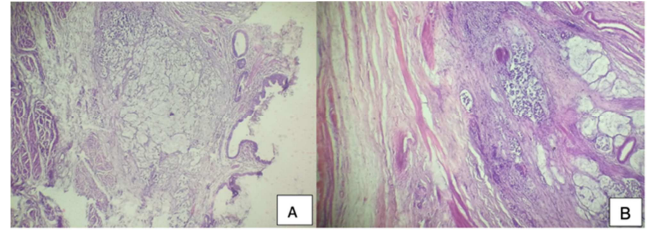


**Figure 1.** Preoperative view of the patient with exstrophy-epispadias complex. Bladder plaque showing ulcerative budding tumor on the upper right.

Case 2: A 28-year-old patient referred for management of an EEC evolving since birth associated with bilateral groin hernia. He had a good general condition (ECOG score 1), a bladder plate with complete epispadias (figure 2). The ureteral meatus were visible on each side at the lower part of the plate. Additional examinations had shown normal serum creatinine. The hemoglobin level was 12 g/dl and there was a non-specific biological inflammatory syndrome. He initially had a bilateral cure of the hernia and an attempt to close the bladder plate. The follow-ups were marked by a loosening of the sutures at the level of the hypogastric wall repair. Eight months later, a cystectomy and urinary diversion according to Bricker were proposed and performed. Histopathological analysis of the plaque revealed bladder adenocarcinoma (figure 3). No cancer tissue was detected in the resected prostate or lymph nodes. Following surgery, no adjuvant therapy was applied. The follow-ups were simple, and the patient was discharged on day 12. He was lost of sight and returned to consultation a year later with a hypogastric mass and pelvic shielding compatible with local recurrence of the cancer. The patient was referred to medical oncology and radiotherapy for further treatment).



**Figure 2.** Preoperative view of the patient with exstrophy-epispadias complex. Bladder plaque showing ulcerated areas.



**Figure 3.** Mucinous adenocarcinoma of the bladder infiltrating the muscularis (case 2).

### 3. Discussion

Epidemiologically, global data has shown that bladder exstrophy occurs in approximately 2 out of 100,000 births [4, 5]. In Senegal, the data is not well documented. Hospital study carried out recorded 21 bladder exstrophies between January 1990 and December 2004. Mean age of patients was 5, 4 years (1 day and 37 years). The majority of patients were male [6]. Our patients were seen in consultation quite late. This long delay could be explained by certain beliefs in our regions according to which these malformations are an evil fate that should be treated first with traditional medicine. Authors have also reported that ECC was considered a subject of shame among some people because it affects the private parts, which would explain the fact that it is hidden for as long as possible [7, 8].

The diagnosis should be made in the prenatal period with advances in obstetric imaging [9]. In neglected cases of bladder exstrophy, the progression would be towards an impairment of renal function and a degenerative risk. The incidence of malignancy occurs between the third and fourth trimester of life. Patients with bladder exstrophy have an incidence of bladder cancer 700 times higher than that of the general population at the same age [10]. Adenocarcinoma is the most common histological type in cases of bladder exstrophy, which represents 95% of cases. this is the histological type reported in our patients [11]. The etiopathogenesis of this tumor remains controversial. Its starting point would be diffuse intestinal metaplasia of the mucosa favored by chronic irritation on bladder exstrophy due to recurrent infections and chronic inflammation [12-14]. At birth, hamartomatous polyps are visible on the exstrophic bladder surface in about 50% of the cases [15]. These polyps have been interpreted as reactive, potential pre-malignant environmental changes. Therefore, closure of the bladder template within the first few hours of life is widely recommended. However, no direct proof was made that bladder cancer is developing from a polyp or a coexistent glandular metaplasia [15].

Usually, the diagnosis of bladder cancers is made by histopathological examination of transurethral resection of the bladder (TURBT) shavings. In our patients the diagnosis was made by biopsy in one and by analysis of the cystectomy surgical specimen in the other.

Treatment should be started within the first hours of life to prevent complications. This treatment aims to protect renal function, ensure good sexual functioning and good urinary

continence through cavitation of the bladder plaque, sphincter repair and abdominogenital plasty, while total excision of the plaque with performance of a continent urinary diversion or non-continent diversion would be indicated in adults. The management of adenocarcinoma on EEC remains a complex problem. Indeed, it must consider urine leakage, wall closure and repair of the external genitalia and cancer treatment. The surgical treatment initiated in one of our patients allowed partial correction of the anomalies with a reduction in leaks which can be collected by the Bricker pouch. However, the appearance of the penis could not be corrected. This patient also had a recurrence of the adenocarcinoma and is currently undergoing radio-chemotherapy. This treatment of exstrophic bladder adenocarcinomas can only be conceived within the framework of a multidisciplinary approach. Cystectomy with lymph node dissection remains the standard treatment [6-8]. Radiotherapy and chemotherapy may be indicated as neoadjuvant and/or adjuvant therapy in certain cases.

The prognosis of this histological entity is generally poor due to its discovery at an advanced stage at diagnosis. In the general population the 5-year survival rate for this type of cancer is 35 to 55% [4]. To date, no data are available to evaluate the prognosis of adenocarcinoma in patients with bladder exstrophy [8].

## 4. Conclusions

The bladder exstrophy-epispadias complex has a low incidence in our daily practice. Bladder adenocarcinoma due to exstrophy is also rare. The prognosis for this histological entity is poor. The diagnosis is often made incidentally. This should be considered when discovering EEC in an adult. Management of ECC should begin from discovery at birth. There is currently no well-codified treatment.

## ORCID

<https://orcid.org/0000-0001-5502-2117> (Babacar Sine)

## Ethics

We declare that this submission is in accordance with the principles laid down by the Responsible Research Publication Position Statements as developed at the 2nd World Conference on Research Integrity in Singapore, 2010. The heads of our departments have approved the study. We are sorry but there was no formal document authorizing the study.

## Author Contributions

All authors participated in the study. All authors read and approved the final version of the manuscript.

## Conflicts of Interest

The authors declare no conflicts of interest.

## References

- [1] Grossfeld GD and Carroll PR: Evaluation of asymptomatic microscopic hematuria. *Urol Clin North Am* 1998, 25: 661-676.
- [2] Smeulders N and Woodhouse CR: Neoplasia in adult exstrophy patients. *BJU Int* 87: 623-628, 2001.
- [3] Xiong, W, Peng R, Zhu L, Zhong Z. Bladder exstrophy-epispadias complex with adenocarcinoma in an adult patient: A case report. *Experimental and Therapeutic Medicine* 2015, 10(6), 2194-2196.
- [4] Hamid, A. R. A., Mochtar, C. A., Saraswati, M., Matondang, S., & Affan, M. I. F. (2021). Adenocarcinoma mucinosum of exstrophy bladder: A rare case report. *International Journal of Surgery Case Reports*, 88, 106493.
- [5] Sharma PK, Pandey PK, Vijay M. K, Bera MK, Singh JP, Saha, K. Squamous cell carcinoma in exstrophy of the bladder. *Korean journal of urology* 2013, 54(8), 555-557.
- [6] Ze Ondo C, Fall B, Sow Y, Diallo Y, Sarr A, Thiam A et al. *Journal Africain de Chirurgie* 2016; 4(2): 67-70.
- [7] Ziouziou I, Karmouni T, El Khader K, Koutani A, Iben Attya Andaloussi A. L'exstrophie vésicale chez l'adulte: A propos de 5 cas. *Afr J Urol* 2014; 20(1): 53-58.
- [8] Castagnetti M, Tocco A, Capizzi A, Rigamonti W, Artibani W. Sexual function in men born with classic bladder exstrophy: a norm related study. *J Urol* 2010; 183: 1118-1122.
- [9] Mohammed B, Paul OJ, Mustapha A, Soufiane M, Fadl TM, Hassan, FM. Adénocarcinome sur une exstrophie de vessie chez un patient adulte: à propos d'un cas. *Pan African Medical Journal* 2018, 29(1), 1-6.
- [10] Roux, S., Poli-Merol, M. L., Merzeau, N., Larré, S., & Leon, P. Rare neuroendocrine tumor decades after bladder exstrophy repair with enterocystoplasty. *Journal of pediatric surgery case reports* 2018; 31: 10-12.
- [11] Touil A, Loughlimi H, El-Abbassi S, Elouazzani H, Mahassini N. Squamous cell carcinoma in bladder extrophy: a case report and literature review. *J Clin Case Rep*, 2017: 7(982), 2.
- [12] Kadouri Y, Hachem F, Lakssir J, Sayegh H, Benslimane L, Nouini Y. Adénocarcinome primitif de la vessie: à propos de 6 cas. *Pan Afr Med J*. 2020 Jun 3; 36: 61.
- [13] Filmer RB, Spencer JR. Malignancies in bladder augmentations and intestinal conduits. *J Urol*. 1990 Apr; 143(4): 671-678.
- [14] Culp DA. The histology of the exstrophied bladder. *J Urol*. 1964 May; 91: 538-548.
- [15] Ebert AK, Reutter H, Ludwig M, Rösch WH. The exstrophy-epispadias complex. *Orphanet Journal of Rare Diseases* 2009; 4(1), 1-17.