



Treatment of Hemangiomas at OMF Region, Expressed in Comparative Results

Saimir Heta¹, Ilma Robo^{2,*}, Hysen Heta¹

¹University Hospital Center, Department of Pediatric Surgery, Tirana, Albania

²Faculty of Medical Sciences, Department of Periodontology, Lector of Clinic Periodontology, Albanian University, Tirana, Albania

Email address:

ilmarobo@yahoo.com (I. Robo)

*Corresponding author

To cite this article:

Saimir Heta, Ilma Robo, Hysen Heta. Treatment of Hemangiomas at OMF Region, Expressed in Comparative Results. *International Journal of Clinical Oral and Maxillofacial Surgery*. Vol. 3, No. 3, 2017, pp. 16-19. doi: 10.11648/j.ijcoms.20170303.11

Received: May 2, 2017; **Accepted:** October 10, 2017; **Published:** November 25, 2017

Abstract: The incidence of infantile hemangioma is from 1.1, up to 2.6%. This incidence increases with 10.1% in each year of change of age. The ways of treatment vary with their advantages and disadvantages. Given the difficulty, to predict whether a lesion will be roughly progress or not, we have tried for the comparison in quantitative manner of treatment methodologies. In the study are included 32 children with hemangioma, in variable localization, to treat with various methods of treatment, in order partial or total regression. Are analyzed the results between localization and method of therapy, regression, complications associated with the provided demographic data (male, female and age). The link between partial and total regression for hemangioma under division in regions of the face, head and neck, in the amount p value, is 0.0001. Relationship between partial regression and age speaks for positive results, as the age reduces. Treatment of hemangioma is always in development options, in terms of interference with as most of the few surgical. Regression is most positive in the age of many more to be minor.

Keywords: Hemangioma, Regression, Complications, OMF Localization

1. Introduction

Hemangiomas actually are a more general term for vascular malformation which can range from infantile spots, to anterior venous fistulas. Classification of hemangiomas is very difficult. The simplest one is the classification who divides the hemangiomas into capillary, cavernous, and mixed. In this tumor in many cases there is a trend of regression after a period of rapid growth. Infantile hemangioma is the most frequent tumor in childhood age. Has an incidence of 1.1 to 2.6 % in newborns. This incidence rises to 10.1% at the age of 1 year, according to Edgerton MT et al. and Höger PH et al. It is very difficult through clinical and imagery aspect, despite advancements in understanding of the natural behavior of hemangiomas, to predict which lesion will or will not regress with time.

Hemangiomas treatment has many methods like observation which we mention above, compression made especially in limbs, is continuous by bandage and intermittent

by pneumatic compression. Sclerosis treatment is made by solutions that are irritant and thrombogenic and provoke inflammatory tissue reaction which causes fibrosis and obliteration of vases. Radiation is not used any more. Steroid treatment has been used widely in the past. Surgery is one of the most used way of treatment but has his problem and his applicability. Our study focused on hemangioma type lesions in oro-maxillo-facial (OMF) areas, regardless of the age of pediatric children. At the request of the parents some were treated with surgery, some of the children are expected to reduce the size of hemangiomas with the increase of the size of the face, some of them treated with the first prescribed propranolol. This is the second phase of this study, as we are looking in the possible linkage of the OMF positioning of hemangiomas, the type of regression (total or partial), with the difference between gender (male/female ratio).

In last year's propranolol treatment has been very useful tool.

In 2008 Leauté-Labrèze et al published their first report about the efficacies of propranolol in the treatment of infantile hemangiomas.

The way how propranolol effect hemangiomas is not very well understood but in a study made by Chim H have been seen that treatment with propranolol led to a dose dependent cytotoxic effect in hemangioma endothelial cells with decreased cell viability, migration, and tubulogenesis. This cytotoxic effect was VEGF (vascular endothelial growth factor) dependent, as demonstrated by decreased VEGF, VEGF-R1, and VEGF-R2 production. Decreased signaling through the VEGF pathway resulted in downregulation of PI3/Akt and p38/MAPK activity. Decreased VEGF activity was mediated through the hypoxia inducible factor (HIF)-1 α pathway but not through NF- κ B signaling, according to Chim H et al.

2. Research Methods

In this study, we have taken 43 children who have hemangiomas in many localization. We have used diagnostic protocol including physical examination, imagery ultrasound or CT in rare cases and take the picture of the lesion. Children are consulted with cardiologist to enable the start of propranolol therapy. To the parents we explained in detail the advantages and disadvantages and after we take consensus the appropriate medication therapy begin. We begin with propranolol 1mg/kg dose, and is followed by 2 mg/kg. We have implemented a monthly follow up. The indications for this therapy are hemangioma localized in regions where surgery will be mutilated like face, finger. Hemangiomas very extended were the other therapeutic are not appropriate. Children were scheduled on a monthly follow up where the dose is changed based on the weight of those children where the therapy has not been very satisfactory. Simultaneously we have scheduled cardiologic follow up where children have regular cardiology visits with Heart Ultrasound, ECG.

3. Analysis Results

Since 2011 we have taken 56 children in treatment with 13 of them have not continued the protocol indicated, so were removed from the study. By 43 children, 32 have hemangiomas positioned in OMF region.

In these 32 children we have 28 girls and 4 boys. (*Table 1*)

Treatment continued for 6.4 months on average. In a period 6 to 9 months. We share in total regression results in partial regression and no response to treatment. In total regression we define those case where we don't see any hemangioma or remnant at all after the treatment. It is worth stressing that there was no case in which the hemangioma to advance under treatment with propranolol.

Complete regression 5 cases, partial regression 21 cases, without regression 2. (*Table 5*) In the group with partial regression we include the children with skin sequel and non total disappearance of hemangioma. Complications we have only 3 cases, one case of diarrhea one case of dry skin and one case of fatigue. (*Table 6*)

The link between partial and total regression for hemangioma under division in regions of the face, head and

neck, in the amount p value, is 0.0001. Relationship between partial regression and age speaks for positive results, as the age reduces.

4. Discussion

The use of propranolol is something relatively new in treatment of Infantile Hemangiomas. We see that propranolol is a feasible and safe therapy in treatment of Infantile Hemangiomas. In our study we have a ratio boy /girl 1 to 9. This ratio is not unusual has been report of this ratio in several article of de Graaf M. et al and Schupp, C. J et al. But in our series is little high up. We see that 46% of the children treated with propranolol are between 4-8 months and 25% under 4 months. (*Table 2*) The mean age in our series is not feasible because we have in our series 2 children 11 and 12 years old so the mean age is higher than in other series and is not representative. In 9 (32%) cases we have used other therapies before treatment like observation 5 compression in 2 sclerotherapy 1 surgery in 2 other. (*Table 3*) In children who have used surgery we use propranolol because of relapse of hemangioma. In these 2 children we had total regression of hemangioma after the treatment with propranolol. As you see the range of therapies in our possessions it's a little beet limited so we have seen treatment with propranolol very useful tool. Localization in our series in 72% of cases we have hemangioma of the face. (*Table 4*) We don't have life threatening hemangiomas like in other series, based at Schupp, C. J. et al. We have total regression of 18% partial regression of 75% of children and no response in 2 cases. As we see, we have only 2 cases with no regression. One of these was a girl 12 years old with facial hemangioma in which extensive sclerotherapy was used. We have seen a very good response in our series where we have older children with a long history in literature have been report Zvulunov that propranolol is effective in older children. So it's feasible the use of propranolol even beyond proliferative fase. We emphasize the fact that during the treatment of hemangioma none of them proliferate or become worse.

Has been many reports for the complication of treatment with propranolol we have seen in our series only 3 complications, 1 case with diarrhea, 1 case with dry skin and 1 case with fatigue. We have no indication of hypoglycemia in our series but they are reports, based at Holland KE et al., of severe hypoglycemia and neurologic problems in children who have symptomatic hypoglycemia, according at Burns CM et al. So we have become more aware of this complication and in the last some children who can have hypoglycemia problem we measure blood glucose levels but we don't find any problem. For the problem of hypoglycemia we don't began the therapy in toddlers less than 2 months.

Table 1. Gender.

Male	Female
4	28
13.5%	87.5%

Table 2. Age of diagnosis and treatment.

Under 8 months	8 months – 3 years	3 years -
15	8	9
47%	25%	28%

Table 3. Therapies before treatment.

Observation	6	18%
Compression	2	6%
Surgery (relapse)	2	6%
Sclerotherapy	2	6%

Table 4. Localization.

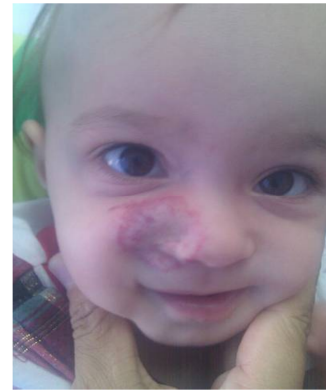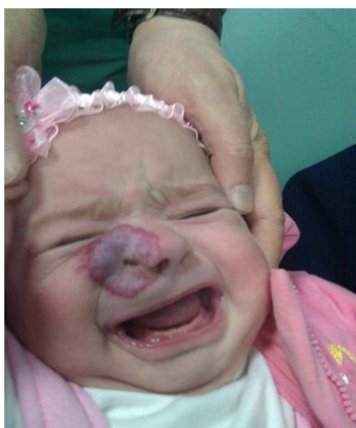
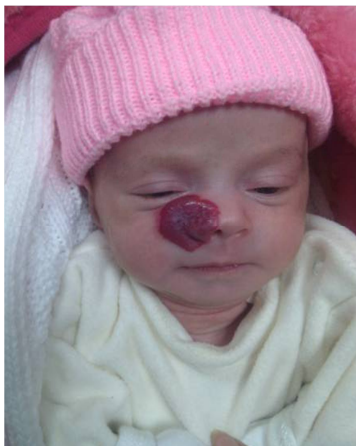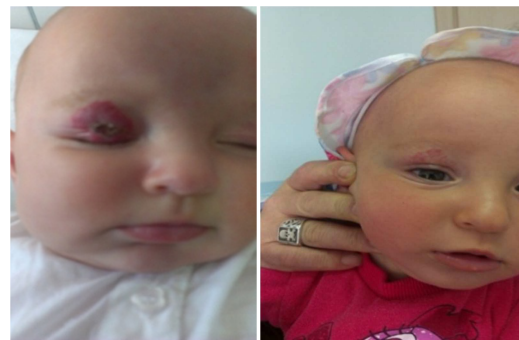Face	21	65.6%
Head	3	9.4%
Arms	2	6.25%
Neck	4	1.3%
Body	2	6.25%

Table 5. Result of treatment.

Total regression	6	18%
Partial regression	24	75%
No response	2	7%

Table 6. Complication.

Diarrhea	1	3.1%
Dry skin (Exanthema)	2	6.25%
Hypoglycemia	0	0%
Fatigue	2	6.25%
Aggravation of bronchitis or Asthma bronchial is	0	0%
Total	5	15.6%

**Figure 1.** After non full adherence to the treatment first and second photo, parents became more cautious the third photo.**Figure 2.** Another case after non full regression.

The adherence to the treatment is been e problem for us 9 of the children diagnosed with hemangioma doesn't fulfill the protocol. Some of them rejoin the protocol (see the picture) and are under treatment now.

5. Conclusions

Treatment of hemangioma is always in development options, in terms of interference with as most of the few surgical. Regression is most positive in the age of many more to be minor.

Treatment of hemangiomas with propranolol is a new tool in the treatment of hemangiomas. The use of propranolol is very effective and safe the complication observed are not life threatening and make possible to use in extensive time. The facts that during the treatment with propranolol the proliferation of hemangioma is arrested in all cases make us believe that the use of propranolol will be best solutions in many of Infantile Hemangiomas.

References

- [1] Burns CM, Rutherford MA, Boardman JP et al. (2008), Patterns of cerebral injury and neuropathologic outcomes after symptomatic neonatal hypoglycaemia. *Pediatrics*;122:65–74.
- [2] Chim H, Armijo BS, Miller E, Gliniak C, Serret MA, Gosain AK. (2012 Jul) Propranolol Induces Regression of Hemangioma Cells Through HIF-1 α -Mediated Inhibition of VEGF-A. *Ann Surg*. 256(1):146-56.

- [3] de Graaf M, Breur JM, Raphaël MF, Vos M, Breugem CC, Pasmans SG., (2011 Aug), Adverse effects of propranolol when used in the treatment of hemangiomas: a case series of 28 infants. *J Am Acad Dermatol*.;65(2):320-7. doi: 10.1016/j.jaad.2010.06.048.
- [4] Edgerton MT., (1976). The treatment of hemangioma with special reference to the role of steroid therapy. *Ann Surg*, 183:517-532.
- [5] Höger PH. (2012 Feb); Hemangioma. New aspects of pathogenesis, differential diagnosis and therapy. *Hautarzt*. 63(2):112-20. doi: 10.1007/s00105-011-2312-9.
- [6] Holland KE, Frieden IJ, Frommelt PC et al. (2010), Hypoglycemia in children taking propranolol for the treatment of infantile hemangioma. *Arch Dermatol*;146:775–778
- [7] Léauté-Labrèze C, Dumas de la Roque E, Hubiche T et al., (2008). Propranolol for severe hemangiomas of infancy. *N Engl J Med*; 12:358.
- [8] Schupp, C. J., Kleber, J.-B., Günther, P. and Holland-Cunz, S. (2011), Propranolol Therapy in 55 Infants with Infantile Hemangioma: Dosage, Duration, Adverse Effects, and Outcome. *Pediatric Dermatology*, 28: 640–644. doi: 10.1111/j.1525-1470.2011.01569.
- [9] Zvulonov A, McCuaig C, Frieden IJ et al. (2011), Oral propranolol therapy for infantile hemangiomas beyond the proliferation phase: a multicenter retrospective study. *Pediatr Dermatol*; 28:94-98.