

Case Report

A Case of Cauda Equina Arachnoiditis Ossificans and Review the Literature

Luo Jianxian, Yang Yuhao, Lin Hongsheng*

Department of Orthopedics, The First Affiliated Hospital of Jinan University, Guangzhou, China

Email address:

linhongsheng2019@126.com (Lin Hongsheng)

*Corresponding author

To cite this article:

Luo Jianxian, Yang Yuhao, Lin Hongsheng. A Case of Cauda Equina Arachnoiditis Ossificans and Review the Literature. *Clinical Neurology and Neuroscience*. Vol. 3, No. 3, 2019, pp. 66-68. doi: 10.11648/j.cnn.20190303.12

Received: June 9, 2019; Accepted: July 15, 2019; Published: July 30, 2019

Abstract: Arachnoiditis ossificans is a rare, chronic and progressive disease, especially cauda equina. Most of its causes are due to severe trauma or sequelae after spinal surgery, generally gradual calcification from the initial adhesive arachnoiditis to the end stage of ossified arachnoiditis. At present, the treatment of this rare disease standard is difficult to determine, and the clinical outcomes of conservative and surgical treatment options remain controversial. We present a 26-year-old female patient who was postoperative lumbar surgery for trauma, plain and reconstructive X-ray, CT and MRI images showed an ossified lesion within the master at the L5-S1 levels and compression of the left spinal canal at L4/5 level. We explored and decompressed spinal canal and released root nerves, while the calcified cauda equina nerve was not treated. Postoperative supportive treatment including detumescence, anti-inflammation, nutritional nerve and analgesia, the postoperative clinical course of the patient was good and the patient was very satisfied with the curative effect. This case, along with a review of literature is reported.

Keywords: Arachnoiditis Ossificans, Cauda Equine, Treatment

1. Introduction

Arachnoiditis ossificans is a rare disease in the clinic. Arachnoiditis ossificans in cauda equina is more rare. It is characterised by adhesion, calcification, ossification and obvious neurological sequelae after arachnoid inflammation. At present, it is believed that these changes are due to previous operations, trauma, spinal cord disease, infection and subarachnoid hemorrhage [1]. A typical case of cauda equina Arachnoiditis ossificans is reported as follows.

2. Case Report

A 26-year-old woman was admitted to our hospital because of 5 years of lumbar acid, aggravated pain of left lower limb for 1 month. She had multiple lumbar fractures and paraplegia of both lower limbs caused by high fall five years ago. She had undergone L1-S1 laminectomy, spinal canal decompression and T12-S1 pedicle screw and rod

internal fixation. The symptoms relieved and muscle strength recovered year by year after operation. One month ago, Her symptoms were aggravated and came to our hospital for treatment. Physical examination on admission: no obvious deformity of the spine and limbs, tenderness of lumbosacral spinous process and paraspinal process, radiation pain along the left lower extremity during lumbar over extension, 45° positive in the straight leg raising test and negative in the right leg. 3 grade in the left lower extremity backward extensor muscle strength, 4-5 grade in the left lower extremity residual muscle strength, physiological reflexes were normal and pathological reflexes were not elicited. CT results: changes after removal of T12-S1 internal fixation, stenosis of L1, L2, L5 and S1 horizontal spinal canals, sacral dural calcification, and compression of the left spinal canal at L4/5 level (Figure 1). Diagnosis: 1. cauda equina arachnoiditis ossificans; 2. Syringomyelia; 3. Postoperative lumbar fracture. Under general anesthesia, posterior L4/5 spinal canal exploration and decompression, nerve root

release, pedicle screw system and cage fixation were performed. Bilateral L4 pedicle isthmus rupture, granulation tissue hyperplasia and serious deformation and hyperplasia of bilateral L4/5 articular processes were observed during the operation. The L4/5 bilateral vertebral plate were resected, we found that the ligamentum flavum was thickened and adhered to the dura mater. L5 nerve root was obvious edema and compressed by small bone blocks, it was decompressed and released. L5 and S1 levels of dura mater, arachnoid membrane and surrounding soft tissue adhesion were serious, no pulsation of dura mater in the vertebral canal, local ossification, cauda equina nerve was wrapped by bone structure. In order to prevent interference or injury cauda equina nerve, we didn't release of cauda equina nerve. After operation, nutritional nerve, anti-inflammatory and other supportive treatments were arranged, the internal fixation position of X-ray film is good. The patient's left lower limb pain is obviously relieved, recovered well.

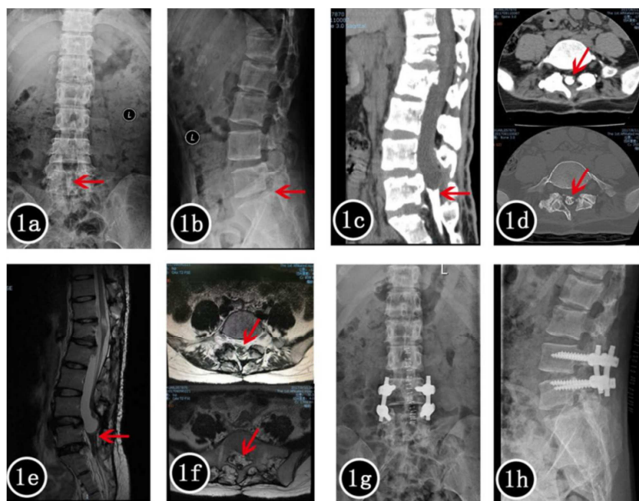


Figure 1. 1a and 1b, preoperative lumbar X-ray films showed blurred calcification in lumbosacral spinal canal; 1c and 1d preoperative lumbar CT showed ossification in L5-S1 horizontal spinal canal; 1e and 1f, preoperative lumbar MRI showed abnormal signal in L5-S1 horizontal spinal canal; 1g and 1h, 1 month after surgery, lumbar X-ray films showed that L4/5 vertebral lamina had been removed and internal fixation was well (Red arrows indicate calcified arachnoid membranes).

3. Discussion

Arachnoid calcification or ossification is a common phenomenon in surgery and autopsy [2-4]. These deposits are considered to be calcium crystals produced by degenerative processes, not real bone tissue, and they are not considered to cause clinically significant symptoms [5]. Arachnoiditis ossificans in the spine is a rare clinical disease, especially in the cauda equina. The first case of arachnoiditis ossificans was reported by Gatzke in 1957 [6]. At present, less than 80 cases had been reported [5]. It is characterized by pathological ossification of the arachnoid membrane and is considered to be the result of arachnoid inflammation. However, the specific pathogenesis of the disease has not been fully elucidated

[7]. So far, it is believed that most of the causes of the disease are predisposing factors, because it is well known that the arachnoid membrane between the soft spinal meninges and the dura mater has no blood supply and little inflammation. However, under the stimulation of pathogenic factors, there will be inflammation between the soft spinal meninges and the dura mater. With the development of inflammation, the arachnoid fibers become thicker, and there will be arachnoiditis by adhering to the adjacent soft spinal meninges and only a very small number of the final calcification or ossification of the formation of arachnoiditis ossificans. This case has a clear history of trauma and surgery, because we believe that it is very likely that multiple fractures of the lumbar spine or L1-S1 operation will cause sacral dura and soft spinal meninges injury, which will lead to arachnoid inflammation in this area, then gradually calcification, and eventually to the formation of a rare cauda equina Arachnoiditis ossificans.

Nowadays, effective methods of clinical diagnosis of arachnoiditis ossificans mainly include CT and MRI. Myelography lacks specificity and often leads to misdiagnosis [8, 9]. Christopher *et al.* believe that due to the difference of attenuation coefficient between CSF and bone tissue, conventional CT is more sensitive to intradural calcification, while MRI can help to show the degree of spinal cord compression and syringomyelia that may accompany the disease. The preoperative CT sagittal plane in this case showed a calcified strip lesion in the spinal canal below the L5 vertebral body level, which was the dura mater calcified in the sacral canal. Local defect of conus medullaris can be seen on MRI (Figure 1). Therefore, in the diagnosis of arachnoiditis ossificans, common CT and MRI can be used as complementary basis.

The treatment of arachnoiditis ossificans is still a difficult problem. The rare nature of this disease makes it difficult to determine the standard treatment regimen, and the clinical outcomes of conservative treatment and surgical treatment regimens are uneven [10-12]. Changbing Wang and others believe that patients with mild symptoms should be observed and treated, while patients with severe or deteriorating symptoms should be treated by surgery, and the main purpose of surgery is to decompress [13, 14]. Domenicucci *et al.* reported that only about half of the patients receiving surgical treatment had improved their symptoms, while the patients receiving conservative treatment had achieved satisfactory improvement through drug treatment. Therefore, it was considered that active surgical treatment could not guarantee improvement of symptoms [1]. Li Diliu and others believe that arachnoiditis is a relatively rare disease with unknown etiology and limited treatment. Surgical intervention should be carefully considered, because it may lead to adverse outcomes and multiple revision operations [15]. In this case, L4/5 spinal canal stenosis is obvious, which can be considered as the main cause of lumbar acid, plantar numbness and lower limb muscle weakness. Therefore, we utilized spinal canal

decompression and internal fixation to relieve nerve root compression, but did not deal with the calcified lesions in the sacral canal. The symptoms of the patients were relieved obviously after operation, and satisfactory clinical effects were achieved.

4. Conclusion

This is a rare case of cauda equina arachnoiditis ossificans after trauma and operation. The early diagnosis of cauda equina arachnoiditis ossificans mainly relies on CT and MRI. At present, there is still controversy about its treatment, however, through literature review and our relevant experience, we believe that the treatment of cauda equina arachnoiditis ossificans is mainly conservative treatment, surgical treatment is cautious, and surgical treatment is mainly decompression.

Conflict of Interests

Authors have no potential competing interests or conflicts to report.

Acknowledgements

This work was supported by National Natural Science Foundation of China (81771331), Natural Science Foundation of Guangdong Province, China (2017A030313595), and Guangzhou science and technology project (201605130849016).

References

- [1] Domenicucci M, Ramieri A, Passacantilli E, Russo N, Trasimeni G, Delfini R. Spinal arachnoiditis ossificans: report of three cases. *Neurosurgery*. 2004. 55 (4): 985.
- [2] Opalak CF, Opalak ME. Arachnoiditis ossificans and syringomyelia: A unique presentation. *Surg Neurol Int*. 2015. 6 (Suppl 24): S608-10.
- [3] Bernard P, Vanhoenacker FM, Adam N. Arachnoiditis ossificans. *JBR-BTR*. 2010. 93: 108.
- [4] Wijdicks CA, Williams JM. Spinal arachnoid calcifications. *Clin Anat*. 2007. 20(5): 521-3.
- [5] Maulucci CM, Ghobrial GM, Oppenlander ME, Flanders AE, Vaccaro AR, Harrop JS. Arachnoiditis ossificans: clinical series and review of the literature. *Clin Neurol Neurosurg*. 2014. 124: 16-20.
- [6] GATZKE LD, DODGE HW, DOCKERTY MB. Arachnoiditis ossificans; report of two cases. *Proc Staff Meet Mayo Clin*. 1957. 32 (24): 698-704.
- [7] Bagley JH, Owens TR, Grunch BH, Moreno JR, Bagley CA. Arachnoiditis ossificans of the thoracic spine. *J Clin Neurosci*. 2014. 21 (3): 386-9.
- [8] Dennis MD, Altschuler E, Glenn W, Wiltse LL. Arachnoiditis ossificans. A case report diagnosed with computerized axial tomography. *Spine (Phila Pa 1976)*. 1983. 8 (1): 115-7.
- [9] Chan CC, Lau PY, Sun LK. Arachnoiditis ossificans. *Hong Kong Med J*. 2009. 15: 146-8.
- [10] Steel CJ, Abrames EL, O'Brien WT. Arachnoiditis Ossificans - A Rare Cause of Progressive Myelopathy. *Open Neuroimag J*. 2015. 9: 13-20.
- [11] Kumaran SP, Gupta K, Maddali A, Viswamitra S. Post traumatic arachnoiditis ossificans. *J Emerg Trauma Shock*. 2012. 5(3): 250-2.
- [12] Mello LR, Bernardes CI, Feltrin Y. Thoracic spine arachnoid ossification with and without cord cavitation. Report of three cases. *J Neurosurg*. 2001. 94: 115-20.
- [13] Kahler RJ, Knuckey NW, Davis S. Arachnoiditis ossificans and syringomyelia: a unique case report. *J Clin Neurosci*. 2000. 7 (1): 66-8.
- [14] EI Asri AC, EI Mostarchid B, Akhaddar A, Baallal H, Dao I, Naama O, Gazzaz M, Boucetta M. Arachnoiditis ossificans of the cauda equina. *Br J Neurosurg*. 2012. 26(4): 547-8.
- [15] Liu LD, Zhao S, Liu WG, Zhang SK. Arachnoiditis ossificans after spinal surgery. *Orthopedics*. 2015. 38 (5): e437-42.