



# Follow-up of a Barlow Mitral Valve Billowing and Prolapse Repair Patient

Roland Fasol<sup>1,\*</sup>, Noell Fasol<sup>2</sup>, Thomas Binder<sup>3</sup>

<sup>1</sup>Department of Cardio Thoracic Surgery, Tree Top Hospital, Male, Maldives

<sup>2</sup>School of Medicine, Sigmund Freud University Vienna, Vienna, Austria

<sup>3</sup>Department of Cardiology, AKH (Allgemeines Krankenhaus), University of Vienna, Vienna, Austria

## Email address:

[roland@fasol.us](mailto:roland@fasol.us) (R. Fasol)

\*Corresponding author

## To cite this article:

Roland Fasol, Noell Fasol, Thomas Binder. Follow-up of a Barlow Mitral Valve Billowing and Prolapse Repair Patient. *American Journal of Thoracic and Cardiovascular Surgery*. Vol. 2, No. 3, 2017, pp. 41-44. doi: 10.11648/j.ajtcv.20170203.11

**Received:** February 20, 2017; **Accepted:** March 29, 2017; **Published:** April 22, 2017

**Abstract:** We report the 20 year follow up of a female patient who underwent mitral valve billowing and prolapse (Barlow) repair at the age of 29 yrs. Our repair method to aggressively remodel the valve, which maximizes predictable anatomic and physiologic efficacy and minimizes unpredictable results incorporates a complete resection of the posterior leaflet, a sliding and folding plasty with the remaining lateral scallops combined with a triangular resection of the anterior leaflet and a ring-annuloplasty. This long term follow up confirms the absence of any sclerotic leaflet degeneration or calcification, a perfect leaflet coaptation and no regurgitation with normal ventricular function in regular sinus rhythm after 20 years.

**Keywords:** Mitral Valve, Valve Repair, Barlow

## 1. Introduction

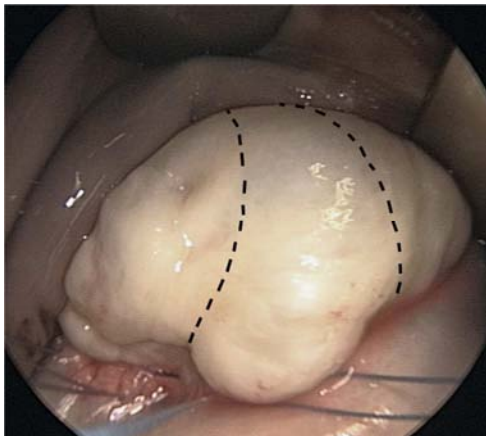
Mitral valve billowing and prolapse is commonly known as Barlow's disease, since the first mention of the systolic click in 1887 which is now known to be the auscultatory marker of this type of mitral valve disease [1]. This 'Barlow' pathology is found to summarize complex different mechanisms, namely thickening, thinning, elongation or ruptured chordae, deformed and dilated annulus, voluminous excess and multiple sites of leaflet prolapse [2]. Valve size in Barlow's disease is generally on the large side. Usually multiple segments are involved with myxomatous changes, resulting in thickened and distended 'floppy' leaflets. The typical Barlow patient is often a younger individual with a longer history of a regurgitant murmur, but often clinically asymptomatic. Indications for early surgery in this group of patients with hemodynamically important regurgitation depends on whether valve repair is judged to be feasible. Barlow's disease still represents a surgical challenge due to the complexity of the mechanisms involved. The prospects of a failed valvuloplasty influences some cardiologists and family doctors toward delaying surgery until the patient is significantly symptomatic. Even worse, there are some

surgeons and centers which tend to a replacement rather to a repair strategy despite it is widely accepted that repair procedures have highly superior long term results [3]. So called minimally invasive surgical procedures have gained maximal interest in the last 20 years and the focus on the surgical access may have altered the focus on the reproducibility of proven standard-of-care mitral repair techniques and results. More recently some alternative strategies like neochordal (Loop) [4] and edge-to-edge (Alfieri) repair techniques have been introduced with some perioperative failure rates of nearly 5% (more than mild mitral regurgitation requiring early reoperation), postoperative elevated resting mean gradients, smaller orifice areas and a short term freedom from mitral reoperation of only 90% [5]. These strategies, not based on a physiological reconstruction to remodel and repair the failing valve, will have to prove their results and efficacy in the long term and have to show that their theoretical 'easiness' of surgical execution can bear up to and reach the perfectness and superior short and long term results of 'conventional' and proven surgical repair techniques – which may be doubted.

We have shown that mitral valve repair in patients with billowing and prolapse (Barlow) is possible in every patient, if our modified repair technique, which is streamlined and simplified, is applied [6]. However, it was unknown at that time of surgery (20 years ago) if long term follow up will allow long lasting results or will be limited by sclerotic thickening and leaflet degeneration or calcification of the suture lines of the surgical intervention and the manipulation of the mitral mitral leaflets.

## 2. Patient Profile

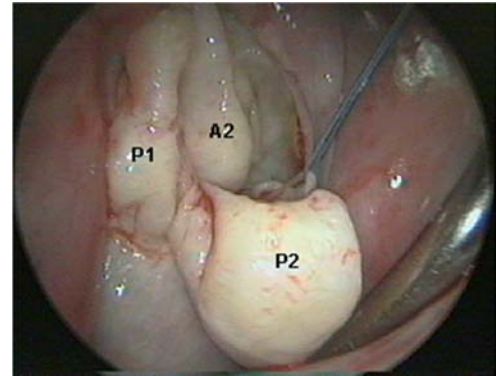
A 29-year-old female patient underwent mitral repair surgery due to severe mitral incompetence caused by Barlow's billowing and prolapse syndrome at the University of Vienna in 1997. This patient was admitted with progressive limitation of her physical activity with subsequent dyspnea only at higher physical activity (NYHA II). A cardiological routine assessment showed a regular sinus rhythm, but a severe mitral incompetence with more than one incompetence jet due to mitral valve billowing and prolapse (Barlow). This patient was one in a series of 37 consecutive patients who underwent mitral repair with our newly described method, which maximizes predictable anatomic and physiologic efficacy and minimizes unpredictable results, between 1996 and 1998, summarized and followed up in 2001 [6].



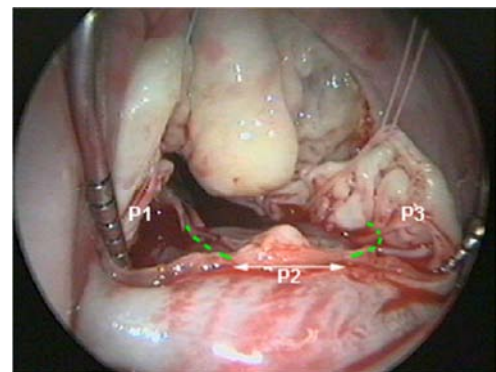
**Figure 1.** Intraoperative view of this typical 'Barlow valve' showing enormous hood-like bulging with significant excess tissue of all segments of the mitral valve. Dotted line shows the triangular resection of the anterior leaflet [A2].

Surgery in this reported female patient was performed through a small right sided thoracotomy. The repair concept to aggressively reduce the significant excess tissue and to physiologically remodel the valve included a triangular resection of the prolapsing and bulging anterior leaflet (A2) [figure 1]. Marked billowing and prolapse specifically of the posterior scallop P2 [figure 2] led to the complete resection of the middle posterior leaflet (P2) [figure 3] and a partial detachment of both of the remaining posterior scallops P1 and P3. Plication of the annulus was followed by a combined sliding leaflet and folding plasty with both of the remaining lateral scallops (P1 and P3) to create a "new" posterior leaflet [figure 4]. The surgical

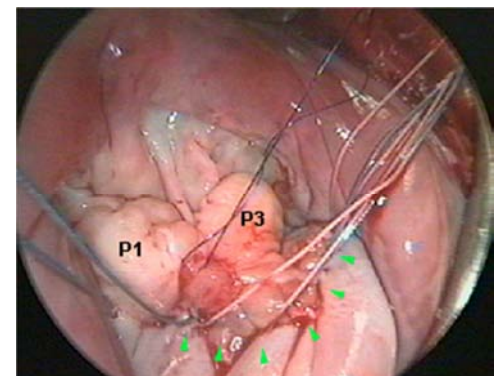
technique was described in detail before [6]. The size and extent of the triangular resection of the bulging part of the anterior leaflet was carefully matched to the extent of bulging and was performed according to a previously described technique [7]. Care is taken to keep clear of the anterior annulus, not to resect into the annulus and to save the major chordae.



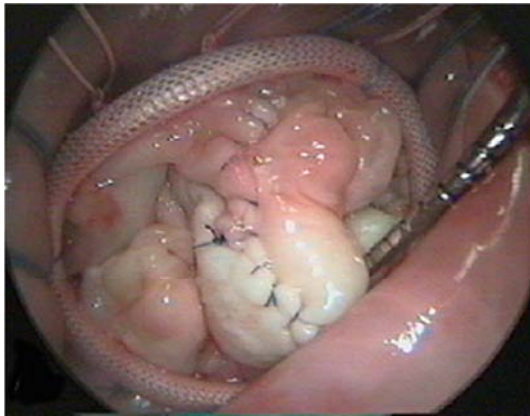
**Figure 2.** Assessment of the significant billowing and prolapse of the 'Barlow' mitral valve leaflets - specifically the scallops A2 and P2 show a marked billowing and prolapse which caused a significant mitral regurgitation.



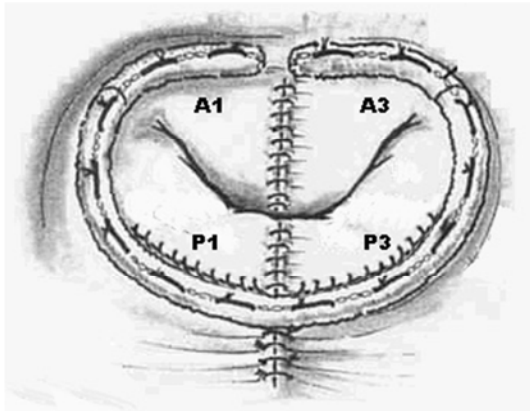
**Figure 3.** Complete resection of the middle scallop of the posterior leaflet [P2] and partial detachment of the remaining posterior scallops [P1 and P3 - see: green dotted line] to allow a sliding leaflet as well as a folding plasty with the remaining segments P1 and P3.



**Figure 4.** View of the reconstructed posterior leaflet. After complete resection of the scallop P2, the remaining lateral scallops P1 and P3 form the "new" posterior mitral leaflet by a sliding leaflet and folding plasty [green arrows]. Sutures for the annuloplasty ring have been put through the annulus before reattaching the leaflets.



**Figure 5.** Intraoperative view of the finalized repair showing the suture line of the triangular resection of the anterior leaflet - the size and extent of the resection carefully matched to the extent of bulging - and the implanted annuloplasty ring. [The remaining scallops A1 and A3 are re-approximated with a running 5-0 Peter's suture].



**Figure 6.** Schematic drawing of the repair concept, showing the suture lines of the triangular resection of the anterior leaflet [A2], the complete resection of the middle posterior leaflet [P2], sliding leaflet and folding plasty with both of the remaining posterior scallops [P1 and P3] all with running 5-0 Peter's sutures.

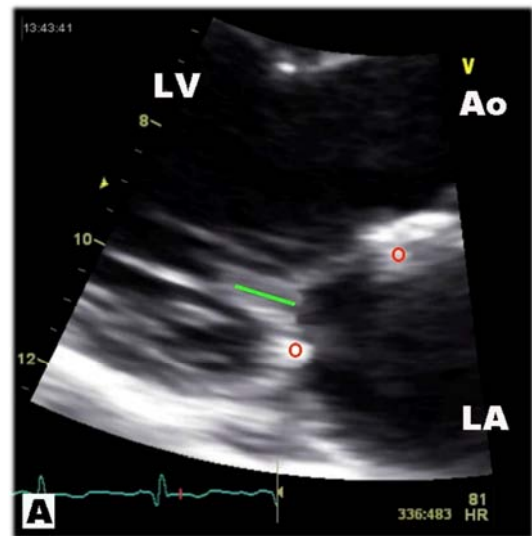
Two stay sutures attached to the free edges of the anterior leaflets of A1 and A3 (A2 to be removed) helped to take hold of the major chordae, to delineate the area of resection involved. Furthermore, instilling some cold saline into the left ventricle helped to visualize the prolapsed area to be resected, nicely demonstrated in figure 1 [7]. The free edges of resection are sewn using a running 5-0 Peter's suture, mildly taut and not cinched, so as to prevent corrugation of the leaflet tissue. The repair was completed by implanting an annuloplasty ring [figure 5]. Figure 6 summarizes the repair concept, the schematic drawing showing the suture lines.

The postoperative course of this female patient was completely uneventful and the patient could be closely followed up to this date. She had 3 uneventful pregnancies after surgery, is completely healthy and living a normal life as a working mother. Echocardiographic follow up demonstrates a significant postoperative ventricular remodeling resulting in normal ventricular dimensions and function, summarized in table 1.

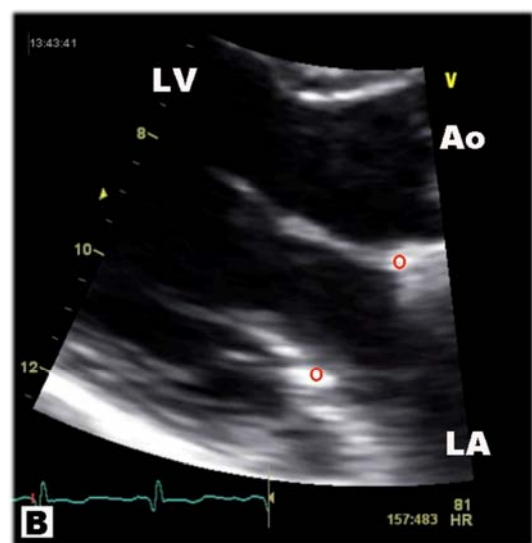
**Table 1.** Echocardiographic Variables.

Characteristic	Pre OR	2 yrs post	20 yrs post
LA ø (cm)	5.5	4.6	3.2
LVED ø (cm)	6.4	5.5	4.2
LVS ø (cm)	3.8	3.5	3.0

Up to this day the patient is without any medication, in stable sinus rhythm, with no limitation of her physical activity (NAHA I), with a normal heart function for her age and with no echocardiographic signs of any leaflet 'stiffness' or calcification of the operated valve leaflets after 20 years of follow up [Fig. 7A, B]. The patient describes the quality of her life as normal.



**Figure 7A.** Systolic parasternal long-axis view of the mitral valve at the 20 year follow up, showing normal mitral valve leaflets with no signs of any restricted leaflet movement or any hint of sclerotic degeneration, thickening or calcification. Note the full line of coaptation of the anterior and posterior leaflets (green bar). [LV = Left Ventricle; Ao = Aorta; LA = Left Atrium; red circle = mitral annuloplasty ring].



**Figure 7B.** Diastolic parasternal long-axis view of the mitral valve. Unrestricted mobility of the mitral leaflets allows normal mitral function at the 20 year follow up. No signs of leaflet 'stiffness' or calcification of the operated valve could be detected.

A total of 37 consecutive patients underwent mitral repair with this new method from 1996 to 1998. A short term follow-up collected in 1999 after a mean follow-up of  $22.7 \pm 8.6$  months (10 to 39 months) was 100% complete [6]. No patient had recurrent mitral regurgitation. There was one late death (2.7%). This patient died 2 years after mitral valve surgery due to cardiac failure at the age of 81 years. Of all surviving patients, 93.0% were in NYHA functional class I or II, all describing their quality of life as 'normal'. A ten-year follow-up was performed in 2008, however 10 of the 37 (27%) patients could not be found due to moving from their old address. All remaining patient were doing extremely well, had no consecutive surgery or adverse events, but with nearly 30% of the patients not contacted this information is of no value for a follow-up.

However, this reported case of a 29-year-old female patient allowed a regular and continuous echocardiographic follow up by the same cardiologist for 20 years. This report confirms the absence of any sclerotic leaflet degeneration or calcification, a perfect leaflet coaptation and no regurgitation with normal ventricular function in regular sinus rhythm after 20 years for our new method of mitral repair for a Barlow mitral valve.

### 3. Comments

Durability of mitral repair procedures and recurrence of regurgitation are influenced by inadequate procedures performed and specific surgical techniques used [8]. However, recurrence rates of regurgitation are rarely reported because most studies focus on survival and reoperation rates. At the time this surgery was performed no information was available regarding long term performance of specific techniques like triangular resection of the anterior leaflet [7]. To perform such a resection of the anterior leaflet was opposed by many and advocated only by few at that time [9]. It was not known if these suture lines in the long run stiffen the leaflet, calcify or cause other problems. We now know that specific surgical repair techniques like the non-use of a sliding annuloplasty have a predictive value for recurrence of regurgitation [10]. We also now know that the anterior leaflet can be attacked and corrected with good long term results.

To summarize the above, this case shows the excellent long term result of the approach to physiologically correct a Barlow's mitral valve billowing and prolapse.

### Conflict of Interest

Thomas Binder is founder of the internet education platform 123echocardiography.com, but all authors have no conflicts of interest to disclose. The authors did not perceive any source of support for this case report.

### References

- [1] Cuffer M, Barbillion M. Nouvelles recherches sur le bruit de galop cardiaque. *Arch Gen Med.* 1887; 19: 129–49.
- [2] Barlow JB, Bosman CK, Pocock WA, Marchand P. Late systolic murmurs and non-ejection ("mid-late") systolic clicks. An analysis of 90 patients. *Br Heart J.* 1968; 30: 203–18.
- [3] Adams DH, Rosenhek R, Falk V. Degenerative mitral valve regurgitation: best practice revolution. *Eur Heart J.* 2010; 31: 1958–66.
- [4] Fasol R, Slepian M. Artificial chordae replacement. US Patent. WO 99/11201; 1999.
- [5] Da Rocha e Silva J, Spampinato R, Misfeld M, et al. Barlow's mitral valve disease: A comparison of neochordal (loop) and edge-to-edge (Alfieri) minimally invasive repair techniques. *Ann Thorac Surg.* 2015; 100: 2127–35.
- [6] Fasol R, Mahdjoobian K. Repair of mitral billowing and prolapse (Barlow): The surgical technique. *Ann Thorac Surg.* 2002; 74: 602–5.
- [7] Fasol R, Joubert-Hübner E. Triangular resection of the anterior leaflet for repair of the mitral valve. *Ann Thorac Surg.* 2001; 71: 381–3.
- [8] Flameng W, Herijgers P, Bogaerts K. Recurrence of mitral valve regurgitation after mitral valve repair in degenerative valve disease. *Circulation.* 2003; 107 (12): 1609–13.
- [9] Deloche A, Jebara VA, Relland JY, et al. Valve repair with Carpentier techniques. The second decade. *J Thorac Cardiovasc Surg.* 1990; 99: 990–1001.
- [10] Flameng W, Meuris B, Herijgers P, Herregods MC. Durability of mitral valve repair in Barlow disease versus fibroelastic deficiency. *J Thorac Cardiovasc Surg.* 2008; 135: 274–82.