

## Case Report

# Clinical and Radiological Features of Possible Normal Pressure Hydrocephalus in a Patient with Multiple Sclerosis

Solomiia Bandrivska<sup>1,2,\*</sup>, Mykhailo Bandrivskiy<sup>1,3</sup>, Iryna Pepenina<sup>1</sup>, Natalia Maslianchuk<sup>1</sup>,  
Natalia Mykhailovska<sup>2</sup>, Iryna Lasiichuk<sup>4</sup>, Viktoriia Gryb<sup>5</sup>, Tatyana Slobodin<sup>1,2</sup>

<sup>1</sup>Department of Neurology, Medical Center of Limited Liability Company «Dobrobut Clvinic», Kyiv, Ukraine

<sup>2</sup>Department of Neurology No. 1, Shupyk National Healthcare University of Ukraine, Kyiv, Ukraine

<sup>3</sup>Department of Neurosurgery, Medical Center of Limited Liability Company «Neurospine», Kyiv, Ukraine

<sup>4</sup>Department of Neurology, Kolomyia Central Regional Hospital, Kolomyia, Ukraine

<sup>5</sup>Department of Neurology and Neurosurgery, Ivano Frankivsk National Medical University, Ivano Frankivsk, Ukraine

## Email address:

bandrivska.solomiia@gmail.com (Solomiia Bandrivska)

\*Corresponding author

## To cite this article:

Solomiia Bandrivska, Mykhailo Bandrivskiy, Iryna Pepenina, Natalia Maslianchuk, Natalia Mykhailovska, Iryna Lasiichuk, Viktoriia Gryb, Tatyana Slobodin. Clinical and Radiological Features of Possible Normal Pressure Hydrocephalus in a Patient with Multiple Sclerosis. *American Journal of Psychiatry and Neuroscience*. Vol. 11, No. 2, 2023, pp. 34-40. doi: 10.11648/j.ajpn.20231102.11

**Received:** March 8, 2023; **Accepted:** March 28, 2023; **Published:** April 11, 2023

**Abstract:** Normal pressure hydrocephalus (NPH) is potentially treatable form of dementia, which along with gait disturbance and impaired urinary control compose a clinical picture of the Hakim-Adams syndrome. In advanced age it could be challenging to distinguish the disease from other form of dementias or brain atrophy. From another prospective, other brain conditions could have a number of similar symptoms that could make it even harder to raise a suspicion of NPH. In this article we describe a clinical picture, neurological examination data, neuroimaging and clinical analysis of blood and cerebrospinal fluid (CSF) of the patient with confirmed multiple sclerosis (MS) and symptoms falling under Hakim-Adams triad criteria. On the other hand, pronounced cortical atrophy and patient's cognitive decline, could be a consequence of prolonged disease, absence of disease-modifying treatment and poor compliance of the patient. Challenges in management of the patient were not only limited by the duration of the multiple sclerosis, but also a number of comorbidities in the history of the disease and not straightforward data after performing the tap test. Thorough review of a patient with multiple sclerosis with clinical manifestations corresponding to Hakim's triad, and with ventriculomegaly on CT/MRI, should be performed as the comorbidity of MS and NPH has to be excluded.

**Keywords:** Normal Pressure Hydrocephalus, Multiple Sclerosis, Dementia, Ventricular Shunt

## 1. Introduction

Multiple sclerosis (MS) – is a chronic inflammatory demyelinating disease characterized by a progressive course and often accompanied by significant disability of the patient, especially in the later stages [1]. The most common presentations of multiple sclerosis are limb weakness, sensory disturbances, cerebellar discoordination, cranial nerve involvement. The course of the disease depends on the phenotypic classification: clinically isolated syndrome (CIS), relapsing-remitting (RRMS), primary progressive (PPMS)

and secondary progressive (SPMS) multiple sclerosis. PPMS symptoms can vary, but typical symptoms include vision problems, difficulty talking, problems walking, trouble with balance, general pain, stiff and weak legs, memory impairment, fatigue, trouble with bladder and bowel control, and depression. Along with typical clinical and radiological features, there are often cases of pathological processes belonging to the spectrum of multiple sclerosis but with different clinical presentations.

The variant of multiple sclerosis, the type of course, localization of MS plaques, and whether the patient receives

adequate disease-modifying therapy or not often determine the clinical manifestations of the disease and the degree of future disability. But in a few cases, symptoms are unusual, which makes the neurologist wonder if it is still a pathological process limited to one nosology. The following clinical case demonstrates the importance of paying attention to each new symptom in a patient with multiple sclerosis, which requires clinical and radiological comparison.

## 2. Clinical Case

### 2.1. Patient History

A 56-year-old female was referred to a neurologist. The patient uses a wheelchair with the assistance of her daughter. The reason for the referral to a neurologist is self-care problems due to irrational behavior, the patient's inability to control the functions of bowel and bladder, disorientation in space and time, and pronounced cognitive decline, which have become especially disturbing in recent years. The patient herself does not express any complaints. She is uncritical about her condition at the time of the examination.

From the history of the disease given by the daughter, the patient has had multiple sclerosis since 2000. The disorder manifested in dizziness, nausea, and imbalance. Numerous foci of demyelination were detected on MRI. Cognitive deficits to the degree of dementia, gait disturbances, and urinary incontinence were gradually built up to the primary features of the disease, because of which the patient stopped working and became disabled. She received interferon B and glatiramer acetate as disease-modifying therapy from 2005 to 2013. She had been undergoing pulse therapy with methylprednisolone for relapses. Due to impaired gait and balance, a fracture of the neck of the left femur occurred 2

months before admission.

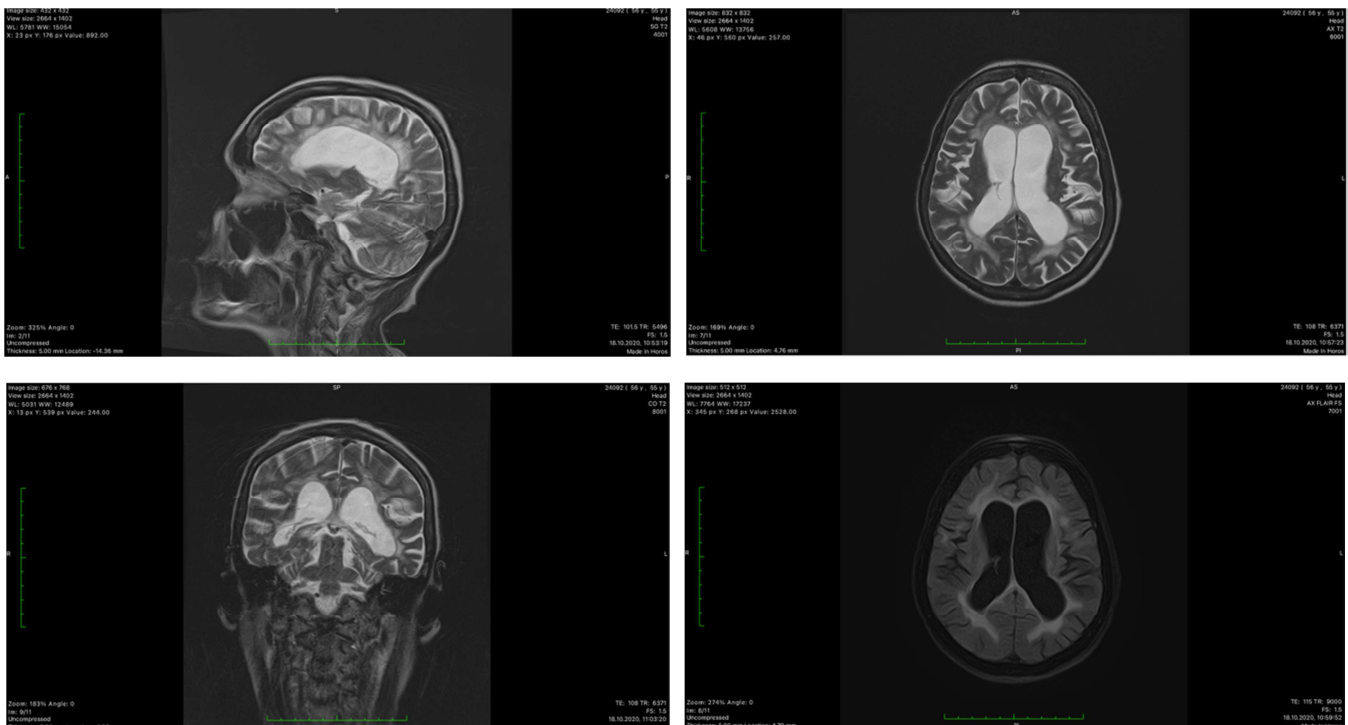
### 2.2. Clinical Examination

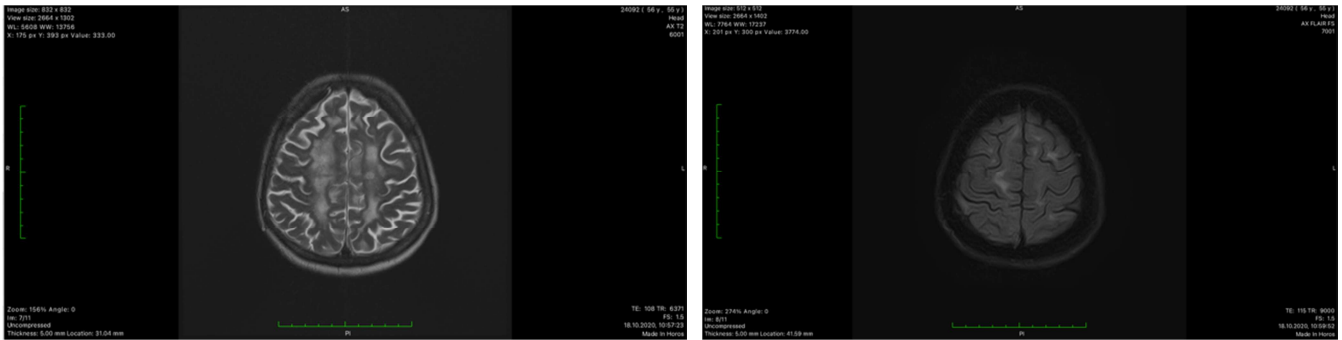
Neurological examination shows that the patient is available for language contact and answers to questions but has no insight into her own condition and is wholly disoriented in time and space but oriented in her own person (tells her name). The patient tells information that contradicts the history of the disease and the objective condition: she notes that she takes care of herself in everyday life, in particular, goes to the store for shopping and does not use additional means of transportation. Severe impaired memory and executive functions are prominent at the visit. According to objective assessment scales, cognitive status is: Mini-mental state examination (MMSE test) – 10 points, Montreal cognitive Assessment (MoCa test) – 4 points. Self-care is objectively impaired by cognitive decline. Bilateral pyramidal symptoms with the presence of pathological reflexes of Babinski, Strümpel, and Rossolimo with mild paresis in the lower limbs (4/5 points) are observed. Slight athetoid movements are present in the right hand. The patient needs support in walking: she does small steps with her legs wide apart and cannot make turns without assistance. Urinary control is violated.

### 2.3. Neuroimaging

The clinical features of the disease, which are not typical for multiple sclerosis, were combined with unusual neuroimaging findings (Figure 1).

A set of clinical symptoms (pronounced cognitive impairment, impaired gait and balance, urinary control), together with ventriculomegaly, prompted a revision of the diagnosis in favor of normal pressure hydrocephalus (NPH) [2].

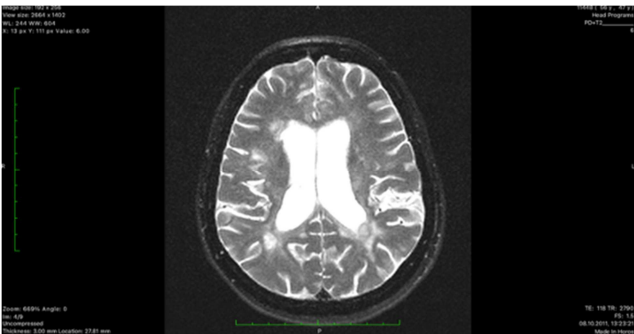




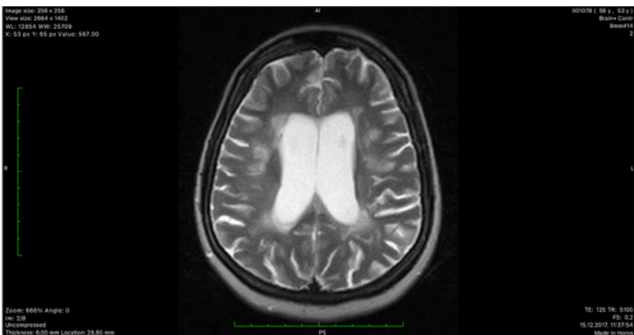
**Figure 1.** According to MRI data since 18 October 2020: the ventricular system is expanded; the width of the anterior horns of the lateral ventricles at the level of foramen Monro is 20 mm on the right, 22 mm on the left; III ventricle 16 mm, IV ventricle 19 mm; on the periphery of the ventricles there are wide zones of leukoaraiosis in the white matter with spread to the subcortical regions.

Additional questions to the daughter regarding the medical history revealed that in 1998 the patient suffered a mild traumatic brain injury due to falling on a metal pipe. According to the CT scan of the brain taken immediately after the injury: brain matter is without traumatic injuries, and expansion of the ventricular system is noted (the lateral ventricles are up to 1.2 cm at the level of the anterior horns, at the level of the ventricular bodies are up to 1.5 cm; III ventricle width is 0.6 cm). A short time after the injury, the patient developed dizziness, periodic headache, nausea, and imbalance. During a thorough review of the history, presumably, the patient was diagnosed with secondary syphilis and was medically treated back in 2003. The patient does not have any medical papers about this fact of disease.

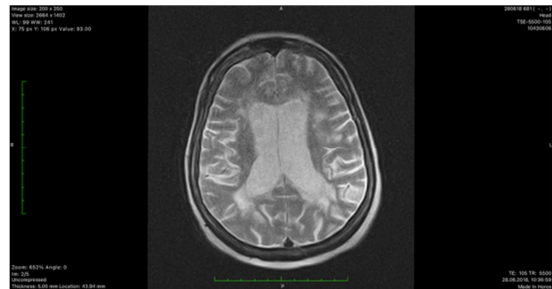
Figures 2-7: Ventriculomegaly, first noticed on a CT scan from 18 Apr 1998 (according to the radiologist's report), has progressed over the years.



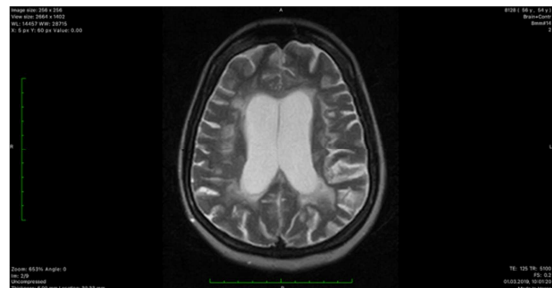**Figure 2.** 08 Oct 2011 MRI T2 Axial plane.



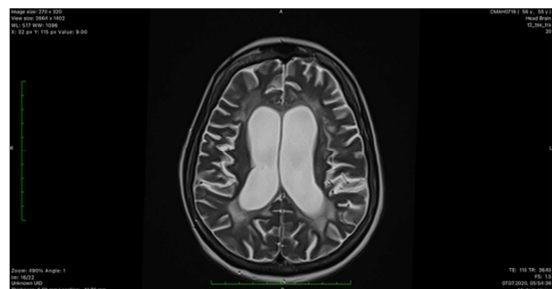
**Figure 3.** 15 Dec 2017 MRI T2 Axial plane.



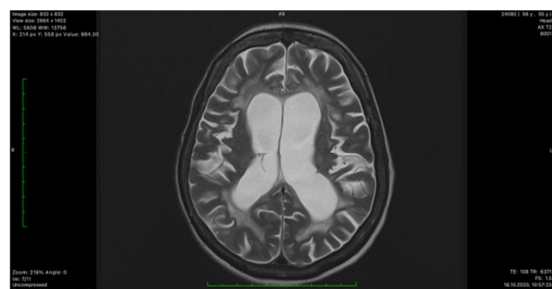
**Figure 4.** 28 Jun 2018 MRI T2 Axial plane.



**Figure 5.** 03 Jan 2019 MRI T2 Axial plane.

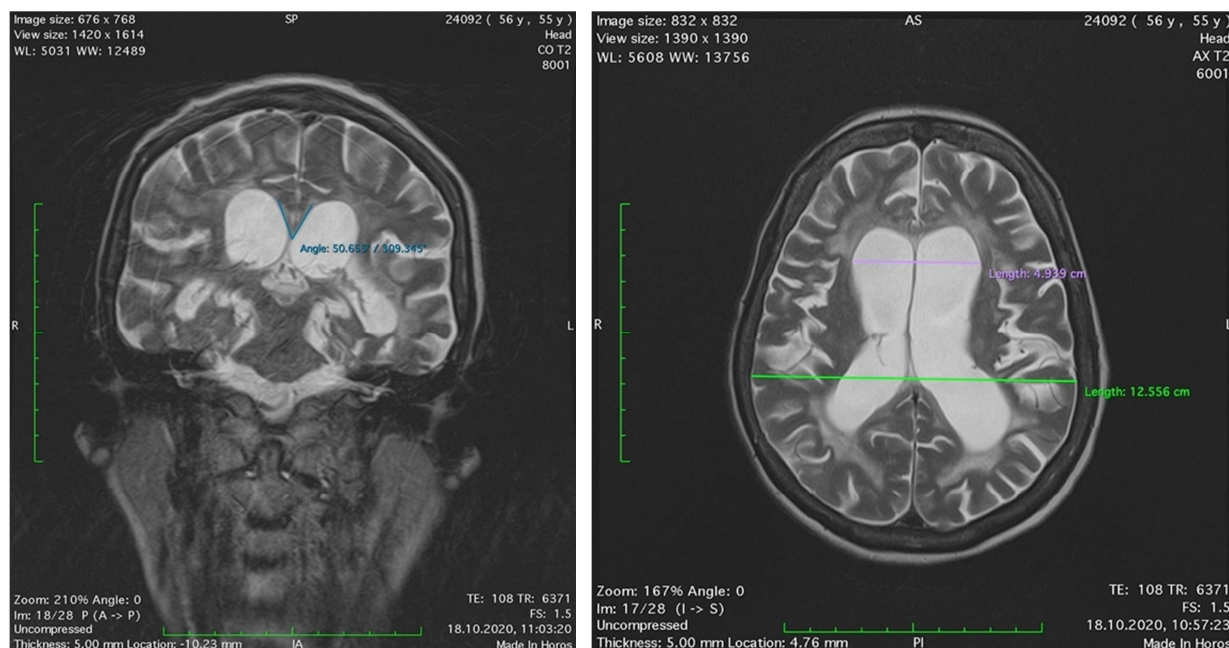


**Figure 6.** 07 Jul 2020 MRI T2 Axial plane.



**Figure 7.** 18 Oct 2020 MRI T2 Axial plane.

A detailed review of the patient's neuroimaging data has been done (Figure 8).



**Figure 8.** According to MRI from 19 Oct 2021: Evans index = 0.393; callosal angle at the level of the posterior commissure = 59.986°. A narrow subarachnoid space is visualized along the midline in convex areas, and there is an increase in the Sylvian furrow bilaterally. These signs correspond to the parameters of normotensive hydrocephalus [3]. Along with this, there is significant atrophy of the hippocampus.

## 2.4. Tap Test

To confirm the diagnostic assumptions, it was decided to conduct a "tap test" [4-5]. Before performing a lumbar puncture, specific tests had been done as a part of the protocol for diagnosing normal pressure hydrocephalus (NPH) [2-3, 6-8] to objectify potential changes in the patient's condition after the tap test. The patient could not perform the Timed Up and Go (TUG) test and short-distance straight walking test due to severe gait disturbance and inability to walk without support. MMSE was 10 points. The lumbar puncture was performed, and the clear cerebrospinal fluid was obtained, which flew out slowly (in general, 30 ml of cerebrospinal fluid was collected). Cerebrospinal fluid was sent to the laboratory for general analysis of cerebrospinal fluid, and oligoclonal antibodies with types of synthesis. A blood test was taken to determine whether IgM and IgG to *Treponema pallidum* are present. The TUG test,

short-distance straight walking test, and MMSE were carried out just after the diagnostic puncture, 24 hours after, 3 days after and 1 week after the diagnostic puncture – there weren't found any positive changes in the patient's neurological status, while positive diagnostic sign after tap test should had been the improvement of the patient's condition. Overall, in a patient with normal pressure hydrocephalus (NPH), changes are most quickly visible in the gait improvement [3].

## 2.5. Cerebrospinal Fluid Examination

The results of laboratory methods of examining the cerebrospinal fluid revealed the presence of oligoclonal bands in the cerebrospinal fluid (Table 1) (and their absence in blood serum), 2 type of intrathecal antibodies synthesis. No significant changes were found in the clinical analysis of the cerebrospinal fluid (Table 2). IgM and IgG to *Treponema pallidum* by the ELISA method were not detected (Table 3).

**Table 1.** Results of the cerebrospinal fluid analysis for the detection of oligoclonal bands.

Investigation	Result	Unit	Reference range
Albumin (CSF)	105	mg/L	35-52
Albumin (serum)	↓ 30.1	g/L	
Albumin quotient	3.5		
IgG (CSF)	16.2	mg/L	7-16
IgG (serum)	↓ 6.20	g/L	
IgG quotient	2.6		
Oligoclonal bands in the CSF	positive		
Oligoclonal bands in the serum	negative		
Summary	Oligoclonal bands in the CSF, not detected in serum; Type II (IEF). Interpretation: Intrathecal IgG synthesis. No evidence of a blood/liquor barrier disorder. Detection of intrathecal immunoglobulin synthesis in the quotient diagram. Production of oligoclonal IgG in the CSF (IEF).		



**Table 2.** Clinical analysis of the CSF.

General analysis of cerebrospinal fluid (CSF)	Result	Unit of measurement	Reference range
Number	4.0	Jr	
Specific density	↑ 1.014		1.006 - 1.007
Reaction (pH)	↑ 8.4		7.3 - 7.5
Color	greyish		colorless
Transparency	partly cloudy		transparent
Protein	0.231	g/L	0.12 - 0.33
Glucose	3.0	mmol/L	2.0 - 4.18
Chlorides	↓ 108.6	mmol/L	118 - 132
Leukocytes	4	number of elements in MKN	1 - 8
Erythrocytes	5	number of elements in MKN	absent

**Table 3.** Blood tests for detection of IgM and IgG to *Treponema pallidum*.

Immunology - ELISA	Result	Unit	Reference interval
Treponema pallidum, IgM antibodies	0.34	R	< 0.8 – negative result 0.85 – 1.1 – doubtful result > 1.1 – positive result
Treponema pallidum, IgG antibodies	0.76	R	< 0.9 – negative result 0.9 – 1.1 – doubtful result > 1.1 – positive result

### 3. Discussion

Normal pressure hydrocephalus (NPH) or Hakim-Adams syndrome is a chronic disorder of fluid dynamics manifested by a significant expansion of the ventricular system but is not accompanied by an increase in intracranial pressure. NPH can be either primary, idiopathic, or secondary – due to subarachnoid hemorrhage, meningitis, craniocerebral trauma, intracranial surgery, or neuroinfection. The disease is characterized by a triad: gait disturbance, dementia, and dysfunction of the pelvic organs in combination with ventriculomegaly on CT/MRI. An important feature of these symptoms is their slow progression, sometimes a wave-like course, including the presence of periods of exacerbation and relative well-being. Diagnosis of the disease is based on relatively specific radiological signs and a "tap test". Lumbar puncture with moderate-to-large amount of cerebrospinal fluid collection has a sensitivity of 58% (26–87%) and a specificity of 75% (33–100%), as reported in systematic reviews [5]. The only treatment for this pathology is the placement of a ventricular shunt [9-11]. Specific findings from the patient's history may indicate a likely etiology, including subarachnoid hemorrhage, meningitis, head trauma, congenital hydrocephalus, and stenosis of the aqueduct of Sylvius. The SINPHONI study demonstrated the value of DESH parameters for brain imaging, i.e., ventriculomegaly (Evans index [EI]  $\geq 0.3$ ), together with a narrow subarachnoid space near the midline on convexital surfaces and enlarged Sylvian sulci, which are signs of impaired CSF dynamics in the subarachnoid space, combined with the classic triad of symptoms in the diagnosis of normal pressure hydrocephalus (NPH) [3, 11-12].

On the other hand, in addition to immune-mediated demyelination of nerve fibers, according to research data, it is known that inflammation is also the cause of axonal degeneration of nerve cells and cortical atrophy in the

pathogenesis of multiple sclerosis itself [13-14]. This provides an understanding of the pathogenesis of atrophy of the brain, a significant cognitive and neurological deficit, which is not easy to exclude if considering the duration of the patient's illness and the lack of adequate disease-modifying therapy [15].

But forasmuch as the signs of ventriculomegaly were radiologically found much before any clinical signs and prior to the trauma, it was the right decision to suspect normal pressure hydrocephalus in this patient.

Even though the "tap test" did not show significant changes in the patient's neurological status, given the presence of Hakim's clinical triad and radiological quantitative and qualitative indicators (Evans index [EI]  $\geq 0.3$ , callosal angle < 100, narrow subarachnoid space on the convexity surface brain, enlargement of Sylvian furrows), according to the recommendations for the management of patients with normal pressure hydrocephalus (NPH), we cannot deny the diagnosis of probable hydrocephalus. In addition, according to the literature, the frequency of false-negative "tap tests" increases directly proportionally with the duration of the disease. According to the recommendations, there is no evidence of the need to repeat the "tap test" or lumbar drainage [3, 16]. Verifying or ruling out the diagnosis of NPH only after conducting ventricular shunting is possible.

As per confirmation of the diagnosis of multiple sclerosis by the detection of oligoclonal bands, II type of intrathecal antibody synthesis, the patient was discharged with a confirmed diagnosis of multiple sclerosis, secondary progressive course, atypical variant with the presence of pronounced cognitive deterioration to the stage of dementia, impaired motivation, self-care and urinary function control, 8 points in EDSS. The patient was recommended highly active drug therapy of multiple sclerosis - ocrelizumab, guidelines for rehabilitation methods, and cognitive exercises. According to the recommendations for the management of patients with normal pressure hydrocephalus (NPH) regardless of the

negative "tap test", the patient was recommended ventricular bypass [3, 17]. But considering the duration of clinical and radiological symptoms of the disease (>20 years) and the presence of massive foci of white matter lesions according to MRI data, the probability of an insufficient effect from the intervention is high [18]. Data from the literature [19-22] shows a negative correlation between foci of brain white matter atrophy and clinical improvement after cerebrospinal fluid drainage. In addition, in the opinion of fellow neurosurgeons, considering the duration of atrophic changes in the brain tissue, the risks of intracranial hemorrhage due to damage of the bridging veins after resorption/elimination of hydrocephalus are high.

All possible positive effects and negative aspects of ventricular shunting have been explained to the patient's relatives. Their decision is awaited.

## 4. Conclusions

Older patients with neurodegenerative diseases are often underdiagnosed because neurovisual signs of normal pressure hydrocephalus (NPH) are difficult to distinguish from unspecific cerebral atrophy. Moreover, symptoms of cognitive decline, gait disturbance, and urinary incontinence are more often attributed to nonspecific causes in the elderly in general and patients with multiple sclerosis in particular. Zarey and colleagues described six cases [23] in which the diagnosis of multiple sclerosis manifested exclusively with a cognitive/neuropsychiatric syndrome. Dementia in these patients had both cortical signs (dysphasia, dysgraphia, dyslexia) and subcortical signs (psychomotor degradation, problems with mood, relative preservation of language, calculation, discrimination of objects and problems with memory, which are best manifested when trying to repeat phrases or words). Disability in these patients was due to dementia. Bowel and bladder dysfunction appeared later on. This course of the disease may be one of the variants of multiple sclerosis, but due to its masks, such as senile dementia, Alzheimer's disease, and normal pressure hydrocephalus (NPH), it mostly remains outside the attention of clinicians.

When studying each case of a neurological disease, it is possible to find ambiguous clinical and radiological findings, which must be considered since not all of them lie in the pathogenesis of a single disease. Mentions of two verified independent diagnoses of MS and NPH in one patient are not common in the literature: the case of a 28-year-old patient was described by Oktay Algin and colleagues; 2 patients by O'Brien T. and colleagues [24-25].

The validity of the diagnosis and surgical treatment brought significant relief in the lives of these patients and their families. Considering our clinical case, one cannot reject the atypical course of MS caused by the prevalence of cognitive disorders with pronounced cortical atrophy and disability due to significant dementia. Nevertheless, it is essential to thoroughly diagnose a patient with multiple sclerosis with ventriculomegaly and clinical manifestations corresponding to Hakim's triad because the combination of two diseases - MS

and NPH - is not excluded [24-25]. Moreover, normal pressure hydrocephalus (NPH) has been considered a form of "dementia that could be treated". This fact should especially motivate clinicians to increase diagnostic vigilance in this direction. The placement of a ventricular shunt dramatically solves the problem in a patient with MS with a confirmed diagnosis of normal pressure hydrocephalus (NPH), but, of course, it does not eliminate the symptoms primarily caused by foci of multiple sclerosis. Advances in the non-invasive establishing the diagnosis of the disease are the study of biological markers of NPH and the use of PET-CT, which are promising and will probably contribute to the higher diagnostic rate of this pathological process [26-28].

## References

- [1] Goldenberg MM (2012). Multiple sclerosis review. *P & T: a peer-reviewed journal for formulary management*, 37 (3), 175–184.
- [2] Clinical significance of cerebrospinal fluid tap test and magnetic resonance imaging/computed tomography findings of tight high convexity in patients with possible idiopathic normal pressure hydrocephalus. Ishikawa M, Oowaki H, Matsumoto A, Suzuki T, Furuse M, Nishida N *Neurol Med Chir (Tokyo)*. 2010; 50 (2): 119-23; discussion 123.
- [3] Guidelines for Management of Idiopathic Normal Pressure Hydrocephalus (Third Edition): Endorsed by the Japanese Society of Normal Pressure Hydrocephalus PMID: PMC7905302 PMID: 33455998.
- [4] The clinical effect of lumbar puncture in normal pressure hydrocephalus. Wikkelsø C, Andersson H, Blomstrand C, Lindqvist GJ *Neurol Neurosurg Psychiatry*. 1982 January; 45 (1): 64-9.
- [5] CSF tap test - Obsolete or appropriate test for predicting shunt responsiveness? A systemic review. Mihalj MJ *Neurol Sci*. 2016 Nov 15; 370 (): 157.
- [6] A systematic review of the diagnostic utility of simple tests of change after trial removal of cerebrospinal fluid in adults with normal pressure hydrocephalus. Scully AE, Lim ECW, Teow PP, Tan DML *Clin Rehabil*. 2018 July; 32 (7): 942-953.
- [7] Early and delayed assessments of quantitative gait measures to improve the tap test as a predictor of shunt effectiveness in idiopathic normal pressure hydrocephalus. Ishikawa M, Yamada S, Yamamoto K *Fluid Barriers CNS*. 2016 Nov 22; 13 (1): 20.
- [8] Objective assessment of gait in normal-pressure hydrocephalus. Williams MA, Thomas G, de Lateur B, Imteyaz H, Rose JG, Shore WS, Kharkar S, Rigamonti D *Am J Phys Med Rehabil*. 2008 January; 87 (1): 39-45.
- [9] Idiopathic normal pressure hydrocephalus: diagnostic and predictive value of clinical testing, lumbar drainage, and CSF dynamics. Mahr CV, Dengl M, Nestler U, Reiss-Zimmermann M, Eichner G, Preuß M, Meixensberger J *J Neurosurg*. 2016 Sep; 125 (3): 591-7.
- [10] Diagnosis and management of idiopathic normal-pressure hydrocephalus: a prospective study in 151 patients. Marmarou A, Young HF, Aygok GA, Sawauchi S, Tsuji O, Yamamoto T, Dunbar J *J Neurosurg*. 2005 June; 102 (6): 987-97.

- [11] Lumboperitoneal shunt surgery for idiopathic normal pressure hydrocephalus (SINPHONI-2): an open-label randomized trial. Kazui H, Miyajima M, Mori E, Ishikawa M, SINPHONI-2 Investigators. *Lancet Neurol*. 2015 June; 14 (6): 585-94.
- [12] Kubo Y, Kazui H, Yoshida T, Kito Y, Kimura N, Tokunaga H, Ogino A, Miyake H, Ishikawa M, Takeda M. Validation of grading scale for evaluating symptoms of idiopathic normal-pressure hydrocephalus. *Dement Geriatr Cogn Disord*. 2008; 25 (1): 37-45. doi: 10.1159/000111149. Epub 2007 Nov 20. PMID: 18025828.
- [13] Immunology of multiple sclerosis. Mireia Sospedra and Roland Martin *Annual Review of Immunology* 2005 23: 1, 683-747.
- [14] Siffrin V, Vogt J, Radbruch H, Nitsch R, Zipp F. Multiple sclerosis—candidate mechanisms underlying CNS atrophy. *Trends Neurosci*. 2010; 33: 202–10.
- [15] Nancy D Chiaravalloti, John DeLuca, Cognitive impairment in multiple sclerosis, *The Lancet Neurology*, Volume 7, Issue 12, 2008, Pages 1139-1151, ISSN 1474-4422.
- [16] The value of temporary external lumbar CSF drainage in predicting the outcome of shunting on normal pressure hydrocephalus. Walchenbach R, Geiger E, Thomeer RT, Vanneste JA *J Neurol Neurosurg Psychiatry*. 2002 April; 72 (4): 503-6.
- [17] Normal pressure hydrocephalus: vascular white matter changes on MR images must not exclude patients from shunt surgery. Tullberg M, Jensen C, Ekholm S, Wikkelsø C *AJNR Am J Neuroradiol*. 2001 October; 22 (9): 1665-73.
- [18] The European iNPH Multicentre Study on the predictive values of resistance to CSF outflow and the CSF Tap Test in patients with idiopathic normal pressure hydrocephalus. Wikkelsø C, Hellström P, Klinge PM, Tans JT, European iNPH Multicentre Study Group. *J Neurol Neurosurg Psychiatry*. 2013 May; 84 (5): 562-8.
- [19] Normal-pressure hydrocephalus: white matter lesions correlate negatively with gait improvement after lumbar puncture Paulo Bugalho I, Luisa Alves Affiliations expand PMID: 17768003 DOI: 10.1016/j.clineuro.2007.07.012.
- [20] Cerebrospinal fluid shunting in idiopathic normal-pressure hydrocephalus of the elderly: effect of periventricular and deep white matter lesions. Krauss JK, Droste DW, Vach W, Regel JP, Orszagh M, Borremans JJ, Tietz A, Seeger W *Neurosurgery*. 1996 August; 39 (2): 292-9; discussion 299-300.
- [21] Amyloid deposits and response to shunt surgery in idiopathic normal-pressure hydrocephalus. Hiraoka K, Narita W, Kikuchi H, Baba T, Kanno S, Iizuka O, Tashiro M, Furumoto S, Okamura N, Furukawa K, Arai H, Iwata R, Mori E, Yanai KJ *Neurol Sci*. 2015 Sep 15; 356 (1-2): 124-8.
- [22] Sastre-Garriga J, Ingle GT, Chard DT, Cercignani M, Ramio -Torrentà L, Miller DH, Thompson AJ. Gray and white matter atrophy in early clinical stages of primary progressive multiple sclerosis. *Neuroimage*. 2004; 22: 353–9.
- [23] Cognitive presentation of multiple sclerosis: evidence for a cortical variant. M Zarei, S Chandran, A Compston, J Hodges.
- [24] Unusual Patient with Multiple Sclerosis and Shunt-Responsive Normal-Pressure Hydrocephalus Article in *Clinical Neuroradiology* April 2011 DOI: 10.1007/s00062-011-0068-3 Source: PubMed doi: 10.2176/nmc.st.2020-0292. Epub 2021 Jan 15.
- [25] Apparent hydrocephalus and chronic multiple sclerosis: a report of two cases. O'Brien T, Paine M, Matotek K, Byrne E, Author information *Clinical and Experimental Neurology*, 01 Jan 1993, 30: 137-143 PMID: 7712624.
- [26] Early evaluation of cerebral metabolic rate of glucose (CMRglu) with 18F-FDG PET/CT and clinical assessment in idiopathic normal pressure hydrocephalus (INPH) patients before and after ventricular shunt placement: preliminary experience. Calcagni ML, Lavalle M, Mangiola A, Indovina L, Leccisotti L, De Bonis P, Marra C, Pelliccioni A, Anile C, Giordano A *Eur J Nucl Med Mol Imaging*. 2012 February; 39 (2): 236-41.
- [27] F-FDG PET-CT pattern in idiopathic normal pressure hydrocephalus. Townley RA, Botha H, Graff-Radford J, Boeve BF, Petersen RC, Senjem ML, Knopman DS, Lowe V, Jack CR Jr, Jones DT *Neuroimage Clin*. 2018; 18: 897-902.
- [28] Idiopathic normal-pressure hydrocephalus: pathophysiology and diagnosis by CSF biomarkers. Jeppsson A, Zetterberg H, Blennow K, Wikkelsø C *Neurology*. 2013 Apr 9; 80 (15): 1385-92.