



Case Report

A Case of Severe Necrotizing Enterocolitis with High-Frequency Oscillatory Ventilation-Assisted Breathing Anesthesia Experience Sharing

Lin Song, Xuejie Li*

Department of Anesthesiology, West China Hospital, Sichuan University and the Research Units of West China (2018RU012), Chinese Academy of Medical Sciences, Chengdu, China

Email address:

songlin202307@163.com (Lin Song), lizuima@hotmail.com (Xuejie Li)

*Corresponding author

To cite this article:

Lin Song, Xuejie Li. (2023). A Case of Severe Necrotizing Enterocolitis with High-Frequency Oscillatory Ventilation-Assisted Breathing Anesthesia Experience Sharing. *American Journal of Pediatrics*, 9(4), 231-234. <https://doi.org/10.11648/j.ajp.20230904.17>

Received: November 24, 2023; **Accepted:** December 8, 2023; **Published:** December 18, 2023

Abstract: We report a case of a 27-week premature infant with necrotizing enterocolitis 28 days postpartum who underwent high-frequency oscillation-assisted ventilation anesthesia during surgery. Children born after the whole body's skin is blue, spontaneous breathing is weak, with a sigh breath, limb soft, oxygen desaturation under endotracheal intubation-assisted ventilation into the NICU. On the 20th day after the birth of children, abdominal distension sign of progression, merger, NEC. 22 days after birth oxygen saturation fluctuations in 80% to 90%, blood gas analysis in children with prompt acidosis is obvious, to correct acidosis, baking soda, at the same time with PaCO₂ prompt rise obviously, sputum, mechanical ventilation has been unable to maintain oxygenation, has been into high-frequency respirator assisted ventilation, respiratory frequency of 9 HZ, sputum suction, abdominal X-ray signs of intestinal obstruction, pediatric surgical consultation to laparotomy. Visit poor children to see children before anesthesia, bronze skin, through the mouth insert 3.5 endotracheal intubation mechanical assisted ventilation, abdominal plain film hint of peng of the children with abdominal significantly, abdominal veins, visible gastrointestinal type, high tension. Breathing machine Chang Pin ventilation by putting the children into the operating room, home bed immediately after connecting high-frequency ventilation, line ECG noninvasive arterial blood pressure SPO₂ (onset of each one) percutaneous CO₂ monitoring temperature monitoring of cerebral oxygen saturation monitoring. Intraoperative heat preservation, blood transfusion, and rehydration, sputum suction strong heart, in order to maintain stable hemodynamics and adjust the internal environment stable. The operation lasted only 38 minutes, safely back to NICU, put the patient on the evening the postoperative respiratory machine model had a high-frequency mode to Chang Pin auxiliary breathing machine, the second day postoperatively, children with open and body moving, stopped using positive inotropic drugs, continue to have a breathing machine auxiliary breath, at the same time strengthen parenteral nutrition support and anti-infection treatment, postoperative 3 months into the common ward, five months after hospital discharge. High-frequency oscillatory ventilation provides a new respiratory support method for newborns suffering from necrotizing enterocolitis, especially premature infants, and also buys valuable time for their subsequent treatment.

Keywords: Neonatal Necrotizing Enterocolitis, High-Frequency Oscillatory Ventilation, Anesthesia Management

1. Introduction

Neonatal necrotizing enterocolitis [1-3], the neonatal period is a kind of special intestinal inflammation necrotic disease, due to hypoplasia of the intestinal wall by blood vessels,

mucous membrane, metabolism, and other unknown factors combination of stimulation, causes serious bowel injury end-stage performance, characterized by the intestinal mucosa, and even for the depth of bowel necrosis. Its pathogenesis is not yet fully understood, the case fatality rate is 15% ~ 50%, and in severe NEC, extremely low birth weight, and need

higher fatality rate in patients with surgical treatment of NEC. NEC especially in premature infants, especially below 1500 g it's easy to have a very low birth weight.

The pointer is NEC surgery including 1. Absolute pointer: celiac-free gas, namely the digestive tract perforation; 2. Peritonitis signs; 3. Internal medicine conservative treatment after the disease continues to deteriorate, acidosis can't correct, shock, etc., also need surgery [4-6].

High-frequency ventilation by high-frequency piston pump a small amount of gas pumping and the principle of the airway can be taken out for ventilation, this way can reduce the pressure fluctuation in the airway, can raise more alveolar lung in a state of uniform air and suitable capacity, improve the body oxygenation effect is obvious, and has lower airway pressure and intrathoracic pressure [7-10]. Pediatric patients mainly use high-frequency oscillatory ventilation (HFOV), frequency is 500-3000 times/min, tidal volume for anatomical die cavity volume of 20% to 80%, can remove CO₂, not easily induce barotrauma, small tidal volume and the advantages of simple operation, fewer side effects, in recent years gradually become one of the preferred ventilation schemes of pediatric intensive treatment.

Preterm infants with necrotizing enterocolitis have extremely high mortality and poor prognosis due to poor cardiac reserve function and severe respiratory system disorders. However, advances in respiratory support methods, especially the widespread application of high-frequency oscillatory ventilation, have given these children a better chance of survival. We report a case of a 27-week premature infant with necrotizing enterocolitis 28 days postpartum who underwent high-frequency oscillation-assisted ventilation anesthesia during surgery.

2. Case Presentation

Children, female, age 28 days, because at 27 weeks premature, birth weight 810 grams, Apgar score 1-5-10 minutes respectively 1-5-10 points, after the birth of the whole body skin blue, spontaneous breathing is weak, with occasional sigh breath, limb soft, heart rate 78 beats/min, SPO₂ 52%, endotracheal intubation assisted ventilation past into the NICU. On the 20th day after the birth of children, abdominal distension sign of progression, the abdomen is obvious of peng, bowel sounds are abated, and blood stool, considering NEC. Illness alleviates not seen after conservative treatment, after the birth of 25 children with oxygen saturation fluctuations in 80% to 90%, blood gas analysis suggests acidosis, PaCO₂ prompt obviously increases, the increase in the number of sputum use breathing machine model for high-frequency ventilation, line abdominal X-ray plain film suggest signs of intestinal obstruction, combining with the current condition changes, contact a laparotomy was proposed line after pediatric surgical consultation. Preoperative diagnosis: 1. Low birth weight (810 g); 2. Super premature (27 weeks); 3. Neonatal respiratory distress syndrome; 4. NEC. 5. DIC. 6. Newborn pneumonia; 7. Intrauterine infection; 8. The digestive tract hemorrhage; 9. Subcutaneous ecchymosis. 10.

Neonatal edema; 11. The neonatal asphyxia; 12. The newborn pathological jaundice; 13. The neonatal anemia; 14. The tricuspid regurgitation; 15. Intestinal obstruction.

Supervision of children by the bed before anesthesia: premature children born for 28 days, weight 980 g, ECG monitoring: P: 190 times/min, NBP: 70/45 mmHg, SPO₂: 95%. Measuring blood sugar tendency for 6.4 L. Children with skin reaction, bronze, inserted through the mouth size 3.5 endotracheal intubation mechanical assisted ventilation, intubation depth of 6.5 CM. Double lung breath sounds crude, audible, and sputum song; Abdominal plain film hints of peng of the children with abdominal significantly, abdominal veins, visible gastrointestinal type, and high tension. The children with cycle stability, yet preoperative vascular active drug use yet. Because Chang Pin's mechanical ventilation has been unable to maintain oxygenation, she has been into high-frequency respirator assisted ventilation, with a respiratory frequency of 9 HZ. Routine blood tests: Hb 108 g/L, Hct 30.6%, Plt 83*10⁹/L, WBC 13.3*10⁹/L. Echocardiographic: patent foramen ovale, artery catheter is not closed, tricuspid regurgitation, EF69%. Blood gas analysis: PH 7.325, and PaCO₂ 58.5mmHg, PaO₂ 74.3 mmHg, BE 4.8mmol/L, HCO₃⁻ 26.3 mmol/L, K⁺ 3.7 mmol/L, 125 mmol/L for Na⁺, Glu for 6.1 mmol/L, hemoglobin 13.1 g/L, Lac for 3.6 mmol/L, SPO₂ 93.8%.

We optimize the general condition and internal environment of newborns through active communication with neonatologists before surgery. Communicate transport and intraoperative ventilation strategies with respiratory therapists, and plan to arrange high-frequency ventilation ventilators in advance. Communicate with the surgeon about the surgical plan and the estimated time of operation, and prepare blood products before the operation. On the day of surgery, the anesthesiologist, the neonatal team, and the respiratory therapist transferred the child to the operating room with regular ventilation by the transport ventilator. After entering the bed, the patient was immediately connected with high-frequency ventilation at a frequency of 9HZ. In order to avoid excessive temperature fluctuation of children during the perioperative period, the operating room temperature was increased while the body temperature was monitored, combined with a heat preservation blanket and infusion heating. Invasive blood pressure monitoring was established through the femoral artery after intravenous administration of high-dose fentanyl (10ug) + Cis-atrazine (2mg) anesthesia induction. Continued anesthesia with fentanyl and muscle relaxants. At the same time, 5% glucose (3ml/h), white red blood cell suspension (6ml/h), epinephrine (0.03ug/kg/min), and dopamine (5ug/kg/min) were pumped. During the operation, blood pressure dropped significantly during the operation of laparotomy and intestinal tube clearing, the infusion speed of white red blood cell suspension was immediately increased, and epinephrine was increased to 0.1ug/kg/min. Given 0.3ml 10% calcium gluconate, three inflammatory perforations with necrosis were observed in the whole digestive tract, complete necrosis of the ileocecal part and whole ascending colon, adhesion, and torsion of the perforated necrotic intestine with pus

formation, complete adhesion and obstruction of the proximal intestine. During the operation, a large amount of fluid continued to permeate and bleed, and the maximum amount of fluid after laparotomy reached 33ml/kg. Intraoperative oxygen saturation fluctuated greatly, ranging from 77% to 96%. There was a lot of sputum in the tracheal catheter, and repeated suction was performed during the operation. The operation took just 38 minutes. After the operation, the child returned to the NICU, and the ventilator mode changed from high-frequency mode to permanent frequency ventilator-assisted breathing on the night after the operation. On the second day after the operation, the child opened his eyes and moved his body, stopped positive inotropic drugs, and continued to receive invasive ventilator-assisted breathing, anti-infection, vitamin K1 to prevent bleeding, intravenous nutrition, and heat preservation. He was transferred to a general ward three months after surgery and discharged five months after surgery.

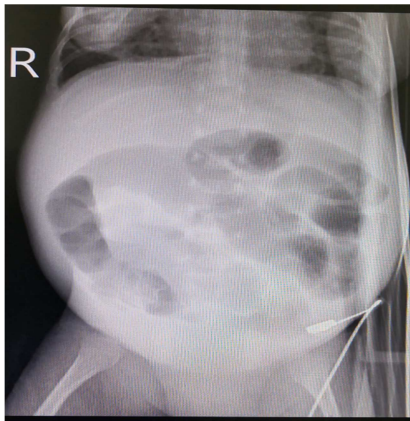


Figure 1. Children with preoperative abdominal plain radiographs indicate signs of intestinal obstruction.

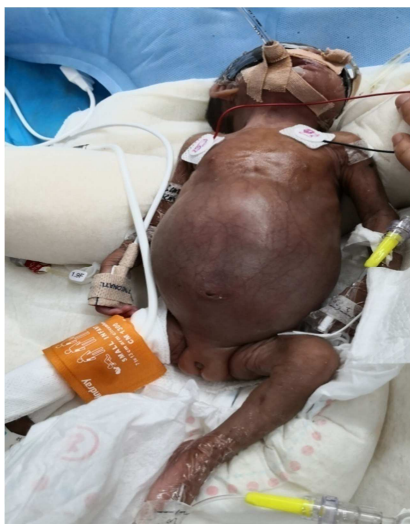

Figure 2. For children with abdominal peng, veins revealed abdominal wall.

3. Discussion

Along with the advance of premature treatment technology, premature mortality is declining, but also brings the rising

incidence of NEC. According to statistics, more than 30% of NEC children need surgery treatment [11].

Premature especially NEC of very low birth weight is often a very grave prognosis. On the one hand, premature cardiac reserve function is poor, tolerance difference of dramatic change. And premature babies often merge congenital heart disease [12], PDA, in particular, is often left to right shunt, but may be reversed. And children themselves effective circulating blood volume is limited, the redistribution of fluid state, the circulatory failure can occur easily, should pay close attention to children by monitoring means capacity status, avoid overloading circulation failure or cause pulmonary edema. Respiratory system, due to premature bronchial pulmonary dysplasia may exist, neonatal pneumonia is seen in airway secretions increase, respiratory function reserve is insufficient when severe abdominal distention limiting diaphragmatic muscle movement, tends to appear in children with respiratory distress, such as auxiliary ventilation without breathing machine, children with high case fatality rate [13]. The progress of respiratory support means, especially widely used in high-frequency oscillatory ventilation, also bring new life for these children. High-frequency oscillatory ventilation can remove CO₂ by it, not easily induce barotrauma, small tidal volume, and the advantages of simple operation, and fewer side effects, in recent years has gradually become the first selection of high-frequency ventilation. After many years of accumulation of experience, high-frequency oscillatory ventilation in pediatric intensive therapy has become one of the first choices of ventilation scheme, in ARDS, the treatment of diseases such as bronchial BPF, also gradually plays a more and more important role [14, 15].

4. Conclusion

According to the anesthesia management of this patient, our experience is as follows: Premature especially NEC is often a very grave prognosis of very low birth weight, anesthesia management is full of challenges. The anesthesia of NEC children often needs multilateral cooperation and communication, and making plans together. Perioperative respiratory circulation management should be closely monitored to maintain the stability of the internal environment, serious NEC children are likely to need a lot of blood transfusion and large doses of vascular active drugs; When normal breathing mode is still unable to maintain the patient's oxygen timeliness, consideration should be given in the high-frequency ventilation surgery under anesthesia. Under the HFOV line after general anesthesia operation, should be paid attention to: 1. Try to choose the largest diameter of the endotracheal tube for children ages; 2. Need to use the X-ray imaging examination confirms the endotracheal tube such as the position and the right lung capacity; 3. You need to do a percutaneous shout at the end of the carbon dioxide (Tc PCO₂) monitoring; 4. The inhalation anesthetics can't be used, but such children often already don't need them; 5. Caution: lung expansion excessively, gas leakage, intracranial hemorrhage, bradycardia, endotracheal sputum bolt, and hypotension.

ORCID

Lin Song: 0009-0009-4507-1578

Xuejie Li: 0000-0001-9706-3435

Conflicts of Interest

The authors declare no conflicts of interest.

References

- [1] Group E B M. Clinical guidelines for the diagnosis and treatment of neonatal necrotizing enterocolitis (2020) [J]. Zhongguo Dang dai er ke za zhi Chinese Journal of Contemporary Pediatrics, 2021, 23 (1): 1-11.
- [2] Cai X, Liebe H L, Golubkova A, et al. A Review of the Diagnosis and Treatment of Necrotizing Enterocolitis [J]. Current Pediatric Reviews, 2023, 19 (3): 285-295.
- [3] Müller M J, Paul T, Seeliger S. Necrotizing enterocolitis in premature infants and newborns [J]. Journal of neonatal-perinatal medicine, 2016, 9 (3): 233-242.
- [4] Munaco A J, Veenstra M, Brownie E, et al. Timing of optimal surgical intervention for neonates with necrotizing enterocolitis [J]. The american surgeon, 2015, 81 (5): 438-443.
- [5] De Bernardo G, Sordino D, De Chiara C, et al. Management of NEC: Surgical Treatment and Role of Traditional X-ray Versus Ultrasound Imaging, Experience of a Single Centre [J]. Current Pediatric Reviews, 2019, 15 (2): 125-130.
- [6] Van Heesewijk A E, Rush M L, Schmidt B, et al. Agreement between study designs: a systematic review comparing observational studies and randomized trials of surgical treatments for necrotizing enterocolitis [J]. The Journal of Maternal-Fetal & Neonatal Medicine, 2020, 33 (12): 1965-1973.
- [7] Miller A G, Bartle R M, Rehder K J. High-frequency jet ventilation in neonatal and pediatric subjects: a narrative review [J]. Respiratory Care, 2021, 66 (5): 845-856.
- [8] Elgin T G, Stanford A H, Klein J M. First intention high-frequency jet ventilation for periviable infants [J]. Current opinion in pediatrics, 2022, 34 (2): 165-169.
- [9] Ethawi Y H, Abou Mehrem A, Minski J, et al. High frequency jet ventilation versus high frequency oscillatory ventilation for pulmonary dysfunction in preterm infants [J]. Cochrane Database of Systematic Reviews, 2016 (5).
- [10] Wheeler C R, Smallwood C D, O'Donnell I, et al. Assessing initial response to high-frequency jet ventilation in premature infants with hypercapnic respiratory failure [J]. Respiratory Care, 2017, 62 (7): 867-872.
- [11] Carr B D, Gadepalli S K. Does surgical management alter outcome in necrotizing enterocolitis? [J]. Clinics in Perinatology, 2019, 46 (1): 89-100.
- [12] Lemons J A, Bauer C R, Oh W, et al. Very low birth weight outcomes of the National Institute of Child health and human development neonatal research network, January 1995 through December 1996 [J]. Pediatrics, 2001, 107 (1): E1.
- [13] Sweet D G, Carnielli V, Greisen G, et al. European consensus guidelines on the management of respiratory distress syndrome—2019 update [J]. Neonatology, 2019, 115 (4): 432-450.
- [14] Sánchez-Luna M, González-Pacheco N, Belik J, et al. New ventilator strategies: high-frequency oscillatory ventilation combined with volume guarantee [J]. American journal of perinatology, 2018, 35 (06): 545-548.
- [15] Miller A G, Tan H L, Smith B J, et al. The physiological basis of high-frequency oscillatory ventilation and current evidence in adults and children: a narrative review [J]. Frontiers in Physiology, 2022, 13: 808.