

Anesthetic Management of an Intrathoracic Fetus in Fetus Case in a 5 Months Old Infant at a Low Resources African Sub-saharan Hospital

Joseph Akodjènou^{1,*}, Abdel-Kémal Bori Bata², Antoine Séraphin Gbénou², Médard Guedenon², Morgiane Hounbadji³, Eulalie Sansuamou⁴, Maroufou Jules Alao³, Eugène Zoumènou¹, Jean Etienne Bazin⁵, Francis Veyckemans⁶

¹Resuscitation Anesthesia Department, Mother and Child Teaching Hospital Lagoon, Abomey-Calavi University, Cotonou, Benin

²Pediatric Surgery Department Mother and Child Teaching Hospital Lagoon, Abomey-Calavi University, Cotonou, Benin

³Pediatric Department, Mother and Child Teaching Hospital Lagoon, Abomey-Calavi University, Cotonou, Benin

⁴Radiology Department, Mother and Child Teaching Hospital Lagoon, Abomey-Calavi University, Cotonou, Benin

⁵Resuscitation Anesthesia Department, Estaing University Hospital Center, Clermont, Ferrand, France

⁶Resuscitation Anesthesia Department, Regional University Hospital Center, Lille, France

Email address:

josephakodjenou@yahoo.fr (J. Akodjènou)

*Corresponding author

To cite this article:

Joseph Akodjènou, Abdel-Kémal Bori Bata, Antoine Séraphin Gbénou, Médard Guedenon, Morgiane Hounbadji, Eulalie Sansuamou, Maroufou Jules Alao, Eugène Zoumènou, Jean Etienne Bazin, Francis Veyckemans. Anesthetic Management of an Intrathoracic Fetus in Fetus Case in a 5 Months Old Infant at a Low Resources African Sub-saharan Hospital. *American Journal of Pediatrics*. Vol. 7, No. 4, 2021, pp. 198-202. doi: 10.11648/j.ajp.20210704.13

Received: September 30, 2021; **Accepted:** October 19, 2021; **Published:** October 28, 2021

Abstract: Fetus in fetus (FIF) is an extremely rare congenital condition characterized by the parasitic development of a malformed fetal twin within a normal second twin's body. The localization is mostly abdominal in the retroperitoneum. Thoracic localization is extremely rare. In this clinical case, a 5 month old female infant weighing 5 kg presented with a chest mass causing respiratory distress. We realized a chest CT-Scan; the latter revealed a heterogeneous mass, completely occupying the left hemithorax. Imaging studies confirmed the presence of the fetus in fetus occupying the entire left hemithorax and mediastinum, pushing the heart to the right. A complete resection of the mass could be performed under general anesthesia and orotracheal intubation (GA + OTI). The monitoring involved ECG, SpO₂, NIBP, PR, T°, and Capnometry. The ventilation was first mechanical and secondarily manual. The patient did not receive unipulmonary ventilation nor central IV line. Postoperative period marked by volume overload, anemia, cardiac arrest, with successful resuscitation. Histopathology studies and imaging confirmed the diagnosis. On D9, she was discharged from pediatric critical care and from hospital on day ten postoperative. She presented in good clinical condition after a 3-month follow-up. We report this case in order to show how we took care of this FIF case in the precarious conditions.

Keywords: Fetus in Fetus, Chest Mass, Anesthetic Management, Infant

1. Introduction

Fetus in fetus is an extremely rare congenital condition characterized by the development of a parasitic malformed twin within a normal second twin's body [1]. The localization is mostly abdominal in the retroperitoneum. Nevertheless, some cases were found in the brain, mouth, cranium, neck,

mediastinum, liver, scrotum and even the sacrococcygeal region [2, 3].

Thoracic localization is extremely rare [4], with only six cases reported in the literature [5, 6]. In three of those, the mass was found in the mediastinum, another in lung parenchyma, in the left hemithorax, and in the anterior chest wall.

We are reporting here a case of intrathoracic mass, in a female five months old infant, evoking a fetus in fetus, which was managed in a low human, material and financial resources context at the Cotonou Mother and Child Teaching Hospital Lagoon (CHU-MEL) in Benin.

1.1. History

A five kgs 5 months old female infant referred from a clinic to the pediatric unit of CHU-MEL for 72 hours ongoing respiratory distress. She had past history of recurrent pulmonary infections since two months of life, this after a well followed pregnancy. Delivery done through cesarean section indicated for fetal distress, issuing birth of a 2600g female newborn with immediate cry and APGAR 9-10.

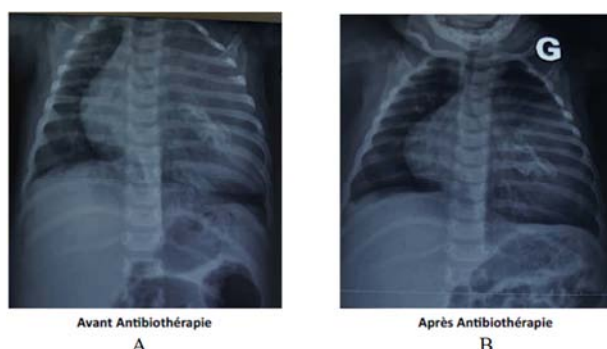


Figure 1. Chest X – ray.

Upon admission at the pediatric unit she presented a mild respiratory distress, RR=50cpm, SpO₂=94%, intercostal indrawing, nasal flaring, HR=137bpm, dullness and absence of breath sounds in the left lung field. Repeated chest radiographs revealed persistent opacity of the left hemithorax with skeleton like axial bony opacity, and rightward mediastinum deviation (Figure 1A, 1B). Chest ultrasound revealed an important free left pleural non-partitioned collection, and homolateral passive atelectasis. Biological workup evidenced anemia (10.3g/dL), polynuclear leukocytosis (25G/L), thrombocytosis (524G/L), elevated tumor markers like alpha-fetoprotein (AFP)=73.26ng/ml, βHCG=9.11mUI/ml, carcino-embryonic antigens (CEA)=4.29ng/ml. On awaiting a chest CT-Scan, the infant developed abrupt deterioration with clinical and radiological severe respiratory distress then indication of chest drainage (Figure 2). She was addressed to the pediatric surgery unit for urgent chest drainage.

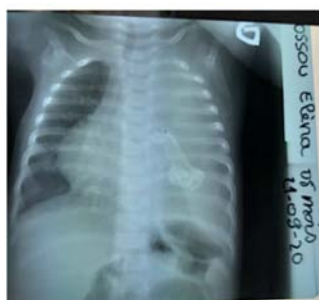

Figure 2. Image that motivated drainage.

Drainage done under general anesthesia with facial mask after Propofol induction; brought out 250ml of a clear fluid mixed with vernix caseosa like whitish substance (Figure 3). We realized a chest CT-Scan under better conditions after amelioration of respiratory distress with SpO₂ passing from 94% to 98% at room air. The latter revealed a heterogeneous mass, completely occupying the left hemithorax, with mass effect on the left superior lobe; hypertrophy of the homolateral inferior lobe and central bony opacity was also present (Figures 4-5). All this made the radiologists to evoke the diagnosis of fetus in fetus, congenital diaphragmatic hernia and iatrogenic bowel perforation by chest drain.

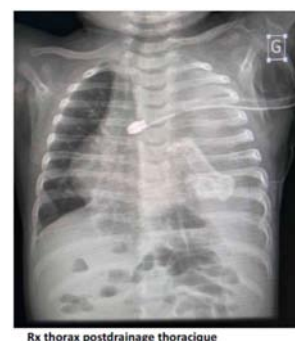

Figure 3. Post-drainage chest x-ray.

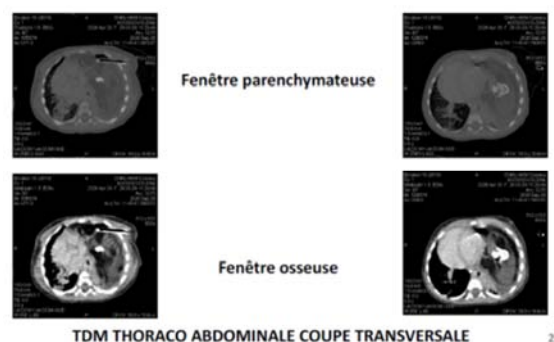


Figure 4. CT scan showing a lump in the left hemithorax.

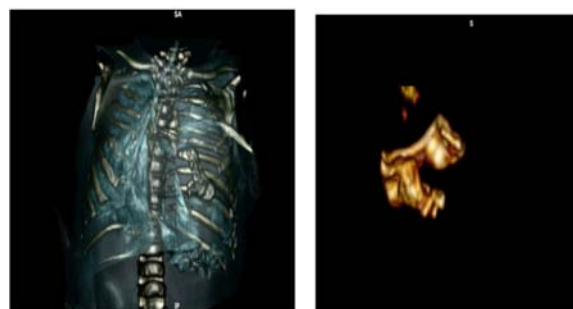


Figure 5. CT scan in video form showing mass centered by opacity of bone density.

The patient was admitted next day in the theater for left posterolateral thoracotomy. Standard monitoring used was ECG, SpO₂, NIBP, PR, Temperature, and capnometry.

Induction was done with Sufentanyl, Propofol, and Suxamethonium; orotracheal intubation with Hi-Contour® size 3.5-balloon tracheal tube after antibioprophylaxis with 75

mg of cefuroxime. We initially proceeded by mechanical ventilation with 50% FiO₂ for SpO₂ greater than 96%, Vt=30ml; I/E=1/2 and PEEP=03CmH₂O and right lateral decubitus. This was secondarily changed into manual ventilation FiO₂=80%, with small volumes during mass removal, all because of lack of special material for selective lung ventilation.

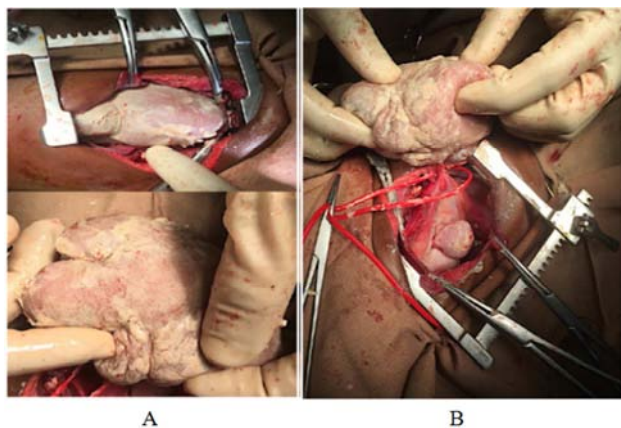


Figure 6. Left posterolateral thoracotomy with mass occupying the left hemithorax and mediastinum.

The left posterolateral thoracotomy revealed a completely occupying left hemithoracic and mediastinal mass, pushing the heart to the right (Figure 6A, 6B). The mass appeared covered with a membranous sac containing some clear fluid mixed with vernix caseosa. It presented a normal looking skin and vernix caseosa. The inferior pole presented three lobes similar to precursors of head and limbs, with others similar to organs on the internal face. It was attached to an umbilical cord-like unique vascular pedicle. Complete removal of a 170g mass was done, measuring 11*8*8cm (Figure 7). Complementary complete exeresis of a sessile mass of 1.5cm was also realized.

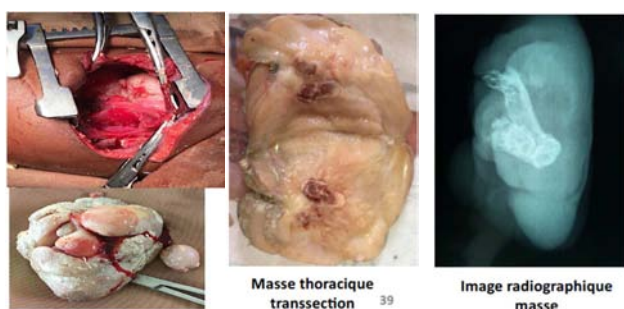


Figure 7. Image of the mass after excision.

Per operatively, we maintained narcosis with Sevoflurane, reinjections of Propofol and Sufentanyl. The patient received 150ml of packed red cells, with satisfactory hemodynamic state until the end of surgery.

The intervention lasted 5hours 08 minutes, followed by a transfer to pediatric critical care under mechanical ventilation and sedation with Midazolam and Sufentanyl through electric syringe (Figure 8).

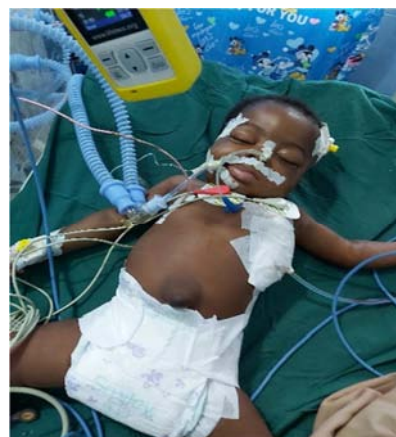

Figure 8. Image of patient under sedation in intensive care unit.

1.2. Care and Events in the Pediatric Critical Care Unit

Few hours after admission in the critical care unit, the patient presented fever at 38.5°C, facial swelling, right lung crackles with suspicion of volume overload, pallor and nasal flaring, managed with 70ml packed red cells transfusion and 5 mg of furosemide. Under this management, SpO₂ went from 98% to 78% at FiO₂ at 80%, HR dropped from 133bpm to 89bpm with subsequent hypoxic cardiorespiratory arrest due to obstruction by thick tracheal tube secretions and abrupt rupture of oxygen provision. We proceeded with oropharyngeal suctioning, sedation was stopped, manual ventilation initiated with self-inflating balloon, external chest compressions, then extubation and reintubation after return of oxygen. This led to cardiac activity recovery, and the patient remained hemodynamically stable under morphine 20mcg/kg bolus then 20mcg/kg/h through electric syringe and acetaminophen 15mg/kg q6hrs for post-operative pain management.

On day 4 post-operative, hemoculture isolated *E. coli* sensitive to amikacin, cefuroxime and metronidazole. Treatment was readjusted with amikacin 75mg q24hrs, cefuroxime 170mg q8hrs, metronidazole 75mg q12hrs, and 100ml/kg of daily fluids. Following evaluation of pain with Amiel Tison scale [7] of pain the patient was weaned off morphine and pain management continued with acetaminophen IV and ketoprofen 100mg suppository q24hrs.

On day 6 post-operative, extubaion and facial mask oxygenation with good ventilatory mechanic and absence of pathologic crackles; SpO₂ greater than 95% for 24hrs; chest drain and IV line removal; breast milk feeding, and oral antibiotics.

On day 9 post-operative, the patient was out of the critical care unit and discharged from the hospital on day 10 post-operative. The incomplete left lung expansion indicated respiratory physiotherapy sessions (Figure 9A, 9B).

Histopathologic studies on the mass revealed normal skin, adipose, muscular and vascular tissues, all centered by a structurally normal mature bone. It found no abnormal or undifferentiated tissues, no sign of malignancy, which raised the probability of a fetus in fetus. The child presented with a good clinical state after a 3 months follow-up.

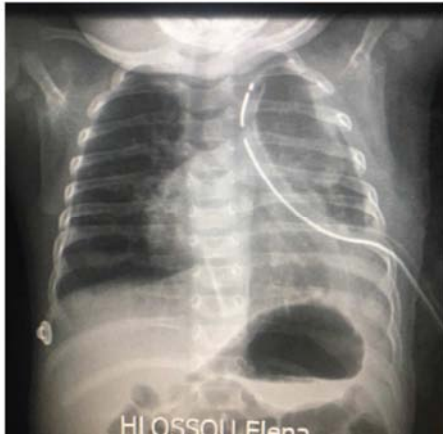

Figure 9. Chest x-ray 48 hours postoperatively.

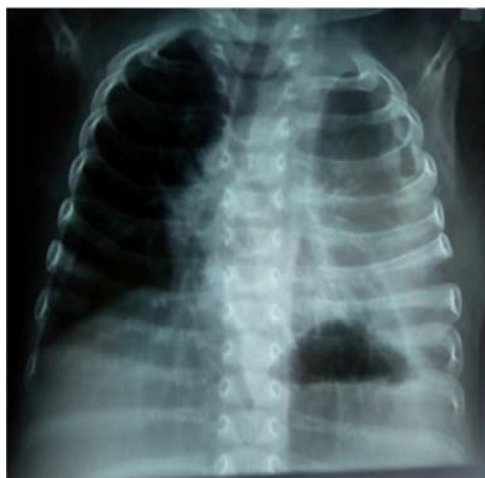

Figure 10. Chest x-ray 11th postoperative day.

2. Discussion

FIF results from abnormal embryogenesis of a diamniotic monochorial twin pregnancy leading to asymmetric division and abnormal anastomosis of vitelline circulation [3]. It is a rare condition with most of the cases diagnosed before 18 months of life and male prevalence [6]; the incidence is estimated at 1/500000 births [5].

The majority of cases present with the swallowed twin being anencephalic, with a vertebral column and limbs. The upper limbs less developed than the lower, are usually in the abdomen [8].

The pre-operative diagnosis is made by ultrasonography, radiography, CT-Scan or MRI. Histopathologic studies results confirm the diagnosis [5]. Our history presents a rare case of intrathoracic FIF.

Clinical symptoms of FIF are the result of surrounding organ compression by the mass (abdomen distension, feeding difficulties, vomiting, and rarely jaundice or respiratory distress), though it can remain asymptomatic [3, 5, 6]. Our patient presented with severe respiratory distress following recurrent lung infections and late admission because of the financial constraints and no health security. She became much better after chest drainage and mass removal.

FIF prenatal diagnosis is possible, but only 7% of published cases were diagnosed before birth [7]. Pre-operative diagnosis is done in 16.7% of cases. Chest radiographs guide the diagnosis when it shows axial skeleton, whereas CT-Scan and MRI confirm the diagnosis, evaluates limits and mass effects on surrounding organs [3, 4]. In our history, we realized a chest radiograph and a CT-Scan but no MRI realized because of its unavailability; per-operative diagnosis was made.

Clinic and pathologic features can be discussed while considering the differential diagnoses [3]. The differential diagnoses include neuroblastoma, FIF and teratoma [9]. Congenital neuroblastoma, usually presents with further involvement of skin, liver, or bone. Teratoma rarely arise in the retroperitoneum, compressing less than 5% of retroperitoneal masses, compared to FIF, which are most often observed in the retroperitoneal location [10]. Pathologically, FIF is highly differentiated tissue about a vertebral skeleton, whereas teratoma are discordant congregations of pleuripotential cells without systemic organization [11].

The anesthetic management of intrathoracic mass surgery in the infant, specifically which of FIF is rarely described. In our history, the mass was located in the thoracic region, thus necessitated a painful, potentially hemorrhagic surgery on the lateral position, for an unpredictable duration. In the absence of an adapted central venous catheter for a 5 months old infant, we used two peripheral IV lines. Likewise we couldn't put an arterial IV line for hemodynamic monitoring, and sampling for both ABGs and blood electrolytes due to lack of necessary material; the same as we couldn't even warm up the patient. Peri-operative monitoring involved ECG, SpO₂, capnography, PR, and temperature.

Post-operative phase must insure rapid autonomy recovery of the patient, which goes with both optimal pain control as much as post-operative rehabilitation programs.

In the past decade, increasing description of the genetic features of FIF have also been identified. In all reports, the karyotype of the FIF is identical to that of the host fetus [12]. Molecular genetic analysis using 10 STR (Short Tandem Repeat) markers has also shown that the genotypes of the FIF mass and the host infant are heterozygous and identical [13].

According to Spencer, FIF diagnosis confirmation must meet one or more of the following criteria [14]: (a) contained in a distinct sac with fluid or vernix caseosa; (b) partially or completely covered with normal skin; (c) have grossly recognizable anatomic parts; (d) attached to the host through one or many large vessels. Our clinical case responded to most of latter criteria. AFP, β -HCG and CEA can be normal or elevated [5, 15]. Genetic markers analysis, as blood group, karyotype, and DNA show no difference between host and FIF. The definitive diagnosis is histopathologic.

3. Conclusion

Our mass met Spencer's criteria, which, coupled to histopathologic studies results makes definitive diagnosis of intrathoracic FIF in a 5 months old infant, successfully managed in a limited resources hospital.

The anesthetic management involves deep narcosis, airway management and optimal per and post-operative pain control.

After three months follow-up, the patient presents a good clinical and biological state.

The perioperative complications mostly linked to the unavailability of oxygen, absence of health insurance, and last but not the least: lack of monitoring material in both the theater and the pediatric critical care unit.

Conflicts of Interest

The authors declare no conflicts of interest regarding the publication of this paper.

Acknowledgements

The authors wish to thank Miss FANDOHAN Joyce and NJITAM GASSAM Stéphane Brice for their contributions to the translation of this manuscript.

References

- [1] Sitharama SA, Jindal B, Vuriti MK, Naredi BK, Krishnamurthy S, Subramania DB. Fetus in Fetu: Case Report and Brief Review of Literature on Embryologic Origin, Clinical Presentation, Imaging and Differential Diagnosis. *Pol J Radiol*. 2017; 82: 46-49.
- [2] Lord JM. Intra-abdominal foetus in foetu. *J Pathol Bacteriol* 1956; 72: 627-41.
- [3] Lindsey M. Prescher, William J. Butler, Tyler A. Vachon, Marion C. Henry, Thomas Latendresse, Romeo C. Ignacio Jr. Fetus in fetu: Review of the literature over the past 15 years; *Journal of Pediatric Surgery CASE REPORTS, J Ped Surg Case Reports* 3 (2015) 554-562.
- [4] Reddy RK, Kannaiyan L, Srirampur S, Malleboyina R, Irfan GM, Sharab H, Kannepalli S. Thoracic fetus in fetu. *J Indian Assoc Pediatr Surg*. 2012; 17 (4): 178-9.
- [5] Hoeffel CC, Nguyen KQ, Phan HT, Truong NH, Nguyen TS, Tran TT, et al. Fetus in fetu: a case report and literature review. *Pediatrics* 2000; 105: 1335-44.
- [6] Phatak. Fetus-in-fetu: a case report. *Indian J Radiol Image* 2003; 13: 93-4.
- [7] Barrier G, Mayer MNB, Amiel-Tison C et al. Measurement of post-operative pain and narcotic administration in infants using a new clinical scoring system; *Intensive Care Med* 1989; 15: 37-9.
- [8] Escobar MA, Rossman JE, Caty MG. Fetus-in-fetu: report of a case and a review of the literature. *J Pediatr Surg* 2008; 43: 943-6.
- [9] Hing A, Corterville J, Foglia RB, Bliss Jr DP, Dollis – Keller H, Downton SB. fetus in fetu: molecular analysis of a fetiform mass. *Am J Med Genet* 1993; 47: 333-41.
- [10] Grosfeld JL, Stepita DS, Nance WE, Palmer CG. Fetus in fetu: An usually cause for abdominal mass in infancy. *Ann Surg* 1974; 180: 80-4.
- [11] Khadaroo RG, Evans MG, Honore LH, Bhargava R, Phillipos E. Fetus in fetu pressing as cystic meconium peritonitis: diagnosis, pathology, and surgical management. *J Pediatr Surg* 2000; 35: 731-3.
- [12] Chua JH, Chui CH, Sai Prasad TR, Jabcobsen, AS, Meenakshi A, Hwang WS. Fetus in fetu in the pelvis: report of case and literature review. *Ann Acad Med Singapour* 2005; 34: 646-9.
- [13] Kim JW, Park SH, Park SS, Wang KC, Cho BK, Kim SY, and al. Fetus in fetu in the cranium of a 4 month-old boy: histopathology and short tandem repeat polymorphism- based genotyping. Case report. *J Neurosurg Pediatr* 2008; 1: 410-4.
- [14] Spencer R. Parasitic conjoined twins: external, internal (fetuses in fetu and teratomas), and detached (acardiacs). *Clin Anat* 2001; 14: 428-44.
- [15] Ji Y, Chen S, Zhong L, Jiang X, Jin S, Kong F, Wang Q, Li C, Xiang B. Fetus in fetu: two case reports and literature review. *BMC Pediatr*. 2014; 14: 88.