

Case Report

Graves' Disease in Fourteen Years Old Girl

I Gusti Ayu Prema Yani Sidemen^{*}, I Made Arimbawa

Department of Child Health, Udayana University, Sanglah Hospital, Denpasar, Bali, Indonesia

Email address:

premasidemen@gmail.com (I G. A. P. Y. Sidemen), maderimawa@gmail.com (I M. Arimbawa)

^{*}Corresponding author**To cite this article:**I Gusti Ayu Prema Yani Sidemen, I Made Arimbawa. Graves' Disease in Fourteen Years Old Girl. *American Journal of Pediatrics*. Vol. 6, No. 4, 2020, pp. 476-480. doi: 10.11648/j.ajp.20200604.25**Received:** November 5, 2020; **Accepted:** November 18, 2020; **Published:** December 4, 2020

Abstract: Graves' disease (GD), an autoimmune disorder resulting from thyrotropin (TSH) receptor stimulation by autoantibodies, is an uncommon disease in children. The incidence of GD is thought to be rising and is currently about 0.1 per 100,000 person-years in young children to 3 per 100,000 person-years in adolescents. The estimated prevalence varies between countries, from 1/10,000 in the United States to 1/100,000 person-years (for children aged 0–15 years) in the UK and Ireland. We reported one female patient, 14 years old, complained neck lump accompanied by exophthalmos, palpitation especially at night, followed by easily sweating all over her body. That manifestation also followed by increased of appetite, sleep disturbance, agitated, and behavioural changes those affecting her school report. Physical examination revealed hypertension, tachycardia, proptosis of both eyes, a non-pain palpable soft diffuse symmetrical mass on front neck followed down when swallowing, a systolic murmur, sweating on palms and soles of the feet. Laboratory investigation was found FT4 >100,000 ng/dL (0.93-1.70); TSH_s <0.05 IU/mL (0.27-4.20); T3 Total 28.6 nmol/L; TRAb 36.5 IU/L (≤1.75) and an ECG result found sinus tachycardia. Patient was treated with thyrozol (thiamazole) and propranolol. We need to increase awareness to adverse event of antihyperthyroid drugs, remission rate, predictor factors in successful treatment to get a better long-term outcomes of medical therapy in Grave's disease.

Keywords: Graves' Disease, Hyperthyroidism, Thyrotoxicosis

1. Introduction

Graves' disease (GD), an autoimmune disorder resulting from thyrotropin (TSH) receptor stimulation by autoantibodies, is an uncommon disease in children, who account for only 1–5% of all patients with GD [1]. In adults, this disease affects approximately 2% of women and 0.2% of men. It accounts for about 15% of thyroid disorders during childhood and, like most other thyroid disorders in both adults and children, GD is much more frequent in female than in male subjects [1, 2]. It may occur at any age during childhood, but its frequency increases with age, peaking during adolescence. The incidence of GD is thought to be rising and is currently about 0.1 per 100,000 person-years in young children to 3 per 100,000 person-years in adolescents [1, 3]. The estimated prevalence varies between countries, from 1/10,000 in the United States to 1/100,000 person-years (for children aged 0–15 years) in the UK and Ireland. A frequency

of up to 14 per 100,000 patient-years has been reported in Hong Kong, and differences in the frequency of this condition do not seem to depend on dietary iodine intake. GD is more frequent in children with other autoimmune conditions, and in children with a familial history of autoimmune thyroid disease [2, 4].

Current treatment approaches include antithyroid drugs (ATDs), which are commonly used as the first-line treatment, or thyroid ablation with either radioactive iodine therapy or thyroidectomy [3, 5, 6]. Management of Graves' disease in childhood remains an important controversy in endocrinology because of the high rate of relapses when ATDs are used and because no single treatment modality consistently restores euthyroidism [7]. Although remission in adults is 40%-60%, these rates are less common in prepubertal and pubertal children, in whom remission occurs in 20%-30% and 15%, respectively [7, 8]. There are only a few studies focusing on prognostic factors in children and adolescents with Graves'

disease, and although a number of variables have been investigated to evaluate the risk of relapse, results still are inconclusive [9]. An older age, a greater body mass index (BMI) at diagnosis, a smaller goiter size, a greater initial dosage, and prolonged drug treatment are among the factors analyzed that correlate with a greater likelihood of remission. Therefore, children and adolescents usually undergo longer periods of drug treatment than adults, despite the absence of an evidence-based strategy for disease management [9, 10].

2. Case Report

A fourteen years old girl, referred from K District Hospital to our outpatient clinic, complained neck lump since 2 months before admitted to the hospital, then got worse since three days before admitted. The lump was located at front of the neck. At first it was enlarged at the right side, then diffused to the left side and finally made one big lump. There was no pain when patient swallowed or at any activity. Lump at any other site was denied. Voice changes, fever, and shortness of breath since lump enlarged were denied.

Exophthalmus were complained since 2 months before admitted, few days before neck lump appeared. There was stabbing pain at both eyes prior to the complaint. When the pain disappeared, her eyes started to goggled. The exophthalmus became worse 1 week before admitted. She felt uncomfortable with this condition since her friends at school scared of her. Redness on her eyes, blurred vision, and discharge from her eyes were denied.

Patient complained palpitation since 1 month before admitted. Palpitation was appeared all day and became worse at night. This complaint worse as time by and made her agitated. Pain in chest or radiating to the left arm were denied.

Patient got easily sweating all over her body since palpitation appeared, and either worse at night. Patient could not stay longer outside the house at day, she prefer stayed inside a cool room. She was complained to often changing clothes due to sweating a lot. She often complained her palms were sweating too, made her hard to do writing or handshaking.

Sleep disturbance happened since the last 6 months. Patient was said to tend moving around the bed, agitated, and being restless. She was tired in the morning because did not have good bed time. She also was being complained for having behavioural changes. She could not stay calm when doing simple conversation. She tend to moved around and talked to herself a lot. She said her concentrations was decreased, as seen as her school report was decreased for last 6 months.

Appetite was extremely increased since the last 6 months. She could eat until 7 times a day, with full portion of rice and meats. Her weight was increased 13 kilograms (kg) for the last 6 months. The changing in sense of thirst was denied, she drank enough water daily. There was no abnormal urination complaint, such as increased frequency of urinate or tend to urinate at night. The defecation was normal.

Her mother also had neck lump but never aware about it before, and did not having it checked to doctor yet. There was

no other same symptom in the family. There was no cancer, diabetes mellitus, asthma, hypertension, or other systemic disease in family.

She was treated in K Distric Hospital outpatient clinic and was said having mental disorder. Patient then was treated for 4 months with drugs those given by the previous doctor. The drugs were withdrawn by patient herself 2 months ago.

Her neck lump was being examined on ultrasonography (USG). The result was bilateral thyroiditis and multiple right and left paracarotid lymphadenopathy. The patient did not receive any treatment and then being referred to our outpatient clinic (figure 1).

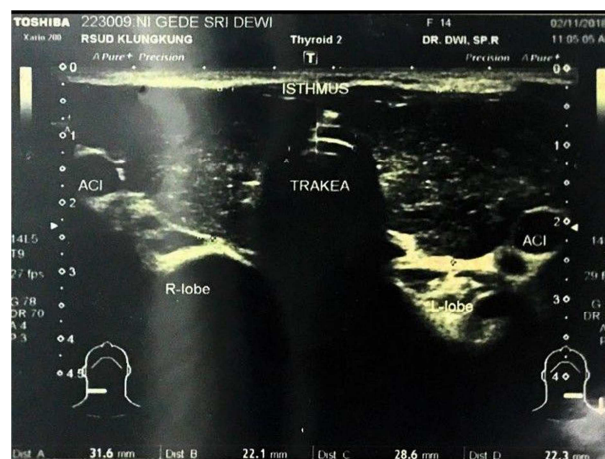


Figure 1. Thyroid Ultra Sound.

From our outpatient clinic, the patient is hospitalized, with therapy propylthiouracil 100 mg every 12 hours and planning diagnostic for electrocardiogram (ECG) evaluation, echocardiography, Thyroid antibodies (TRab), and consult to cardiology division. Monitoring performed for vital sign and Thyroid Crisis Scoring.

Complete blood count, electrolytes count, and liver functions were normal. Increase result in thyroid function was found with FT4>100,000; TSH_s <0.05; T3 total 28.6 nmol/L and TRAb 36.5 gr. From the result from ECG monitoring was sinus tachycardia, heart rate 118 bpm, normal QRS complex, no prolonged PR interval, no abnormal ST waves. The echocardiography found mild tricuspid regurgitation, trivial mitral regurgitation and doesn't need cardiac treatment with plan for re-echo one year later (November 2019).

Athropometric status found that the patient was well nourished, with TB/U <P5, BB/U P5-10, BB/TB in P50, and ideal body weight was 40 kg according to CDC growth charts with Waterlow 100%. Her father was 165 cm and her mother 158 cm with the genetic potential height was 146.5-163.5 cm. The upper body segment and lower body segment ratio was 75 cm: 72 cm ~ 1.04. From the pubertal status found with Tanner stage II, the breast growth found with breast budding, and areolar hyperplasia with small amount of breast tissue and the pubic hair growth found soft pubic hair near the labia.

Based on the clinical and adjunctive examination, the patient was diagnosed with hyperthyroidism et causa grave disease, mild tricuspid regurgitation, trivial mitral

regurgitation, well nourished. Patient has been given thyrozol 10 mg and propranolol 10 mg every 12 hours.

3. Discussion

Normal thyroid function is maintained by endocrine interactions between the hypothalamus, anterior pituitary and thyroid gland. Iodide is transported across the basement membrane of the thyroid cells by an intrinsic membrane protein called the Na/I symporter (NIS) [1, 3]. At the apical border, a second iodide transport protein called pendrin moves iodide into the colloid, where it is involved in hormonogenesis. Once inside the follicle, most of the iodide is oxidized by the enzyme thyroid peroxidase (TPO) in a reaction that facilitates combination with a tyrosine molecule to ultimately form thyroxine (T4) and triiodothyronine (T3). Thyroxine is the major thyroid hormone secreted into the circulation (90%, with T3 composing the other 10%). There is evidence that T3 is the active form of the hormone and that T4 is converted into T3 before it can act physiologically [4].

All of the major organs in the body are affected by altered levels of thyroid hormone. These actions are mainly mediated by T3. In the cell, T3 binds to a nuclear receptor, resulting in transcription of specific thyroid hormone response genes [2, 5].

Thyrotoxicosis is the clinical syndrome that results when tissues are exposed to high levels of circulating thyroid hormone. In most instances, thyrotoxicosis is due to hyperactivity of the thyroid gland, or hyperthyroidism. Grave's disease, an autoimmune thyroid disease associated with thyroid-stimulating hormone (TSH)-receptor stimulating antibodies, is the most common form of thyrotoxicosis leading to thyroid storm, whilst other causes of thyrotoxicosis such as toxic multinodular goitre and toxic adenoma are less-frequent causes [6, 8].

Grave's disease is the most common cause of hyperthyroidism in children and is due to the effect of thyroid stimulating hormone (TSH) receptor stimulating antibodies which stimulate the thyroid to produce excess hormones. The incidence of Grave's disease is believed to be between 0.1 and 3/100,000 children with a prevalence of 1 in 10,000 children in the United States. In Indonesia, the case is 1/100,000 children. Female is predominantly affected by this disease. Familial inheritance also reported in several cases [10]. In our case, the patient is female, age 14 years old. Her mother also has neck mass at anterior part, that she did not recognize it until our finding.

The clinical manifestations of Grave's disease are varying in different age range [11]. Although presenting symptoms are similar to the adult population in many ways, children and adolescents may present with non-specific symptoms that can be overlooked or attributed to normal changes children go through, such as nervousness, fatigue, sleep disturbances, or behavioral and learning disorders [10, 11]. In our case, the patient came with chief complain of palpable mass around the

neck. She also suffered from palpitation, agitated, sleep disturbances, difficulties in concentration and behavioural changes.

As Grave's disease is a common risk factor of hyperthyroidism. The various options for treatment of Grave's disease in children include antithyroid drugs, radioactive iodine ablation, and thyroidectomy [8, 12]. In most centers, the majority of children with grave's disease are initiated on antithyroid drugs with Radio Active Iodine (RAI) ablation and surgery being reserved for children who do not achieve sustained remission with anti-thyroid drugs. Anti-thyroid drugs (ATD) include methimazole and propylthiouracil (PTU) which reduce thyroid hormone synthesis [8, 10, 13]. In 2009, because of the unacceptably high rates of PTU-induced liver injury requiring liver transplant in children, the medication is no longer approved in the pediatric population. Methimazole may be used, but care should be taken to administer the lowest effective dose as dangerous side effects such as agranulocytosis are generally dose-dependent. Anti-thyroid medications alone are not curative therapy, they simply mitigate the symptoms of hyperthyroidism until the Grave's Disease goes into spontaneous remission or a definitive treatment is chosen [14]. Considering the adverse effects of ATD especially fatal liver injury with propylthiouracil (PTU) and the fact that <30% of children achieve sustained remission with ATD, there is increase in the number of children subjected to RAI [5, 6]. Still, ATD forms the initial therapy for pediatric Grave's Disease in a significant proportion of subjects [15].

The recommended starting dose is 0.5–1.0 mg/kg/day for methimazole and 5–10 mg/kg/day for PTU [7]. In a study comparing low and high dose methimazole (<0.5 mg/kg vs. >0.5 mg/kg), more subjects (82%) responded to the higher dose than the lower dose (42%) [9, 14]. The medications are initiated at this dose and reduced every 4–8 weeks after documenting resolution of symptoms and thyroid function tests [9]. In most patients with Grave's disease, there is early reduction of T3 and T4 to normal levels correlating with resolution of symptoms. Recovery of suppressed TSH to normal levels occurs gradually. Continued suppression of serum TSH in patients with Grave's disease during ATD treatment is related to thyroid binding inhibiting immunoglobulin, pre-treatment severity of hyperthyroidism, and time to normalization of serum T₃ and T₄ [10].

The doses of ATD are progressively reduced and maintained at minimum doses required to maintain a clinical and biochemical euthyroid (Normal T3 and T4) for a period of 12–24 months [8]. Following that the ATD is discontinued, and patient kept under follow-up for recurrence of symptoms. In the block and replace method, both ATD and thyroxine are supplemented in an attempt to maintain euthyroid. However, this approach needs a higher dose of ATD and hence vulnerable to the adverse effects [11].

In our case, the patient treated with antithyroid drug, which

is twice daily with tyrosol 10 milligram. Along monitoring of the disease, the patient shows significant positive changes along the treatment. Her high blood pressure, palpitation, and tachycardia relieves. She started to have well sleep at night and less agitated.

Grave's disease can lead to several complications such as cardiac arrhythmia and heart failure. Although dilated cardiomyopathy has been occasionally reported in adults with Grave's disease, it is rare in children. Other complication that also could happen is in the eyes, which could lead to blindness [5, 9]. In our case, we performed several examinations for her heart, and eyes. The result from ECG monitoring was sinus tachycardia without atrioventricular block, from echocardiography there was mild tricuspid regurgitation and trivial mitral regurgitation. We already planned to monitor her disease progress furthermore. The natural history of untreated Grave's disease in children is not well described. A patient is considered to be in remission if T3, T4, and TSH remain normal 1 year after discontinuation of antithyroid therapy. [12] The remission rates in various studies. The remission rates in adults with Grave's disease seem to be variable with studies from US reporting it at 20–30% remission after 12–18 months of dedication. [13] European study indicated a 50–60% remission rate after 5–6 years of treatment. [13–15] The remission rates in children seem to be lower than in adults. Remission rates in children with grave's disease are around 20–30%, and seem to be worse for patients with large glands, high antibody levels or very high free T4 levels at diagnosis. Younger children have lower remission rates and higher relapse rates than older adolescents and adult patients [7, 15]. In our case, the patient performs clinical improvement. Her clinical manifestation at her first admission relieved, while waiting for the thyroid antibody result. This must be maintained by a good compliance from the patient to have continuous monitoring to doctor, or else thyrotoxicosis would appear again or worst, thyroid storm.

Thyroid storm is an acutely exaggerated manifestation of the thyrotoxic state. Many of the manifestations of thyrotoxicosis are related to the increase in oxygen consumption and use of the metabolic fuels associated with the hypermetabolic state, as well as to the increase in sympathetic nervous system activity that occurs [6, 9]. The detailed pathophysiology of thyroid storm is not fully understood, but is thought to be related to increased numbers of beta1-adrenergic receptors being exposed to increased catecholamine levels in states of stress. Displacement of free thyroid hormones by circulating inhibitors of binding in systemic illness (e.g. cytokines) may also play as important role [11, 15].

Thyroid storm by definition represents the extreme in the spectrum of thyrotoxicosis where decompensation of organ function can occur [15]. Therefore any of the classical signs and symptoms of a thyrotoxic state may be seen. The scoring system suggested by Burch and Wartofsky (Table 1) illustrates the typical features of end organ dysfunction that may be seen when thyrotoxicosis is severe enough as to be termed thyroid

storm [10, 15].

Table 1. Diagnostic Criteria for Thyroid Storm [15].

Clinical Feature	Scoring
Thermoregulatory Dysfunction	
37.2 - 37.7°C	5
37.8 - 38.2°C	10
38.3 - 38.8°C	15
38.9 - 39.4°C	20
39.5 - 39.9°C	25
≥40°C	30
Cardiovascular Dysfunction	
Tachycardia (beats per minute)	
<99	0
99 – 109	5
110– 119	10
120 – 129	15
130 – 139	20
≥140	25
Congestive Heart Failure	
Absent	0
Mild (pedal oedema)	5
Moderate (Bibasal rales or crackles)	10
Severe (Pulmonary oedema)	15
Atrial Fibrillation	
Absent	0
Present	10
Central Nervous System Dysfunction	
Absent	0
Mild (Agitation)	10
Moderate (Delirium, psychosis, extreme lethargy)	20
Severe (Seizures, Coma)	30
Gastrointestinal-hepatic Dysfunction	
Absent	0
Moderate (Diarrhea, nausea/ vomiting, abdominal pain)	10
Severe (Jaundice)	20
Previous Episode of Thyroid Storm	
Absent	0
Present	10
Total	20
Interpretation	
>45	High-likely Thyroid Storm
25 – 44	Suggestive of Impending Storm
<25	Unlikely to Represent Storm

Fever is almost universal (>39°C or 102°F) and when present in an unwell patient with known thyrotoxicosis, should prompt immediate consideration of thyroid storm [11, 12]. Associated profuse sweating contributes to excessive insensible water and electrolyte loss leading to dehydration. Cardiac decompensation, usually in the context of high-output cardiac failure, is manifested as evidence of peripheral oedema or pulmonary congestion with respiratory compromise when severe. Tachyarrhythmias are common and usually atrial in origin, unless there is a predisposition to ventricular arrhythmias secondary to primary cardiac disease [2, 5, 10].

Neurological dysfunction may be severe enough as to cause profound delirium or psychosis. Liver dysfunction, secondary to either the presence of cardiac failure with hepatic congestion or hypoperfusion, or a direct effect of the excess

thyroid hormone itself, is characterized by abnormal liver function biochemistry. Jaundice may be noted, and abdominal pain is often seen accompanied by nausea and vomiting, and diarrhea [13, 15].

Patient with Grave's disease whom treated with antithyroid drugs should be monitored in long period of time, since thyrotoxicosis of thyroid storm would present in non compliance patient [9]. Most children with Grave's disease treated with antithyroid drugs do not experience remission, but most remissions do not end in relapse. Adverse reactions to methimazole are common but generally mild [12, 15].

4. Conclusion

In conclusion, we reported Graves' Disease in fourteen years old girl with lower TRAb level which more likely to achieve remission. Since anti thyroid drugs is still the option of treatment for Graves' Disease, long-term treatment will be very challenging. Such a long-term treatment course was inevitably associated with poor medical adherence and adverse event. Realistic discussion and consultation should be applied in all newly-diagnosed pediatric Graves' Disease patients.

References

- [1] Leger J, Kaguelidou F, Alberti C, Carel J. C. (2014). Graves' disease in children. *Best Practice & Research Clinical Endocrinology & Metabolism* 28: 233-243.
- [2] Gastaldi R, Poggi E, Mussa A. (2014). Graves disease in children: Thyroid-stimulating hormone receptor antibodies as remission markers. *The Journal of Pediatrics* 1-8.
- [3] Leger J, Oliver I, Rodrigue D, Lambert A, Coutant R. (2018). Graves' disease in children. *Annales d'Endocrinologie* 79: 647-655.
- [4] Minamitani K, Sato H, Ohye H, Harada S, Arisaka O. (2017). Guidelines for the treatment of childhood-onset Graves' disease in Japan, 2016. *Clin Pediatr Endocrinol* 26 (2): 29-62.
- [5] John M, Sundrarajan R, Gomadam S. (2015). Anti-thyroid drugs in pediatric graves disease. *Indian J Endocrinol Metab* 19 (3): 340-6.
- [6] Lanas A, Diza P, Eugenin D, Gonzalez F, Cid P, Cordero F. (2017). Clinical features of patients with basedow grave's disease seen at a university hospital. *Rev Med Chil* 145 (4): 436-440.
- [7] Boiro D, Ciedhiou D, Niang B, Sow D, Mbodi M, Sarr A. (2017). Hyperthyroidism in children at university hospital in Dakar, Senegal. *Pan Afr Med* 28 (10): 1-5.
- [8] Yasuda K, Miyoshi Y, Tachibana M, Namba N, Miki K, Nakata Y. (2017). Relationship between dose of hyperthyroid drugs and adverse events in pediatric patients with grave's disease. *Clin Pediatr Endocrinol* 26 (1): 1-7.
- [9] Leger J, Carel C. (2017). Management of endocrine disease: Arguments for the prolonged use of antithyroid drugs in children with grave's disease. *Eur J Endocr* 177: R59-67.
- [10] Chiang Y, Ting W, Huang C, Huang S, Chan C, Cheng B, et al. (2020). Long-term outcomes of graves disease in children treated with anti-thyroid drugs. *Pediatrics and Neonatology* 61: 311-317.
- [11] Choi Y. J., Jang J. H., Park S. H., Oh J. H., Koh D. K. (2016). Dilated cardiomyopathy with grave's disease in a young child. *Ann Pediatr Endocrinol Metab* 21: 92-5.
- [12] Elfenbein D. M., Katz M, Schneider D. F., Chen H, Sippel R. S. (2016). Thyroidectomy for grave's disease in children: Indications and complications. *J Pediatr Surg* 51 (10): 1680-3.
- [13] Singh A, Purani C, Mandal A, Mehariya K, Das R. R. (2016). Prevalence of thyroid disorders in children at a tertiary care hospital in western India. *J Clin Diagn* 10 (2): SC01-4.
- [14] Sanyal D, Chatterjee S. (2015). Hyperthyroidism in children: Treatment outcomes and preference in Eastern India. *Clin Pediatr Endocrinol* 24 (2): 65-6.
- [15] Batubara, Jose R. L. *Buku Ajar Endokrinologi Anak*, 1st ed., Badan Penerbit IDAI: Jakarta, 2010, pp. 250-300.