

Onychomycosis in the Military Hospital of Marrakesh: A Five-year Experience

Fatima Babokh^{1,2,*}, Zineb Nassiri^{1,2}, El Mostafa El Mezouari^{1,2}, Redouane Moutaj^{1,2}

¹Department of Parasitology-Mycology, Military Hospital Avicenne, Marrakech, Morocco

²Faculty of Medicine and Pharmacy, Cadi Ayad University, Marrakesh, Morocco

Email address:

Fatibabokh2018@gmail.com (F. Babokh)

*Corresponding author

To cite this article:

Fatima Babokh, Zineb Nassiri, El Mostafa El Mezouari, Redouane Moutaj. Onychomycosis in the Military Hospital of Marrakesh: A Five-year Experience. *American Journal of Laboratory Medicine*. Vol. 6, No. 4, 2021, pp. 66-69. doi: 10.11648/j.ajlm.20210604.13

Received: July 25, 2021; **Accepted:** August 10, 2021; **Published:** August 27, 2021

Abstract: Onychomycosis is a nail fungal infection caused by dermatophytes, becoming one of the most frequent reasons for consultation in mycological dermatology in Morocco. The purpose of this work is to describe the epidemiology of onychomycosis and to specify the most frequently isolated fungal agents in the Avicenna Military Hospital of Marrakesh. This is a retrospective study that included 875 patients and took place in the Avicenna Military Hospital of Marrakesh over a period of 5 years. Direct examination on a slide with a coverslip after clarification with potassium hydroxide (KOH 30%), as well as culture on Sabouraud media supplemented with chloramphenicol and chloramphenicol with cycloheximide were systematically carried out. Incubation was carried out in 20-25°C for dermatophytes and 37°C for yeasts and molds. The tubes were regularly controlled (twice a week) for at least four weeks before giving negative results. Between January 2015 and July 2019, 875 patients were enrolled in this study. Sex ratio (M:F) was 1.06. The average age was 48 years. Toenails were affected in 683 cases (78%), fingernails in 192 cases (21.9%), and both fingernails and toenails in 120 cases (13.7%). *Pachyonychia* was present in 63% of the cases (551/875), subungual hyperkeratosis in 50.8% of the cases (444/875) and xanthonychia in 43% of them (376/875). 61% (625 / 875) of direct examinations were positive, of which 83% (522/625) were confirmed by positive culture. Dermatophytes were isolated in 86.8% of the cases (n=759), yeasts in 13% (n=113) and molds in 0.2% of the cases (n=2). *Candida albicans* was the only identified yeast in this series (13%), found mainly in fingernails. In addition, toenail onychia was mainly caused by dermatophytes. *Trichophyton rubrum* and *Trichophyton mentagrophytes* var *interdigital* represented 80.8% and 6% of isolated dermatophytes, respectively. This work attests the contribution of mycological examination to the confirmation of fungal origin of onychopathies and the treatment orientation. *Trichophyton rubrum* was isolated in the majority of our cases.

Keywords: Onychomycosis, *Trichophyton rubrum*, *Candida albicans*

1. Introduction

Onychomycosis is a nail fungal infection caused by dermatophytes, yeasts or molds. represent approximately 30% of superficial mycoses and 50% of causes of onychopathies [1]. This condition is generally not serious but is poorly tolerated by patients; onychomycosis is becoming one of the most frequent reasons for consultation in mycological dermatology in Morocco. The existence of numerous differential diagnoses (nail psoriasis, mechanical ungual dystrophy, etc.) explains the importance of mycological sampling in order to avoid inadequate management leading to

unnecessary, risky and expensive treatments. The objective of this study is to describe the current epidemiology of onychomycosis and to specify the most frequently isolated fungal agents at the Avicenna Military Hospital in Marrakesh (Morocco).

2. Patients and Methods

This is a retrospective study, which was conducted over a period of five years (January 2015- July 2019), in the Parasitology and Medical Mycology Laboratory of the Avicenna Military Hospital of Marrakesh (Morocco).

During the study period, 875 samples were taken in the

laboratory by a medical biologist.

For the sampling technique, the damaged nails were first disinfected with alcohol then cut with sterile nail clippers all the way to the junction with the healthy nail. The samples were taken by scraping the subungual scales at the junction or at the leukonychia zone. The scales were then collected in a sterile glass Petri dish. If there was perionyxis, the pus was taken using a sterile swab. Each sample was joined by a sheet containing epidemiological data (age, sex...), clinical information (previous treatments, history, clinical aspect...) and risk factors.

Mycological examination was carried out in two steps: First, a direct examination consisting of a microscopic study of the fresh samples (scales of the fingernails and toes), after clarification with potassium hydroxide (KOH 30%), was performed in search for mycelial filaments and / or yeasts. Then the samples were sowed on Sabouraud media supplemented with chloramphenicol and chloramphenicol with cycloheximide.

The samples were deposited in agar slant tubes under aseptic conditions. The tubes were then incubated in an oven at 25-37°C for at least 30 days for dermatophytes and 72 hours for yeasts and / or molds.

The cultures were daily controlled in order to assess the growth time of the fungi and to follow the macroscopic evolution of the colonies in culture.

If there is growth, the yeast-like colonies were identified after performing the serum filamentation test or blastesis test. This test was carried out by adding a drop of yeast suspension in 1 ml of fresh human serum. The preparation was incubated at 37°C for three hours. Auxanograms were then performed on API120 galleries for yeasts with a negative blastesis test.

The identification of dermatophytic species was carried out on average after 15 days of incubation. It was based on the growth speed, macroscopic aspect of both sides of the colonies, pigment development and eventual diffusion as well as on microscopic aspect.

Positive diagnosis of onychomycosis was made if direct examination and / or culture were positive. Molds were incriminated when the fungal agent was found in a second sample taken from the same lesion. After being approved by a

biologist, the results were given to the patients in order to be presented to a dermatologist for therapeutic management.

3. Results

This study reported a male predominance with a sex ratio (M:F)=1.06. The mean age of the patients was 48 years with extremes ranging from 3 to 65 years. The majority of patients were between 30 and 55 years old.

The prevalence of confirmed onychomycosis in the patients included in our study was 72.2% (632 cases).

683 patients (78%) had toenail onychomycosis and 400 (58%) of them were males. The lesions were unilateral in 225 cases (33%) and bilateral in 428 cases (67%).

Reported toenail onychomycoses were essentially distal lateral subungual onychomycoses (564/683: 82.5%). They were most often associated with toe web intertrigo, found in 25% of our patients (Figure 1).

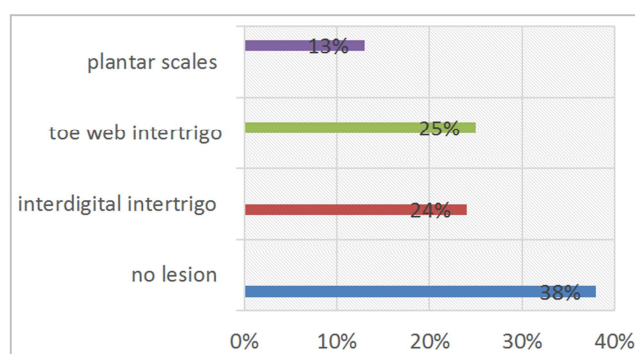


Figure 1. Different lesions associated with onychomycosis.

Fingernail onychomycosis was found in 192 patients, 146 (77%) of whom were females. The lesions were unilateral in 92 cases (47%) and bilateral in 100 cases (53%) (Table 1).

The most common clinical form found in fingernails was proximal subungual onychomycosis (102/192; 53%). It should be noted that 120 patients had mixed lesions (both on fingernails and toenails) and for which palmar and plantar samples were separately made.

Table 1. Lesion characteristics.

		Toenail affection (n=683)		Fingernail affection (n=192)	
		Number	Percentage	Number	Percentage
Sex	Males	400	58%	46	23%
	Females	283	42%	146	77%
Type of lesion	Unilateral	225	33%	92	47%
	Bilateral	428	67%	100	53%

The most often found clinical signs in our patients were, respectively, pachyonychia (63% (551/875)), subungual hyperkeratosis (50.8% (444/875)), xanthonychia (43% (376/875)) and perionyxis (19% (166/875)) (Figure 2).

Direct examination was positive for 712 samples (81.3%). Culture was positive for 692 samples (79%). And both direct examination and culture were positive for 632 samples (72.2%) (Table 2).

Table 2. Distribution of onychomycosis cases based on direct examination and culture results.

	Positive culture	Negative culture	Total
Positive direct examination	632	80	712
Negative direct examination	60	103	163
Total	692	183	875

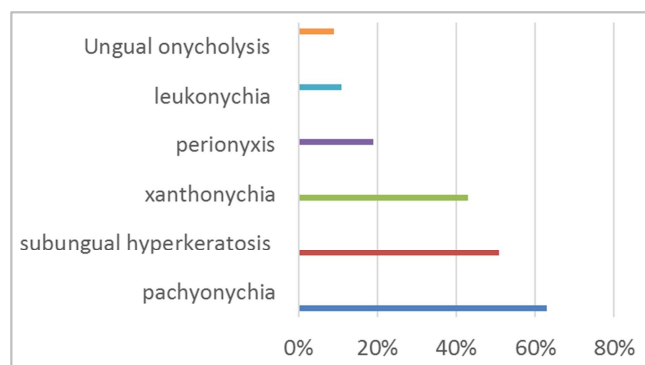


Figure 2. Different clinical signs of onychomycosis.

Yeasts were mainly observed on direct examination in three quarters of fingernail samples (140/192: 73%).

As for toenails, direct examination showed fungal elements in more than half of the samples (382/683: 56%).

In culture, three groups of fungi were found, of which dermatophytes were the most dominant; in fact two dermatophyte species were isolated: 707 strains of *Trichophyton rubrum* (80.8%) and 52 strains of interdigital *Trichophyton* (6%). Yeasts were responsible for 13% of onychomycosis (113 strains) and *Candida albicans* was the only isolated and identified species in culture.

Onychomycosis due to pseudodermatophytes (molds) represented 0.2%: two strains of *Scytalidium hyalinum* were identified (figure 3).

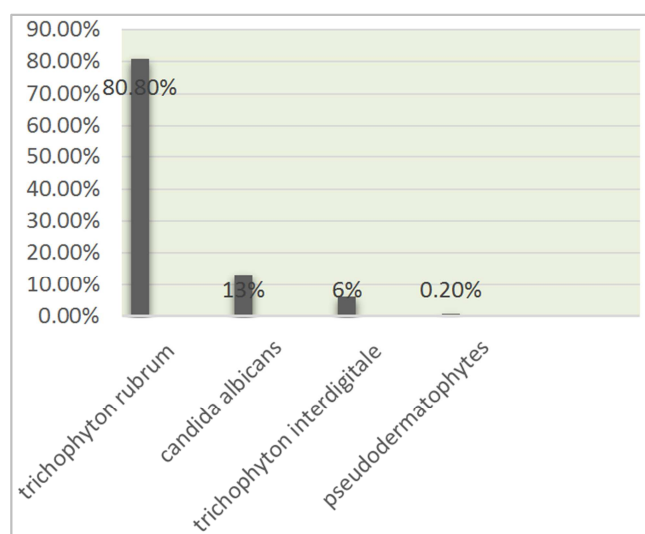


Figure 3. Rate of different species found in culture.

4. Discussion

Onychomycosis is a chronic nail infection and its prevalence in the general population ranges from 2 to 18% [1]. It represents 18 to 50% of nail pathologies and constitutes 1.5 to 18% of the reasons for dermatology consultations [2].

In Morocco, the actual prevalence of onychomycosis is certainly underestimated because of the high cost of their management leading to restriction on mycological examination prescription, hence lack of confirmation of

mycological etiology in case of nail lesions.

Moreover, a large number of patients with onychomycosis are not aware of this condition and its possible complications and therefore do not systematically seek medical attention in case of a non-painful onychodystrophy.

According to this study, the most represented age group was 30 to 50 years with an average age of 48 years: this result is similar to that of Halim and al [3] (46 years) in Morocco and that of Kouotou in Cameroon (40.7 years) [4]. However, it is different from that of Ab Youssef in Tunisia, which reported predominance in an older age group (over 60 years old) [5].

Males were affected in more than half of the cases (59%). This increased incidence in men in this study, unlike several studies that have reported female predominance [3, 5, 6], can be explained by their higher outdoor exposure and physical activity, and by wearing shoes for long periods of time.

In this work as well as in the literature [3, 5, 6], onychomycosis was predominant in the toenails. This could be explained by frequent contamination of the toes by soil containing anthropophilic fungi, by humidity and maceration favored by wearing closed shoes and micro-trauma [7], as well as the slower nail growth rate in toes compared to fingers which leads to reduced fungus elimination [3].

In addition, result analysis according to the site of lesions shows highly significant predominance of fingernail lesions in women, which can be explained by contact with detergents and citrus fruits.

Out of the 875 patients included in our study, direct examination was positive in 712 specimens (81.3%). Direct microscopy examination is necessary, reliable and can provide a rapid response for the clinician; in fact, it can refer them to the fungus in question by showing fungal hyphae in case of dermatophytes or pseudo-hyphae in case of molds, or by directly visualizing yeasts [8, 9]. However, culture was positive in 79% of the cases (692/875 cultures). It compensated for false negative diagnoses on direct examination in 60 cases. Culture should systematically be associated with direct examination. In fact, isolating and identifying fungi in culture is important since the treatment may differ depending on isolated species. However, culture can be negative despite positive direct examination as shown in 80 of our cases. These false negative diagnoses might likely be due to the sowing of a non-parasitized sample, to low parasitism, antifungal treatment not reported by the patient or an inexperienced sampler. As a matter of fact, there might be real differences in results depending on sample quality.

Dermatophytes were the most common etiology of onychomycosis in our study, with *Trichophyton rubrum* leading the way (80.8% of the cases). This is in agreement with the current epidemiology. In fact, *Trichophyton rubrum* is the first fungal agent responsible for dermatophyte onychomycosis. Its prevalence is 96.9% in Tunisia [5], 85.1% in France [10], 53.6% in Senegal [11], 42% in Brazil [12] and 44.4% in Turkey [13].

The second species of dermatophytes responsible for onychomycosis according to our results was *T. interdigitale*. It was isolated in only 6% of cases, whereas it is involved in 13.7%

of onychomycoses in France [10] and in 38% in Brazil [12].

In this study, yeast onychomycosis (found in 13% of cases) was more frequent in fingernails than that due to dermatophytes. *Candida albicans* was the only isolated species. This result is consistent with several studies, which show that *C. albicans* is the predominant species leading to yeast onychomycosis [5, 11, 14]. For mold onychomycosis, only 2 cases of *Scytalidium hyalinum* were recorded in our study. This can be explained by the difficulty to confirm the pathogenicity of a mold which relies on a set of arguments including sample renewal and isolation of the mold in pure culture.

5. Conclusion

This study asserts the contribution and efficiency of mycological examination since it confirmed fungal etiology in 72% of cases and revealed diversity in the isolated fungi. Mycological confirmation of fungal etiology in onychopathies and precision of involved species are important elements for choosing the appropriate treatment. Thus, the laboratory plays a very important role in confirming the mycological origin of onychomycosis, which is a differential diagnosis with many dermatoses of similar clinical expression.

References

- [1] Farhi D, Savary J, Pansart S, Hesse S. Etude prospective des onychomycoses des pieds en France: prevalence, aspect clinique, impact et prise en charge en médecine générale. *J Mycol Med* 2011; 21: 266–72.
- [2] Société française de dermatologie, Recommandations Onychomycose. Modalités de diagnostic et prise en charge. *Ann Dermatol Venerol* 2007; 134: 7–16.
- [3] Halim F, El Kadioui, M. Soussi Abdallaoui. Les onychomycoses à Casablanca (Maroc). *Journal de Mycologie Médicale* (2013) 23, 9–14.
- [4] E. A. Kouotou, F. A. Kechia, Y. Iwewe Somo, U. Nguena Feungue N. J. R. Nansseu c, R. Moyou Somo. Profil mycologique des onychomycoses vues en consultation de dermatologie à Yaoundé, Cameroun. *j.mycmed*.2017.03.002.
- [5] Ben Youssef, A. Kallel Z. Azaiz, S. Jemel, N. Bada, A. Chouchen, N. Belhadj-Salah, N. Fakhfakh, S. Belhadj, K. Kallel. Onychomycosis: Which fungal species are involved? Experience of the Laboratory of Parasitology-Mycology of the Rabta Hospital of Tunis A. *Journal de Mycologie Médicale*. Volume 28, Issue 4, December 2018, Pages 651–654.
- [6] Manasa N Kayarkatte, Archana Signal, Deepika Pandhi, Shukla Das. linico-mycological Study of Onychomycosis in a Tertiary Care hospital-A Cross-Sectional Study. *Mycoses* 2020 Jan; 63 (1): 113–118.
- [7] Nzenze S, Ngoungou EB, Mabika M, Bouyou MK, Avome IM, Kombila M. Les onychomycoses au Gabon: aspects cliniques et mycologiques. *J Mycol Med* 2011; 21: 248–55.
- [8] Zagnoli A, Chevalier B, Sassolas B. Dermatophyties et dermatophytes. In: EMC, Pédiatrie, Maladies infectieuses. 2005; 1–14.
- [9] Chabasse D, Bouchara JP, de Gentile L, Brun S, Cimon B, Penn P. Les dermatophytes. *Cahier Formation Bioforma* 2004; 37: 159.
- [10] P. Zukervar, G. Dabin, T. Secchi, A. Petiot-Roland, N. Mathon, M. Maccari, B. Pincemaille, A. Colcombet-Navarranne a, G. Rigot-Muller a, V. Batut a, S. Picot b, A.-L. Bienvenu b. Étude des onychomycoses en médecine de ville dans la région lyonnaise, France. *Journal de Mycologie Médicale* (2011) 21, 118–122.
- [11] M. C. Seck, D. Ndiaye, K. Diongue, M. Ndiay, A. S. Badiane, D. Sow, K. Sylla, R. Tine, J. L. Ndiaye. Profil mycologique des onychomycoses à Dakar (Sénégal) *Journal de Mycologie Médicale* (2014) 24, 124–128.
- [12] Larissa Lopes Milane Bentine, Lucas Xavier Bonfietti2 & Maria Walderez Szeszs, Marcia de Souza Carvalho Melhem2. Onychomycoses in a Military Population in Brazil. *Curr Fungal Infect Rep* (2017) 11: 171–175.
- [13] Mustafa Gulgun, Elcin Balci, Abdalbaki Karaoglu, Vural Kesik, Oguzhan Babacan, Muzaffer Kursat Fidanci, Turker Turker, Duran Tok, Nedret Koc: Prevalence and risk factors of onychomycosis in primary school children living in rural and urban areas in Central Anatolia of Turkey *Indian J Dermatol Venereol Leprol* 2013; 79: 6; 777–782.
- [14] S. Nzenze Afène, E. B. Ngoungou, M. Mabika Mamfoumbi, M. K. Bouyou Akotet, I. M. Avome Mba, M. Kombila; Onychomycosis in Gabon: Clinical and mycological data *Journal de Mycologie Médicale* (2011) 21, 248–255.