

Report

Biological Incorporation of Lyophilized Radiation Sterilized Bone Allograft and Mixed Bone Graft for the Management of Cysts and Cyst Like Lesions in Bone

Nakul Kumar Datta^{1, *}, Krishna Priya Das¹, Mohammad Mamun Mia²

¹Department of Orthopaedic Surgery, Bangabandhu Sheikh Mujib Medical University (BSMMU), Dhaka, Bangladesh

²Tissue Banking and Biomedical Research Unit, Atomic Energy Research Establishment (AERE), Dhaka, Bangladesh

Email address:

nkdatta123@yahoo.com (N. K. Datta)

*Corresponding author

To cite this article:

Nakul Kumar Datta, Krishna Priya Das, Mohammad Mamun Mia. Biological Incorporation of Lyophilized Radiation Sterilized Bone Allograft and Mixed Bone Graft for the Management of Cysts and Cyst Like Lesions in Bone. *American Journal of Internal Medicine*. Vol. 8, No. 6, 2020, pp. 304-311. doi: 10.11648/j.ajim.20200806.20

Received: October 31, 2020; **Accepted:** November 16, 2020; **Published:** December 4, 2020

Abstract: Cystic lesions include Simple bone cyst and Aneurysmal bone cyst, and among cyst like lesions studied Giant cell tumor, fibrous dysplasia and Non-ossifying fibroma. This prospective interventional study was conducted in the Department of orthopaedic surgery Bangabandhu Sheikh Mujib Medical university (BSMMU) and Biomedical research division, Atomic energy centre Savar, Dhaka Bangladesh from January 2004 to December 2019. Out of 155 Cysts and cysts like lesions were operated, among which cystic lesions were 73 (47.10%), among cystic lesions SBC was 51 (69.86%), and ABC-22 (30.14%) and cyst like lesions were 82 (52.90%), among cyst like lesions GCT was 68 (82.92%), FD was 12 (14.63%) & NOF was 2 (2.43%). All cases were operated by thorough curettage and cavity filled with Lyophilized radiation sterilized bone allograft impregnated with autogenous bone marrow for children and mixed bone graft in adult. Clinical and radiological evaluation was done in all cases in which 61 (83.56%) out of 73 cystic lesions were healed and 12 (16.44%) lesions were recurred, on the other hand 58 (70.73%) out of 82 cyst like lesions were healed and 24 (29.27%) lesions were recurred. Out of 155 cysts and cyst like lesions 119 (76.78%) were healed / satisfactory and 36 (23.22%) were recurred. Follow up period were 9 month to 15 years. P value is <.001. Main aims to evaluate the complete healing of cystic and cyst like lesions of bone with in corporation of allograft. Bone marrow impregnated Lyophilized radiation sterilized bone allograft and mixed bone graft is useful graft material for healing of the lesional area and restoring structural integrity as well as function for management of cysts and cyst like lesions in bone.

Keywords: Bone Allograft, Autogenous Bone Marrow and Mixed Graft, Cysts and Cyst Like Lesions

1. Introduction

Cysts and cyst like lesions of bone are not uncommon in our country like Bangladesh. In the treatment of cystic lesions include Simple bone cyst and Aneurysmal bone cyst, among cyst like lesions studied are Giant cell tumor, fibrous dysplasia, and Non-ossifying fibroma, need large quantity of bone graft to fill the above mention bone lesions. This is not possible to meet auto graft alone. It is difficult to get enough autogenous bone from adult and especially in children and even in patients in whom previous graft harvesting has been performed. It is

only possible to collect inadequate amount of autograft. Lyophilized radiation sterilized bone allograft is often used is alternative to autogenous bone graft, can be safely used in treatment of bone lesions when other forms of bone graft are not easily available especially in children. Using bone allograft eliminates the need for a second operation site and reduce the rate of donor site morbidity, shortening of total operation time and convalescence, minimizing surgical shock and decreasing post operative pain and complication. Lyophilized radiation sterilized bone allograft supply by the tissue bank and Biomedical Research division, Atomic Energy centre, Savar Dhaka, Bangladesh of their easy storage,

transportation and distribution. This type of allograft substantially reduced immunogenicity. The sequence of events of incorporation of allograft is qualitatively similar to that of auto graft but slower rate although in manner identical to fresh autograft. [1, 2] Freeze dried bone is more rapidly transformed into new bone than frozen bone. [3, 4] The best way of ensuring the incorporation of allograft of all kinds is to impregnate the graft with autogenous bone marrow obtained from host. [5, 6] Mixed bone graft: Autograft + Allograft "seed" to provide osteogenic potential. Mixed bone graft of this type will incorporate more rapidly than allograft bone alone. [7] Main aims to evaluate complete healing of cysts and cyst like lesions in bone with incorporation of allograft. Transplantation of allogenic bone as a method of treatment in various disorder of skeleton was started in last decade of 19th century and 1st decade of 20th century united states Navy tissue bank introduce freeze-dried bone allograft for orthopaedic reparative surgery 1951 [8] ionizing radiation was introduced as a method of sterilization of bone graft. The products of freeze-drying have the advantage of an approximate short life of four to five years [9]. Simple bone cyst is the most common benign lytic bone lesion in children mainly affecting the proximal femur and proximal humerus, attributed to a local disturbance of bone growth. [10-13] Although the pathogenesis is still unknown [14, 15], the lesion appears to be reactive or developmental rather than to represent a true neoplasm [16]. SBC consists solitary cavity lined by a membrane and filled with a clear yellow fluid [17] It represent approximately 3% of primary bone lesion [18] The SBC is more common in male 3:1 and detected during first two decades of life. [16, 17] The vast majority of SBC are located proximal diaphysis of humerus and femur when they occur in patients younger than 17 yrs old. [12, 19] The pathological fracture is often the first sign of lesion. [11, 12] The older patients the incidence of involvement of atypical sites such as calcaneum, talus and ilium rises significantly [17, 20]. In these sites the lesion is usually asymptomatic and discovered by accident. Epiphyses extension is unusual [20, 21] ABC: is now generally accepted as a definite recognizable distinctive vascular lesion of the bone. The non-neoplastic nature of ABC however is now clearly established. [22, 1] ABC although first described in 1942 by Jaffe and Leichstein [24, 25] the true aetiology is still unknown [26] typically affects the metaphysis of long bones. in young patients, and peak incidence occur in second decade of life [27, 31]. Several ABC treatment modalities had been utilized including wide resection, [25, 32, 34] intralesional resection/ curettage with or without different adjuvants, [29, 34, 38] radiation, embolization [39-42]. ABC occurs before the age of 20 yrs, [43, 44] ABC most commonly present with a localized pain. [32, 44, 45] Re-currence rates after different therapeutic approach vary widely ranging from 0% to more than 59% [25, 27, 31, 34, 38, 46, 47, 48-51]. ABC may be encountered at any age and in almost any bone though more often in young adults in long bone metaphysis. Giant cell tumor: Giant cell tumor is highly controversial tumor. One end of the spectrum of this lesion designated as benign giant cell tumor. On the

other hand because of its unpredictable and rare metastatic behavior it has been called malignant giant cell tumor. Some author preferred to as sometimes malignant [52]. Jaffe preferred to simply use the name Giant cell tumor, dropping the designation of benign [53]. Although these tumor typically are benign pulmonary metastasis occur approximately 3% of patients. Some times with pulmonary metastasis have spontaneous regression or remain as asymptomatic for many years [54]. Though generally classed as benign, it tends to recur after local removal or curettage [55] GCT is a benign but locally aggressive tumor that usually involved the end of long bones. It occurs most frequently in the 3rd decade of life, after physal plate closure. GCT represents 20% of all benign bone tumors and 5% of all bone tumors [56]. High incidence is seen in China and India, where they represent up to 20% of all bone tumors [57, 58]. It appears in mature bone most commonly in distal femur, proximal tibia, fibula, proximal humerus and distal radius but others bone may be affected [59]. Approximately 70% of patients are between 20 to 40 years old. It can cause pain full effusion because of its juxta-position to a major joint [60]. Characteristically it is eccentric, expanding radiolucent usually centered in epiphysis. usually a solitary lesion although there have been rare reports multiple bone involvement [61-64]. Grossly the tumor has a reddish fleshy appearance or chocolate brown to grayish or mottled appearance [64] The local recurrence rate of GCT confined to bone (comapanancci Grade I and II) was only 7% and compared with 29% in companancci Grade III. Fibrous dysplasia: is benign bone condition in which abnormal fibrous tissue develops in place of normal bone and bone becomes weaker. In weight bearing bones such as femur, the bone bend in its upper part since it is subjected to great stress and a sheprd's crook deformity. It may affect one bone (monostotic or many bones (polyostotic). It occurs chiefly in adolescence and symptomless until spontaneous fracture. Cystic areas of lesion in metaphysis or shaft of long bone are common. Fibrous dysplasia are ground glass appearance in Xray. Curettage and bone grafting may be indicated for selected adult patients with monostotic disease [65] and deformities are corrected by osteotomy with internal fixation. The use of intramedullary (IM) devices is strongly suggested for all lower extremity fracture and reconstruction [66-68]. Non ossifying fibroma: is considered a larger form of fibrous cortical defect. [69] Many author believe it is a different entities [70]. This is a benign defect in the metaphysical region of cortex of long bone in child or young adult [71]. With NOF multiple lesion may take on appearance of fibrous dysplasia. Surgery is indicated when the lesion is so large that fracture is imminent or has occurred or when significant pain is present. [70] If surgery is indicated preferably curettage and bone grafting should be done. Non- ossifying fibroma account for 2% of biopsied primary bone tumor [71]. It is also common cyst like metaphysial lesion of young children [72]. Jaffe and Lichtenstien [53-74] and Hatcher [73] showed that biopsy of these lesions revealed fibrous tissue thus coining the term fibrous cortical defect and non-osteogenic fibroma.

2. Methods

This prospective case study had been carried out at Department of orthopaedic, Bangabondhu Sheikh Mujib Medical University (BSMMU), Dhaka, Bangladesh from January 2004 to December 2019. Minimum follow up period 9 month to 10 years. Total number of 155 cysts and cyst like lesions of bone were operated. The data were collected from each patient including age, Gender, side involved, type of lesions and bone site involvement. The efficacy of Lyophilized radiation sterilized bone allograft, mixed with autogenous bone marrow and mixed bone graft application on the basis of physical examination, roentgenographic assessment and numerous control post-operative visits. Follow up for each patient either the lesions were healed or recurred. The date of each recurrence of and type of subsequent treatment were also noted. The patients were first diagnosed as a cysts and cyst like lesions of bone by history, clinical examination and relevant investigations had been established by histological examination. Lyophilized radiation sterilized bone allograft was supplied by the Tissue Bank and Biomaterial Research unit, Atomic Energy Research Establishment, Savar Dhaka.

Operative technique: Surgery was done in all the cases – exposure of Cysts and Cyst like lesions of bone, according to bone site involvement either by giving General anesthesia, or regional block. Almost all the cases of GCT in companancci group II and III. After wide unroofing of the lesion, thoroughly curettage the cavity up to well vascularised host bed and washed several times with hydrogen peroxide, normal saline and betadine solution and tightly filled with Lyophilized radiation sterilized bone allograft impregnated with autogenous bone marrow from upper part of tibia for children and mixed bone graft for adult. Stabilization was achieved all the cases by immobilization in plaster cast. The cases were followed up at six weeks interval until six months and then at 3 months interval till one year and at six months interval. Minimum follow up period 9 months to 10 years. Data were collected, compiled and tabulated according to the key variables. All the statistical analysis of different variable were analysed according to standard statistical method and calculation done by using computer based software. statistical package for social science (SPSS). Statistical analysis was done by Z test and chi square test.

3. Results

Out of 155 of cysts and cyst like lesions of bone, cystic

lesions were 73 (47.10%), among them SBC were 51 (32.90%) and ABC were 22 (14.20%). Most common age range of SBC, 11yrs to 20yrs was 35 (68.03%) and most common age range of ABC, 21yrs to 30 yrs was 14 (63.64%). In Table 1, out of 82 (52.90%) cyst like lesions, GCT was 68 (43.87%), FD was 12 (7.74%) and NOF was 02 (1.29%). Most common age range of GCT, 21yrs to 40 yrs was 56 (82.32%), most common age range of FD was 21 to 30 yrs were 10 (83.34%) and 02 NOF age was 24 yrs & 35yrs. In Table 1, Sex distribution of patients among 51 SBC, 36 (70.59%) was male and 15 (29.41%) were female. Out of 22 ABC, male was 15 (68.18%) and female was 07 (31.82%). Among 68 GCT, 47 (69.12%) was female and 21 (30.88%) was male. Among 12 FD, 8 (66.67%) was male and 4 (33.33%) were female and 02 (100%) of NOF was female. In Table 2, common sites of cysts and cyst like lesions of bone. Out of 51 SBC common sites are proximal humerus 28 (54.90%) and proximal femur 8 (15.69%). Among 22 ABC, proximal femur 11 (21.57%) and proximal humerus 6 (11.76%). Among 68 GCT, distal femur were 30 (44.12%) and proximal tibia were 22 (32.35%). Among 12 FD, shaft of femur were 7 (58.33%) and 2 NOF almost whole of tibia 1 (50%) and distal part tibia 1 (50%) in table 3.

3.1. Evaluation of Results

Clinical outcome was graded on the basis of evidence of incorporation of allograft. The procedure was considered successful in healed cases and failure in recurred cases. Cysts and Cyst like lesions of bone to be classified as healed when complete obliteration of the cavity and incorporation of allograft [8] and recurred cases in which cystic cavity re appeared and enlarge to involved more on bone causing expansion and thinning of the cortex with imminent threat of pathological fracture [19].

Outcome of cysts and cyst like lesions of bone, out of 51 SBC healed (Successful) were 45 (88.24%) and recurred were 6 (11.76%). Among 22, ABC healed were 16 (72.73%) and recurred were 6 (27.27%). Among 73 cystic lesions 61 (83.56%) were healed and recurred were 12 (16.44%) shown in table 4. Among 68 GCT healed were 50 (73.53%) and recurred were 18 (26.47%). Out of 12 FD, healed were 8 (66.67%) and recurred were 4 (33.33%) and out of 2 NOF healed were 0% and recurred were 2 (100%). Among 82 cyst like lesions healed were 58 (70.73%) and recurred were 24 (29.27%) shown in table 5. Final out come out of 155 cysts and cyst like lesions healed were 119 (76.78%) and recurred were 36 (23.22%) shown in table 6.

Table 1. Age distribution of patients with cysts and cyst like lesions in bone (n 155).

Age group (year)	Cystic lesions		Cyst like Lesions			Total
	SBC	ABC	GCT	FD	NOF	
0-10	12 (23.53%)	0 (0.00%)	0 (0.00%)	0 (0.00%)	0 (0.00%)	12
11-20	35 (68.63%)	07 (31.82%)	10 (14.70%)	01 (08.33%)	0 (0.00%)	53
21-30	04 (07.84%)	14 (63.64%)	26 (38.24%)	10 (83.34%)	02 (100%)	56
31-40	0 (0.00%)	01 (4.54%)	30 (44.12%)	01 (08.33%)	0 (0.00%)	32
41-50	0 (0.00%)	0 (0.00%)	02 (2.94%)	0 (0.00%)	0 (0.00%)	02
Total	51 (100%)	22 (100%)	68 (100%)	12 (100%)	02 (100%)	155

Figure in parenthesis indicate percentage (^{NS} Not Significant in Chi- square test).

SBC: simple bone cyst, ABC: Aneurysmal bone cyst, GCT: giant cell tumor, FD: Fibrous dysplasia, NOF: non ossifying fibroma.

Table 2. Sex distribution of patients with cysts and cyst like lesions in bone (*n*155).

Sex	Cystic		Cyst like lesions			Total
	SBC	ABC	GCT	FD	NOF	
Male	36 (70.59%)	15 (68.18%)	21 (30.88%)	08 (66.67%)	0 (0.00%)	80 (51.61%)
Female	15 (29.41%)	07 (31.82%)	47 (69.12%)	04 (33.33%)	02 (100%)	75 (48.39%)
Total	51 (100%)	22 (100%)	68 (100%)	12 (100%)	02 (100%)	155 (100%)

Figure in parenthesis indicate percentage (^{NS} Not Significant in Chi- square test).

SBC: simple bone cyst, ABC: Aneurysmal bone cyst, GCT: giant cell tumor, FD: Fibrous dysplasia, NOF: non ossifying fibroma.

Table 3. Bone site involvement of cysts and Cyst like lesions. (*n* 155).

Site	Cystic		Cyst like lesions		
	SBC	ABC	GCT	FD	NOF
Humerus	28 (54.90)	06 (27.27%)	03 (4.42%)	01 (8.33%)	0
Femur	08 (15.69%)	11 (50%)	30 (44.12%)	07 (58.34%)	0
Radius	04 (7.84%)	0	07 (10.29%)	0	0
Ulna	02 (3.92%)	0	01 (1.47%)	0	0
Tibia	05 (9.81%)	02 (9.09%)	22 (32.35%)	03 (25.00%)	02 (100%)
Calcaneum	01 (1.96%)	02 (9.09%)	01 (1.47%)	0	0
Phalanx	02 (3.92%)	0	01 (1.47%)	0	0
Clavicle	0	01 (4.55%)	0	0	0
Rib	0	0	0	01 (8.33%)	0
1 st Metacarpal	0	0	01 (1.47%)	0	0
1 st Metatarsal	0	0	01	0	0
Patella	0	0	01 (1.47%)	0	0
Ilium	01 (1.96%)	0	0	0	0
Total	51	22	68	12	02

Figure in parenthesis indicate percentage (^{NS} Not Significant in Chi- square test).

SBC: simple bone cyst, ABC: Aneurysmal bone cyst, GCT: giant cell tumor, FD: Fibrous dysplasia, NOF: non ossifying fibroma.

Table 4. Outcome of Cystic lesions in bone (*n*-73).

Type	Number	Healed	Recurred
SBC	51	45 (88.24%)	06 (11.76%)
ABC	22	16 (72.73%)	06 (27.27%)
Total	73	61 (83.56%)	12 (16.44%)

Figure in parenthesis indicate percentage (^{NS} Not Significant in Chi- square test).

SBC: simple bone cyst, ABC: Aneurysmal bone cyst, GCT: giant cell tumor, FD: Fibrous dysplasia, NOF: non ossifying fibroma.

Table 5. Outcome of cyst like lesions in bone (*n*-82).

Type	Number	Healed	Recurred
GCT	68	50 (73.53%)	18 (26.47%)
FD	12	08 (66.67%)	04 (33.33%)
NOF	02	0	02 (100%)
Total	82	58 (70.73%)	22 (26.83%)

Figure in parenthesis indicate percentage (^{NS} Not Significant in Chi- square test).

SBC: simple bone cyst, ABC: Aneurysmal bone cyst, GCT: giant cell tumor, FD: Fibrous dysplasia, NOF: non ossifying fibroma.

Table 6. Final outcome (*n*-155).

Result	Number of patients	Percentage
Healed	119	76.78%
Recurred	36	23.22%

P value is 0.001 by Z test, that is significant (<0.05).

4. Discussion

Cysts and cyst like lesions of bone are not uncommon in Bangladesh. In fact, management of cystic and cyst like lesion of bone still remain a challenge to the orthopaedic surgeon. The

goal of treatment is not only limb salvage but also maintenance adequate function of the extremity. In Bangladesh lyophilized radiation sterilized bone allograft continuously supplied by Tissue Bank and Biomedical Research division, Atomic Energy Research Establishment, Savar Dhaka. Since the majority of cysts that occur in young, in whom the sources of autogenous bone are often not adequate, it is reassuring to note the similarity in the over all healing rate with freeze dried cancellous bone allograft and autogenous bone graft. Controlled laboratory experiments have also shown that freeze dried bone allograft is the most satisfactory bank bone and compares favorably to autograft control and comparative study of healing process, following different type transplantation [75].

The similar recurrence rates in solitary bone Cysts that have been curetted and packed with autogenous and with bank bone suggests that factors other than the type of the graft used influence the post-operative results. Such factors are age, sex, location, cyst size, the thoroughness of the curettage and the completeness of packing with bone graft [6].

The efficacy of application of lyophilized radiation sterilized bone graft in orthopaedic surgery. In one study out of 435 cases, 59 cases of filling of bone lesions used in Simple bone cyst, Giant cell tumor and Fibrous dysplasia over result were estimated healed (successful) 91%⁸ In which higher healing rate in compare with our study healed (successful) 76.78% was due to our large sample size and also exclusion of ABC in their study.

It has been observed that out of 280 patients of Giant cell tumor, treated by intralesional procedure 27% were recurred usually appeared in first 3 years after surgery [76]. In compare

with this study recurrence rate 26.47% almost similar, Table 6.

Giant cell tumor of bone. An analysis of two hundred and eighteen cases, age distribution common in skeletally mature patients, higher incidence in third decades, there are 125 female and 93 males, predominantly female and common sites distal ends of radius, femur and proximal end of tibia. Seventy seven (35%) of 218 patient had recurrence, follow up period 6 to 9 years [77]. Compare their findings with those of our findings it is seen that correlate well only age and sex distribution but not with recurrence rate. Recurrence rate in our study 26.47% shown in table 6, less recurrence rate in this study due use mixed bone graft.

5. Conclusion

Bone marrow impregnated Lyophilized radiation sterilized bone allograft for children and mixed bone graft for adult is useful graft material for enhancing osteogenic potential and healing of the lesional area, restoring structural integrity as well as function for management of cysts and cyst like lesions in bone. The procedure is relatively simple, cost effective and in general well accepted by the patients. Low rate of recurrence can be achieved if through curettage the cavity upto well vascularised host bed and tightly packed by bone graft in properly selected cases through a well planned surgical approach.

Photography of the Patient

Case 1: Fibrous dysplasia involving almost whole of Right humerus of 22yrs female.

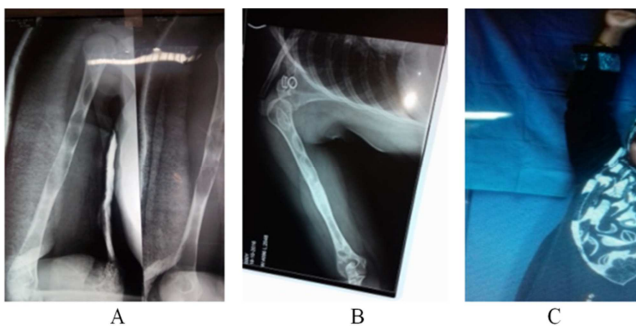


Figure 1. 1A, Pre-operative X-Ray. 1B, post-operative X-Ray at 2 years (After through curettage the cavity and filled with mixed bone graft) complete healing of lesion. 1C, Post-operative photograph at 2 yrs, full abduction of right shoulder joint.

Case 2. Giant cell tumor involving proximal Tibia of 26 yrs old male.

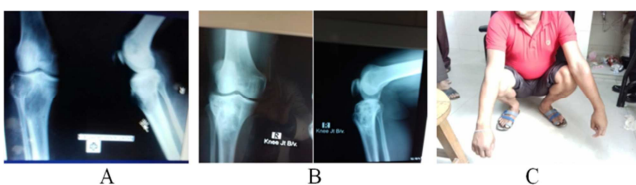


Figure 2. 2A Pre-operative X-Ray. 2B Post-operative X-Ray at 10yrs (good incorporation of mixed bone graft) 2C, He can able to Squat comfortably and able to walk.

Case 3. Aggressive type (Companancci Grade III) Giant cell tumor involving distal Tibia of 25 yrs male patient

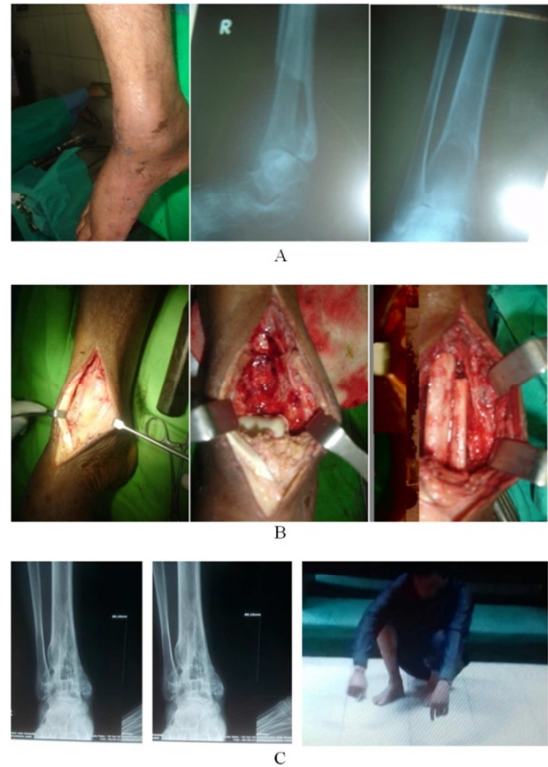


Figure 3. 3A pre operative photograph & X-ray. 3B per operative excision of tumor mass and gap about 5cm filled with double fibular graft along with mixed graft for tibio talar arthrodesis. 3C post operative follow up at 5 yrs with complete healing lesion and patient can able to squat and walk.

Case 4. Giant cell tumor involving proximal femur of 15 yrs old girl.

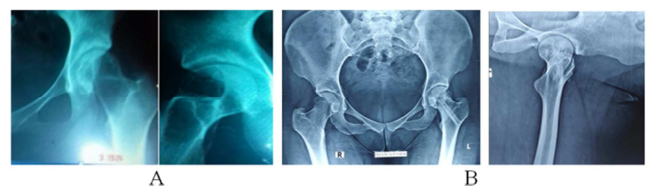


Figure 4. 4A, Pre-operative X-ray. 4B Post-operative follow up at 10 yrs, good incorporation of graft.

Case 5. Simple bone Cyst involving proximal femur of 13 yrs old boy.

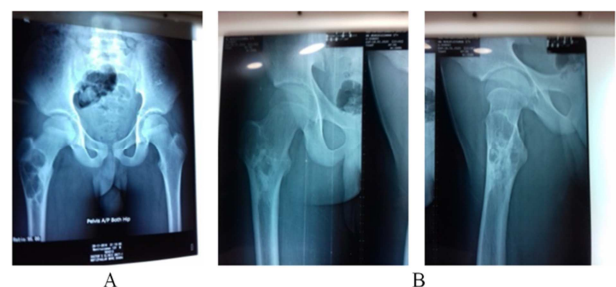


Figure 5. 5A Pre-operative X-ray. 5B. Post Op follow up at 3 years.(Curettage the cavity and filled with allograft mixed with autogenous bone marrow) good healing of lesion,

Case 6. Simple bone cyst involving proximal humerus with pathological fracture of 12 yrs old boy.

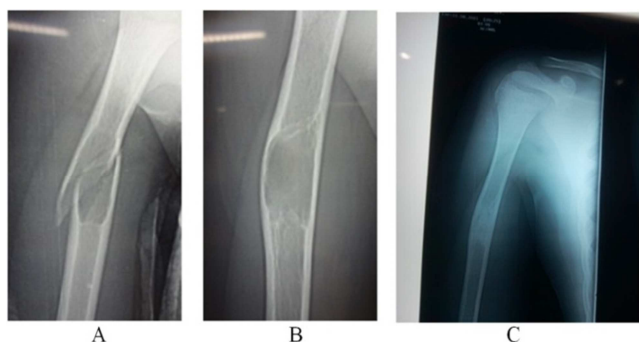

Figure 6. 6A Pre-operative X-ray, treated conservatively, 6B. Complete healing of fracture but residual cavity persist. 6C. Follow up at 2 yrs good incorporation of graft (after curettage the cavity and filled with allograft mixed with autogenous bone marrow.)

Case 7 Aneurysmal bone cyst involving proximal humerus of 16 yrs old girl.

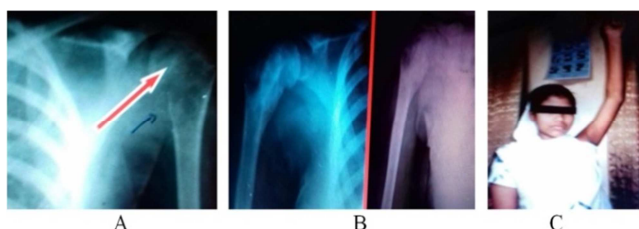


Figure 7. 7A Pre-operative X-ray. 7B. post-operative X-ray at 6month & 18 months good incorporation of graft. 7C. Good abduction of left shoulder.

Case 8. Non ossifying fibroma involving almost whole of tibia 35 yrs old female.

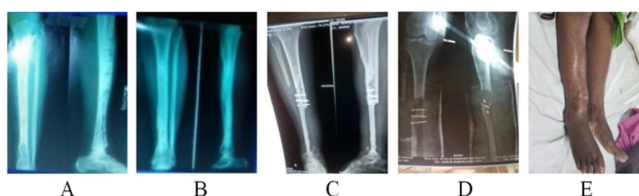


Figure 8. 8A Pre-operative x-ray 8B post-operative at 6 yrs, complete healing of lesion & she can able to walk painlessly upto 8 yrs, 8C. After 8 yrs recurrent occur at lower part & tibialization of fibula done at that time biopsy came as admentinoma 8D & 8E. At 18 month after tibialization again recurrent occur & severe pain swelling of leg and subsequently mid thigh amputation done.

Ethical Issue

This topic was presented several times in Bangladesh Orthopaedic Society annual Conference and IOCON-2016, and also study as a MS thesis article in BSMMU, Dhaka, Bangladesh.

Conflict of Interest

All the authors do not have any possible conflicts of interest.

References

- [1] Friedlaender GE. 1987. current concepts review: Bone graft the basic science rationale for clinical applications. J Bone Joint surg. 69: 786-789.
- [2] Samuel LT. 1984. orthopaedics: principles and Their Application. 4th edn. Vol. 1. pp. 31-100. Lippincott company, New work.
- [3] Kreuz FP, Hyatt GW, Turner JGTC and Bassett JGAL, 1951. The preservation and clinical use of freeze-dried bone. J Bone Joint Surg. 33: 863-872.
- [4] Urist MR, Silverman BF, Buring CG, Klas JC, Dubuc FL. and Rosenberg JM. 1967. The Bone induction principle. Clin Orthop. 53: 243-283.
- [5] Nade G and Burwell RG. 1977. Decalcified bone as a substrate for osteogenesis. J Bone Joint Surg. 59: 189-196.
- [6] Spence KF, Sell KW and Brown RH. 1969. Solitary bone cyst: Treatment with freeze dried cancellous bone allograft. J Bone Joint Surg. 51: 87-96.
- [7] Andrew H, Crenshaw (Jr) AH Surgical techniques and approaches (bone grafting). In: canale ST editor Campbell's operative orthopaedics. Vol. 1, 9th edn. New work, Mosby. 1998: 29-47.
- [8] Zasacki W. 1991. The efficacy of application of lyophilized, radiation sterilized bone graft in orthopaedic surgery. Clin Ortho Relt Res. 272: 82-87.
- [9] Conrad EU, Ericksen DP, Tencer AF, Strong DM, Mackenzie AP. The effects of freeze drying and rehydration on Cancellous Bone. Clin Ortho Relt Res 1993; 290: 279-84.
- [10] Broder HM. Possible precursor of unicameral bone cyst. JBJS Am. 1968; 50: 503-507.
- [11] Cohen J. Etiology of simple bone cyst. JBJS Am. 1970; 52: 1493-1497.
- [12] Jaffe HL, Lichtenstein L. Solitary unicameral bone cyst with emphasis on the roentgen picture, the pathologic appearance, and the pathogenesis. Arch Surg. 1942; 44: 1004-1025.
- [13] Weissel A, Hecht HL. Development of a unicameral bone cyst. JBJS Am. 1980; 62: 664-666.
- [14] Moore TE, King AR. Post traumatic cyst and cyst-like lesion of bone. Skelet Radiol. 1989; 18: 93-97.
- [15] Morton KS. The pathogenesis of unicameral bone cyst. Can J Surg. 1964; 7: 140-150.
- [16] Fechner RE, Mills SE, editors. Tumors of bones and joints. Armed Forces Institute For Pathology; 1993; Washington DC. pp. 173-186.
- [17] Baker M. Benign unicameral bone cyst. Clin Orthop. 1970; 71: 140-151.
- [18] Campanacci M, Capanna R. Unicameral and aneurysmal bone cyst. Skeletal Radiol. 1968; 204: 25-36.
- [19] Neer CS II, Francis KC, Marcove RC, Terz J and Carbonara PN. Treatment of unicameral bone cyst. A follow up study of one hundred seventy-five cases. JBJS Am. 1966; 48: 731-745.

- [20] Goldber RP, Genant HK. Case report 67. Solitary bone cyst of the right ilium. *skeletal Radiol*. 1978; 3: 118–121.
- [21] Capanna R, Van Horn J. Epiphyseal involvement in unicameral bone cyst. *Skeletal radiol*. 1986; 15: 428–432.
- [22] Lichten L. Aneurysmal bone cysts, further observation. *cancer* 1953; 6: 1228-37.
- [23] Sheman RS, Soong KY. Aneurysmal bone cyst: its roentgen diagnosis. *Radiology* 1957; 68: 54-64.
- [24] H. L. Jaffe and L. Lichtenstein, "Solitary unicameral bone cyst: with emphasis on the roentgen picture, the pathologic appearance and the pathogenesis," *Archives of Surgery*, vol. 44, no. 6, pp. 1004–1025, 1942.
- [25] H. J. Mankin, F. J. Hornicek, E. Ortiz-Cruz, J. Villafuerte, and M. C. Gebhardt, "Aneurysmal bone cyst: a review of 150 patients," *Journal of Clinical Oncology*, vol. 23, no. 27, pp. 6756–6762, 2005.
- [26] Sasaki, S. Nagano, H. Shimada et al., "Diagnosing and discriminating between primary and secondary aneurysmal bone cysts," *Oncology Letters*, vol. 13, no. 4, pp. 2290–2296, 2017.
- [27] H. Y. Park, S. K. Yang, W. L. Sheppard et al., "Current management of aneurysmal bone cysts," *Current Reviews in Musculoskeletal Medicine*, vol. 9, no. 4, pp. 435–444, 2016.
- [28] T. B. Rapp, J. P. Ward, and M. J. Alaia, "Aneurysmal bone cyst," *Journal of the American Academy of Orthopaedic Surgeons*, vol. 20, no. 4, pp. 233–241, 2012. View at: Publisher Site | Google Scholar.
- [29] A. M. Vergel De Dios, J. R. Bond, T. C. Shives, R. A. McLeod, and K. K. Unni, "Aneurysmal bone cyst. A clinicopathologic study of 238 cases," *Cancer*, vol. 69, no. 12, pp. 2921–2931, 1992. View at: Publisher Site | Google Scholar.
- [30] A. Leithner, R. Windhager, S. Lang, O. A. Haas, F. Kainberger, and R. Kotz, "Aneurysmal bone cyst. A population based epidemiologic study and literature review," *Clinical Orthopaedics and Related Research*, vol. 363, pp. 176–179, 1999. View at: Publisher Site | Google Scholar.
- [31] H. W. B. Schreuder, R. P. H. Veth, M. Pruszczyński, J. A. M. Lemmens, H. S. Koops, and W. M. Molenaar, "Aneurysmal bone cysts treated by curettage, cryotherapy and bone grafting," *Journal of Bone and Joint Surgery. British volume*, vol. 79, no. 1, pp. 20–25, 1997. View at: Publisher Site | Google Scholar.
- [32] P. Tsgozis and O. Brosjö, "Current strategies for the treatment of aneurysmal bone cysts," *Orthopedic Reviews*, vol. 7, no. 4, p. 6182, 2015. View at: Publisher Site | Google Scholar.
- [33] B. Erol, M. O. Topkar, E. Caliskan, and R. Erbolukbas, "Surgical treatment of active or aggressive aneurysmal bone cysts in children," *Journal of Pediatric Orthopaedics B*, vol. 24, no. 5, pp. 461–468, 2015. View at: Publisher Site | Google Scholar.
- [34] R. C. Marcove, D. S. Sheth, S. Takemoto, and J. H. Healey, "The treatment of aneurysmal bone cyst," *Clinical Orthopaedics and Related Research*, vol. 311, pp. 157–163, 1995. View at: Google Scholar.
- [35] R. J. Steffner, C. Liao, G. Stacy et al., "Factors associated with recurrence of primary aneurysmal bone cysts: is argon beam coagulation an effective adjuvant treatment?" *Journal Bone and Joint Surgery-American Volume*, vol. 93, no. 21, pp. e122 (1)–e122 (9), 2011. View at: Publisher Site | Google Scholar.
- [36] H. Aiba, M. Kobayashi, Y. Waguri-Nagaya et al., "Treatment of aneurysmal bone cysts using endoscopic curettage," *BMC Musculoskeletal Disorders*, vol. 19, no. 1, p. 268, 2018. View at: Publisher Site | Google Scholar.
- [37] J. Syvänen, Y. Nietosvaara, I. Kohonen et al., "Treatment of aneurysmal bone cysts with bioactive glass in children," *Scandinavian Journal of Surgery*, vol. 107, no. 1, pp. 76–81, 2018. View at: Publisher Site | Google Scholar.
- [38] E. H. M. Wang, M. L. Marfori, M. V. T. Serrano, and D. A. Rubio, "Is curettage and high-speed burring sufficient treatment for aneurysmal bone cysts?" *Clinical Orthopaedics and Related Research*, vol. 472, no. 11, pp. 3483–3488, 2014. View at: Publisher Site | Google Scholar.
- [39] S. Zhu, K. E. Hitchcock, and W. M. Mendenhall, "Radiation therapy for aneurysmal bone cysts," *American Journal of Clinical Oncology*, vol. 40, no. 6, pp. 621–624, 2017. View at: Publisher Site | Google Scholar.
- [40] G. Rossi, A. F. Mavrogenis, G. Facchini et al., "How effective is embolization with N-2-butyl-cyanoacrylate for aneurysmal bone cysts?" *International Orthopaedics*, vol. 41, no. 8, pp. 1685–1692, 2017. View at: Publisher Site | Google Scholar.
- [41] G. Rossi, E. Rimondi, T. Bartalena et al., "Selective arterial embolization of 36 aneurysmal bone cysts of the skeleton with N-2-butyl cyanoacrylate," *Skeletal Radiology*, vol. 39, no. 2, pp. 161–167, 2010. View at: Publisher Site | Google Scholar.
- [42] S. Terzi, A. Gasbarrini, M. Fuiano et al., "Efficacy and safety of selective arterial embolization in the treatment of aneurysmal bone cyst of the mobile spine," *SPINE*, vol. 42, no. 15, pp. 1130–1138, 2017. View at: Publisher Site | Google Scholar.
- [43] J. Cottalorda and S. Bourelle, "Modern concepts of primary aneurysmal bone cyst," *Archives of Orthopaedic and Trauma Surgery*, vol. 127, no. 2, pp. 105–114, 2007. View at: Publisher Site | Google Scholar.
- [44] E. Mascard, A. Gomez-Brouchet, and K. Lambot, "Bone cysts: unicameral and aneurysmal bone cyst," *Orthopaedics & Traumatology: Surgery & Research*, vol. 101, no. 1, pp. S119–S127, 2015. View at: Publisher Site | Google Scholar.
- [45] O. Hauschild, M. Lüdemann, M. Engelhardt et al., "Aneurysmal bone cyst (ABC): treatment options and proposal of a follow-up regime," *Acta Orthopaedica Belgica*, vol. 82, no. 3, pp. 474–483, 2016. View at: Google Scholar.
- [46] A. R. Ramírez and R. P. Stanton, "Aneurysmal bone cyst in 29 children," *Journal of Pediatric Orthopaedics*, vol. 22, no. 4, pp. 533–539, 2002. View at: Publisher Site | Google Scholar.
- [47] C. P. Gibbs, M. C. Hefele, T. D. Peabody, A. G. Montag, V. Aithal, and M. A. Simon, "Aneurysmal bone cyst of the extremities. Factors related to local recurrence after curettage with a high-speed burr," *Journal of Bone & Joint Surgery*, vol. 81, no. 12, pp. 1671–1678, 1999. View at: Publisher Site | Google Scholar.
- [48] P. Flont, M. Kolacinska-Flont, and K. Niedzielski, "A comparison of cyst wall curettage and en bloc excision in the treatment of aneurysmal bone cysts," *World Journal of Surgical Oncology*, vol. 11, no. 1, p. 109, 2013. View at: Publisher Site | Google Scholar.

- [49] J. E. Cummings, R. A. Smith, and R. K. Heck, "Argon beam coagulation as adjuvant treatment after curettage of aneurysmal bone cysts: a preliminary study," *Clinical Orthopaedics and Related Research*, vol. 468, no. 1, pp. 231–237, 2010. View at: Publisher Site | Google Scholar.
- [50] S. P. Peeters, I. C. M. Van der Geest, J. W. J. de Rooy, R. P. H. Veth, and H. W. B. Schreuder, "Aneurysmal bone cyst: the role of cryosurgery as local adjuvant treatment," *Journal of Surgical Oncology*, vol. 100, no. 8, pp. 719–724, 2009. View at: Publisher Site | Google Scholar.
- [51] J. P. Dormans, B. G. Hanna, D. R. Johnston, and J. S. Khurana, "Surgical treatment and recurrence rate of aneurysmal bone cysts in children," *Clinical Orthopaedics and Related Research*, vol. 421, pp. 205–211, 2004. View at: Publisher Site | Google Scholar.
- [52] Carnesale PG, Benign (occasionally malignant) tumor's of bone. In: Canale ST editor Campbell's operative orthopaedics. Vol. 1 9th edn. New York, Mosby 1998; 703-13.
- [53] Jaffee HL, Tumors and timorous condition of the bones and joints. Philadelphia, Lea and Febigen, 1958; 18-43.
- [54] Heek (Jr.) RK. Benign (occasionally aggressive) tumors of bone. In: Canale ST Daugherty K & Jones L, eds, Campbell's operative orthopaedics 10th edn. Vol. 1, Mosby, Philadelphia, 2003; 813-17.
- [55] Adams JC & Hamblen DL, Outline of orthopaedics, 13 th edn. Churchill Livingstone, New work, 2001; 82-86.
- [56] Turcotte RE. Giant cell tumor of bone. Orthop, Clin North AM. 2006; 37: 35-51.
- [57] Rao PT. Management of giant cell tumor of bone. Kini memorial oration. Indian J. Orthop. 1993; 27: 96-100.
- [58] Sung, HW, Kuo DP, Chai YB, Liu CC, Li SM. Giant cell tumor of bone: Analysis of two hundred and eight cases in Chinese patients. J. Bone Joint Surg. Am. 1982; 64: 755-61.
- [59] Solomon L, Warwick DJ, Nayagam S; Apley's system of orthopaedics and fracture, 8th edition, London Arnold. 2001; 167-199.
- [60] Randall RL and Hoang BH, Musculoskeletal oncology. In: Skinner HB editor. Current Diagnosis & treatment in orthopaedics, 4th edn. New Work, McGraw Hill Companies. 2006; 298-323.
- [61] Sim FH, Dahlin DC and Beabout JW. Multicentric giant cell tumor of bone. J Bone Joint Surg. 1977; 59A: 1052.
- [62] Sybrandy S, and De La Fuente AA. Multiple giant cell tumor of bone. Report of a case. J Bone Joint Surg. 1973; 55B: 350.
- [63] Tornberg DN and, Dick HM and Johnston A, Multicentric giant cell tomors in the long bones. J Bone Joint Surg. 1973; 57A: 429.
- [64] Turek SL. Orthopaedics principles and their application, Vol. 1. 4th Edn, New work, JB. Lippincott company. 1984; 30-100.
- [65] Enneking W F, Gearen PF. Fibrous dysplasia of the femoral neck. Treatment by cortical bone grafting. J Bone Joint SurgAm. 1986; 68: 1415-1422.
- [66] Ippolito E, Bray EW, Corsi A etal. Natural history and treatment of fibrous dysplasia of bone: a multicentre Clinico-pathologic study promoted by the European Paediatric orthopaedic society. J pediatri orthop B2003; 12: 155-177.
- [67] Stanton RP. Surgery for fibrous dysplasia. J Bone Miner Res. 2006; 21 (supp 2): p105-109.
- [68] Stanton RP, Diamond L, surgical management of fibrous dysplasia in. Mc Cune-Albright syndrome pediatri. Endocrinol Rev. 2007; 4 (Suppl 4): 446-452.
- [69] Randall RL and Hoang BH. Musculoskeletal oncology. In: Skinner HB ed. Current Diagnostic & treatment in Orthopaedics. 4th edn. New York: McGraw Hill companies; 2006. 298-323.
- [70] Carnesale PG. Benign Tumors of In: Canale ST ed. Campbell's operative Orthopaedics. Vol. 1, 9th edn. New York: Mosby; 1998. 683-99.
- [71] Gold RH & Marcove RC. Intraosseous spindle cell and collagen producing tumors, IN: Mirra JM ed. Bone tumors Diagnosis and treatments. Philadelphia: J B Lippincott company; 1980. 257-301.
- [72] Sontag LW and pyle SI. The appearance and nature of cyst like areas in the distal femoral metaphyses of children. Am J Roentgenol. Rad. Ther. Nucl. Med. 1941; 46-185.
- [73] Hatcher CH. The pathogenesis of localized fibrous lesions s in the metaphyses of long bones. Ann. Surg. 1945; 122: 1016.
- [74] Jaffe HL and Lichtenstein L. Non osteogenic fibroma of bone. Am J pathol. 1942; 18: 205.
- [75] Heiple KG, Chase SW and Herndon CHA. comparative study of the healing process following different types bone transplantation. The J Bone & Joint Surg. 1963; 45: 1593-1616.
- [76] Campanacci M, Baldini N, Boriani S, and Sudanese A, Giant cell tumor of bone.. J Bone Joint Surg. 1987; 69: 106-13.
- [77] Goldenberg RR, Campbell CJ and Bonfiglio M: Giant cell tumor of bone. An Analysis of two hundred and eighteen cases. J Bone Joint Surg 1970; 52: 649-61.