

Systemic lupus erythematosus associated hemophagocytic lymphohistiocytosis: A case report and literature review

Po-Chung Cheng¹, Yun-Chung Cheng²

¹Department of Internal Medicine, National Yang Ming University, Taipei, Taiwan, ROC

²Department of Radiology, National Taiwan University, Taipei, Taiwan, ROC

Email address:

luukskyw@yahoo.com (P. C. Cheng), luukskyw@hotmail.com (Y. C. Cheng)

To cite this article:

Po-Chung Cheng, Yun-Chung Cheng. Systemic Lupus Erythematosus Associated Hemophagocytic Lymphohistiocytosis: A Case Report and Literature Review. *American Journal of Internal Medicine*. Vol. 2, No. 3, 2014, pp. 49-53. doi: 10.11648/j.ajim.20140203.13

Abstract: Hemophagocytic lymphohistiocytosis (HLH) is a syndrome of immune overstimulation. HLH commonly manifests as multiple organ failure without apparent physiological stress. Primary HLH relates to genetic defects, whereas secondary HLH is triggered by infection, malignancy, or autoimmune disease. An aberrant natural killer cell or absence of T lymphocyte apoptosis causes uncontrolled inflammation. Secondary HLH in patients with systemic lupus erythematosus (SLE) is uncommon with an estimated prevalence of 0.9%. This report describes a male with SLE associated secondary HLH. Patients affected by HLH require prompt management, but delayed diagnosis is common due to its variable presentation. An eight week induction therapy with dexamethasone, etoposide, and intrathecal methotrexate increases survival in primary HLH and virus-associated secondary HLH. However, no standardized regimen exists for autoimmune associated HLH. Some patients respond to steroid monotherapy, while refractory patients may require cyclosporin, cyclophosphamide, or tacrolimus.

Keywords: Hemophagocytic Lymphohistiocytosis, Systemic Lupus Erythematosus, Autoimmune Disease

1. Introduction

This report describes hemophagocytic lymphohistiocytosis (HLH) associated with systemic lupus erythematosus (SLE). HLH is a syndrome of immune overstimulation and tissue hyperinflammation [1]. Primary HLH relates to genetic mutation. Secondary HLH is consequent to infection, autoimmune disease, or malignancy [2]. In regulated immune

systems, natural killer (NK) cells attenuate histiocyte activity. Activation induced apoptosis also reduces the active T lymphocyte population [3]. In HLH, aberrant NK cell regulation or absent activation induced apoptosis results in uncontrolled inflammation (Figure 1).

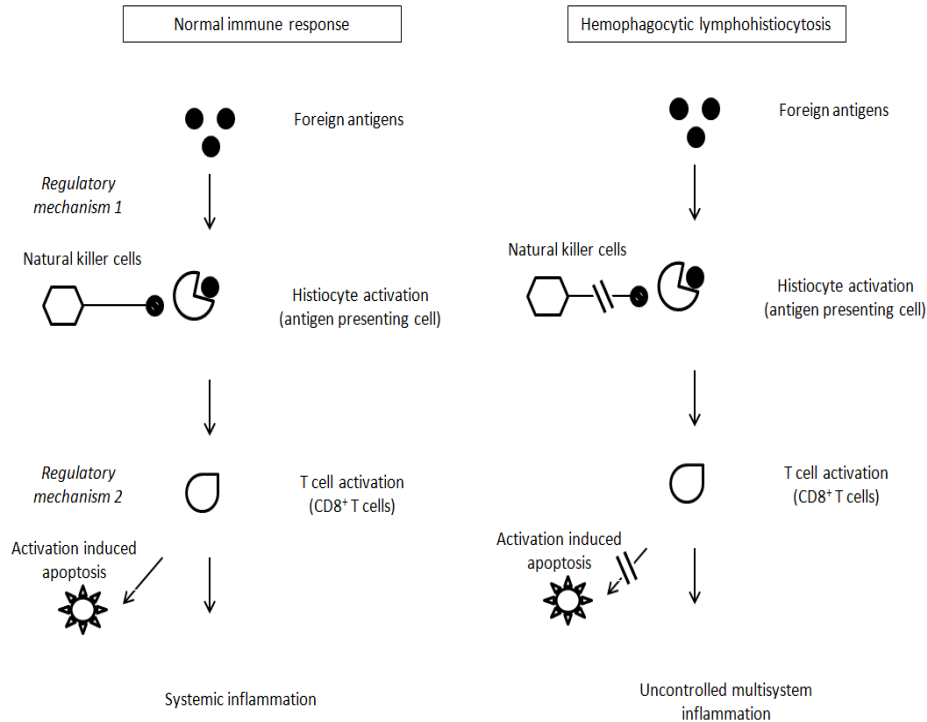


Figure 1. Pathogenesis of HLH

The Histiocyte Society proposed a diagnostic criteria for HLH in 2004 (Table 1) [4]. Prominent features of HLH include fever, cytopenia, and acute organ failure [4]. HLH should be considered in patients with acute multiple organ failure without apparent physiological stress. Although more commonly associated with rheumatologic disorders, HLH affects patients with a wide spectrum of medical conditions, including viral infection, congenital or acquired immune deficiency, and hematologic malignancy.

Delayed diagnosis is common because of its variable presentation. Affected patients often receive treatment for sepsis before their bone marrow examination identifies the underlying disorder. The diagnosis of secondary HLH is even more difficult because symptoms may mimic those of the triggering medical condition, such as SLE or viral infection.

Table 1. Diagnostic criteria for HLH

A. Molecular diagnosis: pathologic mutations of <i>PRF1</i> , <i>UNC13D</i> , <i>Munc18-2</i> , <i>Rab27a</i> , <i>STX11</i> , <i>SH2D1A</i> , or <i>BIRC4</i>
or
B. Five of the eight criteria below are fulfilled:
1. Fever $\geq 38.5^{\circ}\text{C}$
2. Splenomegaly
3. Cytopenia (at least 2 of 3 lineages in peripheral blood) Hemoglobin $< 9\text{ g/dl}$ Platelet $< 100000/\text{ml}$ Neutrophil $< 1000/\text{ml}$
4. Hypertriglyceridemia (fasting level $> 265\text{ mg/dl}$) and / or hypofibrinogenemia ($< 150\text{ mg/dl}$)
5. Hemophagocytosis in bone marrow, spleen, lymph nodes, or liver
6. Low or absent NK cell activity
7. Ferritin $> 500\text{ ng/ml}$ (equivalent to 500 ug/l)
8. Elevated sCD25 (soluble IL-2 receptor)

2. Case Report

A 71-year-old man visited the emergency room because of fever for two weeks. He reported no previous illness. On admission, his body temperature was 38.5°C , heart rate was 96/minute, respiratory rate was 18/minute, and blood pressure was 133/71 mm Hg. Anemic conjunctiva was found. Chest survey revealed no abnormality. Abdominal palpation elicited epigastric tenderness. Neurologic examination was unremarkable.

His hemogram reported a white blood cell count of 11200/ml (normal range (NR): 4000-11000/ml), neutrophils 87%, lymphocytes 8.0%, hemoglobin 7.1 g/dl (NR: 12.3-18.3 g/dl), and platelet count 59000/ml (NR: 150000-400000 /ml). Total bilirubin was 3.2 mg/dl (NR: 0.1-1.2 mg/dl) and direct bilirubin 1.6 mg/dl (NR: 0-0.2 mg/dl).

Direct and indirect Coombs tests were positive. Antinuclear antibody (ANA) titer was 1:320 (positive titer $\geq 1:160$) with fine speckled pattern. Anti-phospholipid antibody (APA) level was 92.1 MPL (positive $> 38\text{ MPL}$). Serum C3 and C4 were 69.5 mg/dl and 3.9 mg/dl, respectively (age-adjusted NR: 90-170 mg/dl). His daily urine protein was 0.72 grams. He fulfilled four of the American College of Rheumatology criteria for SLE, including positive ANA, positive APA, hemolytic anemia, and proteinuria.

Serum ferritin was 2100 ug/l (NR: 20-290 ug/l). Soluble IL-2 was 1928.7 pg/ml (NR $< 880\text{ pg/ml}$). His bone marrow revealed hemophagocytosis (Figure 2). He fulfilled five of the criteria for HLH, including fever $\geq 38.5^{\circ}\text{C}$, cytopenia,

hemophagocytosis in the bone marrow, ferritin elevation, and increased soluble IL-2 level.

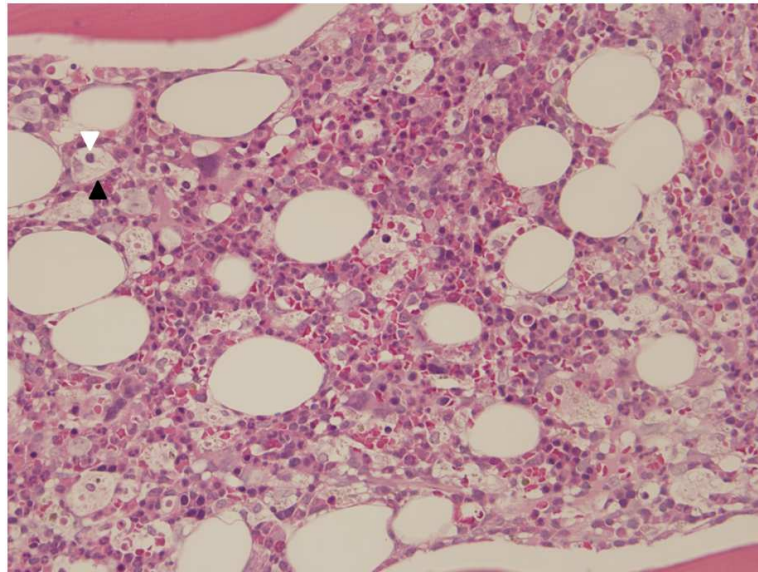


Figure 2. Histiocyte (black arrow) phagocytizing blood cells (white arrow) in the bone marrow (H&E stain x 400)

Acute delirium occurred during hospitalization. He received lumbar puncture to exclude infection of the central nervous system. Cerebrospinal fluid protein was 83 mg/dl (NR: 15-40 mg/dl), with normal glucose and white blood cell levels. No bacterium, fungus or virus was cultured.

No serologic evidence of hepatitis B or C, Epstein-Barr virus (EBV) or human immunodeficiency virus (HIV) was present. Antibody for cytomegalovirus was positive, but quantification test reported negligible titer.

The patient received Cefepime for prophylaxis of bacterial infection. Acute kidney injury occurred on the twelfth day of hospitalization. He underwent hemodialysis. On the twenty seventh day, his serum aspartate aminotransferase (AST) and alanine aminotransferase (ALT)

increased to 83 U/l and 71 U/l (NR: AST 8-38 U/l and ALT 10-50 U/l), respectively. Hepatitis peaked on the thirty sixth day with AST 244 U/l and ALT 222 U/l. He received dexamethasone, initially 5 milligrams twice daily and then 10 milligrams twice daily. Serum ferritin concentration reflects disease activity [5]. Ferritin level decreased after dexamethasone therapy (Figure 3). He received intravenous cyclosporin (100 mg/day) for 4 days and oral cyclosporin (100 mg/day) for 3 days. However, anemia and thrombocytopenia deteriorated (Figures 4 and 5). Rituximab was infused to suppress SLE activity. He received immunoglobulin (24 g/day) for 5 days and ganciclovir (250 mg/day) for 7 days for prophylaxis of cytomegalovirus infection.

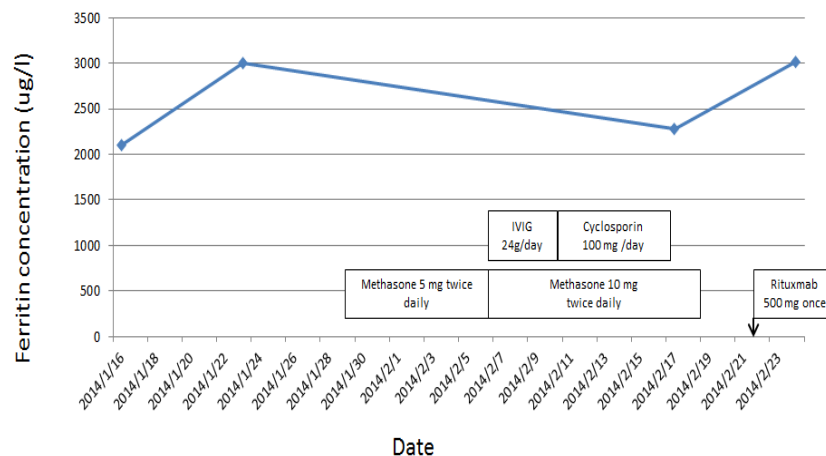


Figure 3. Trend in ferritin concentration

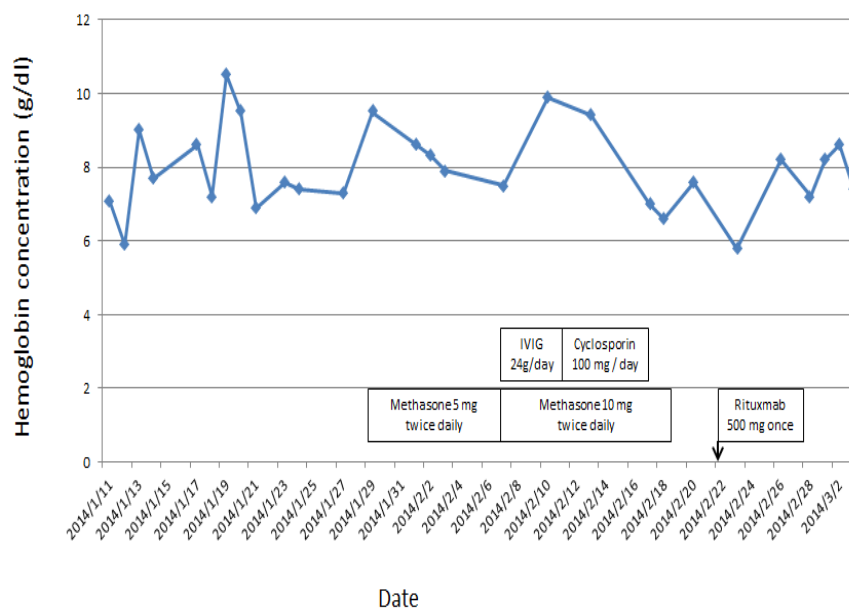


Figure 4. Trend in hemoglobin concentration

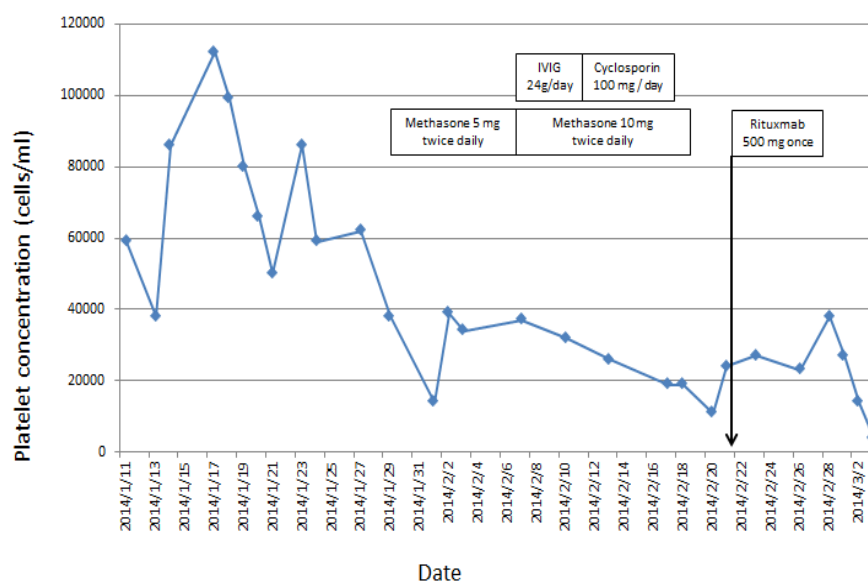


Figure 5. Trend in platelet concentration

Despite intensive immune suppression therapy, hemoglobin decreased to 5.8 g/dl and platelet to 27000/ml. Gastrointestinal bleeding occurred on the fifty eighth day of hospitalization. He was intubated for airway protection. In the Intensive Care Unit, his blood culture reported *Staphylococcus aureus* bacteremia. Despite appropriate antimicrobial therapy, he succumbed to septic shock. Prolonged steroid therapy and Rituximab infusion may have weakened his immune system, resulting in severe bacterial infection. The patient finally died after suffering septic shock.

3. Discussion

The prevalence of secondary HLH was estimated at 0.9% in patients with SLE. Autoimmune associated HLH

commonly affects females with a median age of 43 years [6]. Neurologic symptoms occur in 30% of cases [7]. This report describes an uncommon example of late-onset SLE in a male patient resulting in secondary HLH.

Because of the high mortality associated with HLH, the median survival being 2 months without treatment, the Histiocyte Society proposed an intensive eight week induction therapy with dexamethasone, etoposide, and intrathecal methotrexate. Survival rate increases to 55% after treatment [8]. After induction therapy, eligible patients should receive bone marrow transplantation.

This induction protocol originally enrolled patients with primary HLH or virus-related secondary HLH. Currently no standardized regimen exists for autoimmune associated HLH. Approximately 56% of patients were resistant to

steroid monotherapy [6]. Refractory cases may respond to cyclosporin, cyclophosphamide, or tacrolimus (Figure 6). Affected patients should receive treatment for the underlying rheumatologic disorders. Antimicrobial therapy is indicated to prevent severe bacterial infection during immune suppression therapy.

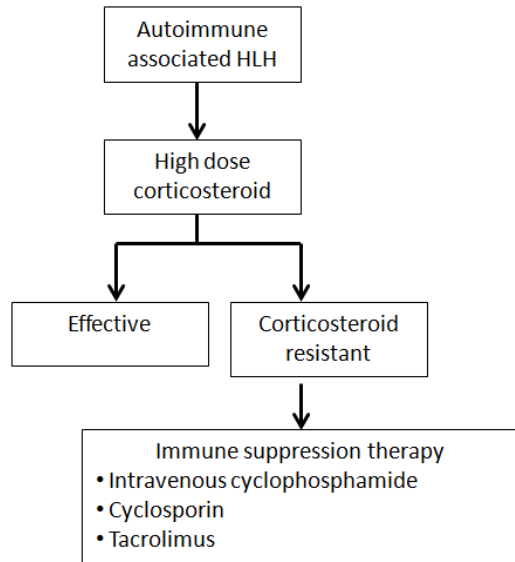


Figure 6. Management of autoimmune associated HLH

4. Conclusion

This report describes a case of SLE associated secondary HLH. The differential diagnoses include HLH triggered by viral infection or malignancy. Infection by EBV is associated with HLH in children and adolescents [9]. HIV relates to HLH in adults [10]. No EBV or HIV infection was identified in the patient. Antibody to cytomegalovirus was present, but quantification reported negligible viral titer. Duodenoscopy and colonoscopy excluded gastrointestinal malignancy.

SLE associated HLH portends poor prognosis. The patient's refractory cytopenia implies that sometimes dexamethasone and cyclosporin are insufficient. Previous literature describes one refractory patient receiving vincristine, which also proved ineffective [6]. In the future, standardized treatment protocols may improve prognosis for patients with autoimmune associated HLH.

Acknowledgment

The authors thank doctor Ren-Chin Wong of the Department of Pathology for reviewing the bone marrow sample.

Nomenclature

HLH (hemophagocytic lymphohistiocytosis), SLE (systemic lupus erythematosus), NK (natural killer), PRF1 (perforin 1), UNC13D (unc-13 homolog D), Munc18-2 (mammalian uncoordinated-18 binding protein 2), Rab27a (Rab subfamily 27a), STX11 (Syntaxin 11), SH2D1A (SH2 domain-containing protein 1A), BIRC4 (baculoviral IAP repeat-containing protein 4), NR (normal range), ANA (antinuclear antibody), APA (anti-phospholipid antibody), IL-2 (interleukin-2), EBV (Epstein-Barr virus), HIV (human immunodeficiency virus)

References

- [1] Freeman HR, Ramanan AV. Review of haemophagocytic lymphohistiocytosis. *Arch Dis Child*. 2011; 96(7):688-693.
- [2] Janka GE. Familial and acquired hemophagocytic lymphohistiocytosis. *Eur J Pediatr*. 2007; 166(2): 95-109.
- [3] Filipovich A, McClain K, Grom A. Histiocytic Disorders: Recent Insights into Pathophysiology and Practical Guidelines. *Biol Blood Marrow Transplant*. 2010; 16(1 suppl): S82-S89.
- [4] Henter JI, Horne A, Arico M, Egeler RM, Filipovich AH, Imashuku S, et al. HLH-2004: Diagnostic and therapeutic guidelines for hemophagocytic lymphohistiocytosis. *Pediatr Blood Cancer*. 2007; 48(2): 124-131.
- [5] Lin TF, Ferlic-Stark LL, Allen CE, Kozinetz CA, McClain KL. Rate of decline of ferritin in patients with hemophagocytic lymphohistiocytosis as a prognostic variable for mortality. *Pediatr Blood Cancer*. 2001; 56: 154-155.
- [6] Fukaya S, Yasuda S, Hashimoto T, Oku K, Kataoka H, Horita T, et al. Clinical features of haemophagocytic syndrome in patients with systemic autoimmune diseases: analysis of 30 cases. *Rheumatology (Oxford)*. 2008; 47 (11): 1686-1691.
- [7] Horne A, Trottestam H, Arico M, Egeler RM, Filipovich AH, Gadner H, et al. Frequency and spectrum of central nervous system involvement in 193 children with haemophagocytic lymphohistiocytosis. *Br J Haematol*. 2008; 140(3): 327-335.
- [8] Henter JI, Samuelsson-Horne A, Arico M, Egeler RM, Elinder G, Filipovich AH, et al. Treatment of Haemophagocytic lymphohistiocytosis with HLH-94 immunochemotherapy and bone marrow transplantation. *Blood*. 2002; 100 (7): 2367-2373.
- [9] Imashuku S. Clinical features and treatment strategies for Epstein-Barr virus-associated hemophagocytic lymphohistiocytosis. *Crit Rev Oncol Hematol*. 2002. 44(3): 259-272.
- [10] Doyle T, Bhagani S, Cwynarski K. Haemophagocytic syndrome and HIV. *Curr Opin Infect Dis*. 2009. 22(1): 1-6.