

# Protective Effect of *Loranthus globosus* on Stress-Induced Major Organ Dysfunctions in Mice

Md. Masud Rana<sup>1</sup>, Alpana Khatun<sup>1</sup>, Md. Rafiqul Islam Khan<sup>1</sup>, Abu Syed Md Anisuzzaman<sup>1,2</sup>,  
Mir Imam Ibne Wahed<sup>1,\*</sup>

<sup>1</sup>Department of Pharmacy, Faculty of Science, University of Rajshahi, Rajshahi, Bangladesh

<sup>2</sup>Department of Radiation Oncology, Winship Cancer Institute, Emory University, Atlanta, USA

## Email address:

drmirimam@gmail.com (M. I. I. Wahed)

\*Corresponding author

## To cite this article:

Md. Masud Rana, Alpana Khatun, Md. Rafiqul Islam Khan, Abu Syed Md Anisuzzaman, Mir Imam Ibne Wahed. Protective Effect of *Loranthus globosus* on Stress-Induced Major Organ Dysfunctions in Mice. *American Journal of Biomedical and Life Sciences*.

Vol. 6, No. 3, 2018, pp. 43-50. doi: 10.11648/j.ajbls.20180603.12

Received: May 27, 2018; Accepted: June 22, 2018; Published: July 16, 2018

**Abstract:** The biochemical parameters such as SGOT, SGPT, MDA, and uric acid levels were investigated for the assessment of stress-induced dysfunction after immobilization stress on the Swiss albino mice. Stress induction caused the elevation of SGOT ( $7.7 \pm 0.2$  vs  $88.8 \pm 0.3$ ; control vs stress), SGPT ( $10.3 \pm 0.5$  vs  $110.5 \pm 5.2$ ), MDA ( $3.9 \pm 0.2$  vs  $9.4 \pm 0.2$  in the serum and  $4.0 \pm 0.3$  vs  $13.9 \pm 0.2$  in brain; control vs stress) and uric acid ( $7.0 \pm 0.1$  vs  $17.2 \pm 0.3$ ; control vs stress) levels in the serum. Histopathology of the liver, kidney heart and lung were also examined, and morphology indicated the degradation of each of the organ by the stress induction. The bark of *Loranthus globosus* was extracted with methanol and then fractionated with petroleum ether (PE), chloroform (CF) and ethyl acetate (EA). Phytochemical screening confirmed the presence of flavanoids and phenolics in all fractions. The antioxidant activity was evaluated by *in vitro* assays using total antioxidant capacity and DPPH- free radical scavenging activity. The results demonstrated that among all the extractives of *L. globosus* EA fraction exhibited highest total antioxidant and free radical scavenging activity. The EA fraction of *L. globosus* (12 mg/kg b. w.) successfully reduced the increased biochemical parameters (stress vs stress + EAF); SGOT ( $88.8 \pm 0.3$  vs  $9.9 \pm 0.9$ ), SGPT ( $110.5 \pm 5.2$  vs  $14.6 \pm 0.7$ ), MDA ( $9.5 \pm 0.2$  vs  $5.5 \pm 0.1$  in the serum; and  $13.9 \pm 0.2$  vs  $7.5 \pm 0.2$  in the brain) and serum uric acid ( $17.2 \pm 0.3$  vs  $8.9 \pm 0.1$ ) on stress-induced mice. Histopathological analysis also supported the beneficial effects of EA fraction of *L. globosus*. Dexamethasone (2 mg/kg b. w.) was used as standard drug. The results suggested that the EA fraction of *L. globosus* might have some beneficial effects in preventing stress-induced organ dysfunction presumably through the neutralization of oxidative-stress generated during immobilization of mice. However, further study is necessary in order to precisely determine the exact molecular mechanisms.

**Keywords:** *Loranthus globosus*, Stress, SGOT and Sgpt, Antioxidant and Free Radical Scavenging

## 1. Introduction

Oxidative stress (OS) represents an imbalance between the production and manifestation of reactive oxygen species (ROS) and a biology system have the ability to readily detoxify the reactive intermediates or to repair the resulting damage. Disturbances in the normal redox state of tissue can cause toxic effects through the production of ROS, such as peroxides and free radical that damage all components of the cell. Some of the ROS (such as superoxide) can be converted

by oxido-reduction reactions into more aggressive radical species that can cause excessive cellular damage [1]. By lipid peroxidation or by oxidizing DNA or proteins, the serve levels of oxidative stress cause necrosis and his damage causes ATP depletion, preventing controlled apoptotic death and causing the cell to simply fall apart [2].

Further, an excess generation of ROS in cells is known to damage DNA, lipids and proteins, resulting in a number of untoward pathophysiological effects such as mutagenesis, malignant transformation, cell death etc. [3-5]. At the initial

stage, to eliminate deleterious ROS from the body, cells utilize various enzymatic and non-enzymatic antioxidants. However, due to excessive oxidative stress, the body's endogenous antioxidant source become exhausted which necessitates the supply of exogenous antioxidants.

In the present study, the antioxidant compound (s) in the methanolic extracts and its various fractions of *Loranthus globosus* and evaluated their protective effects against stress-induced major organ injury in mouse model was investigated. The analyzed serum glutamate oxaloacetate transaminase (SGOT) and serum glutamate pyruvate transaminase (SGPT) levels as biomarkers for liver and heart injury, malondialdehyde (MDA) as biomarker for lipid peroxidation in liver and brain, and serum uric acid levels were also measured. The probable mechanisms of stress-induced oxidative damage and the protective effects of *L. globosus* were also investigated.

## 2. Materials and Methods

### 2.1. Reagents

Dexamethasone was gifted from the Kemiko Pharmaceuticals Ltd., Rajshahi, Bangladesh. 0.9% NaCl solution (Beximco Infusion Lab., Dhaka, Bangladesh), SGOT and SGPT (AMP Medizintechnik GmbH; Austria), gallic acid standard, trichloroacetic acid, thiobarbituric acid, MDA standard and n-butanol (GE Health care, Buckinghamshire, UK)  $\alpha$ ,  $\alpha$ -diphenyl- $\beta$ -picrylhydrazyl (DPPH), sodium phosphate, ammonium molybdate, ascorbic acid and methanol (Sigma Aldrich, St. Louis, USA) were obtained from the sources noted. All employed chemicals and solvents were of analytical grade.

### 2.2. Collection, Extraction and Fractionation of Plant Materials

The barks of *L. globosus* were collected from Pabna, Bangladesh and were taxonomically identified by Dr. Md. Anisuzzaman, Associate Professor, Department of Botany, University of Rajshahi, Bangladesh and the voucher specimen has been preserved in the herbarium. The cleaned stem barks were dried under sunshine and subsequently in oven at 50°C temperatures for complete dryness.

The dried and pulverized plant material was cold extracted by methanol as described previously [13] and the methanolic extract (ME) was successively partitioned with petroleum ether (PE), chloroform (CF) and ethyl acetate (EA) using modified Kupchan partitioning method [14]. The resultant fractions were then evaporated by Rotary-dryer at low temperature (40-50°C) to dryness. The fractions were preserved at -20°C until further experiment. Dimethyl sulfoxide (DMSO) was used for the preparation of dose of various fractions.

### 2.3. Chemical Analysis of the Methanol Extract and Its Fractions

#### i) Determination of total phenolic (TP) content

The total phenolic (TP) content of the crude methanolic extract (ME) of *L. globosus* and its various fractions (PE, CF, EA) were determined by Folin-Ciocalteu Reagent (FCR) according to the method of Kumar *et al.*, [6] with slight modification. Briefly, the solution of each extract (0.5 ml, 1mg/ml) was diluted to 10 ml with distilled water in a volumetric flask. FCR (1 ml) was added and mixed thoroughly, and then sodium carbonate solution (3 ml, 2%) was added. After 2h incubation at room temperature, absorbance was measured at 760 nm. The total phenolic content was determined by comparison with the standard calibration curve of gallic acid, and results are presented as mg of gallic acid equivalents (mg of GAE) per gram dry weight of extracts. All tests were conducted in triplicate.

#### ii) Determination of total flavonoid (TF) content

The total flavonoid content of each extract was estimated by Zhishen *et al.* [7]. Briefly, 0.5 ml (1 mg/ml) of each sample was mixed with 2 ml of distilled water and subsequently with 0.15 ml of NaNO<sub>2</sub> solution (15%). After incubation for 6 min, 0.15 ml of AlCl<sub>3</sub> solution (10%) was added and allowed to stand for another 6 min. Then 2 ml of NaOH solution (4%) was added to the mixture and adjusted the final volume to 5 ml by distilled water. The mixture was then mixed thoroughly and allowed to stand for another 15 min. The absorbance of the final solution was determined at 510 nm. The total flavonoid content was determined by comparison with the standard calibration curve of gallic acid, and results are presented as mg of gallic acid equivalents (mg of GAE) per gram dry weight of extracts.

### 2.4. In Vitro Antioxidant Assay

#### i) DPPH radical scavenging assay

The plant extracts were tested for the scavenging effect on DPPH radical according to the method of Pan *et al.* [8]. Accordingly, 0.2 ml of extract solution in ethanol (95%) at different concentrations (1, 2, 4, 8, 16, 32 and 64  $\mu$ g/ml, respectively) was added to 8 ml of 0.004% (w/v) stock solution of DPPH in 95% ethanol. The scavenging activity on the DPPH radical was determined by measuring the absorbance at 517 nm until the reaction reached the steady state, using a UV-visible spectrophotometer (Shimadzu, Tokyo, Japan). Ascorbic acid was used as a positive control. The DPPH radical scavenging activity (S%) was calculated using the following formula:

$$S\% = [(A_{\text{control}} - A_{\text{sample}})/A_{\text{control}}] \times 100$$

#### ii) Total antioxidant activity assay

The total antioxidant activity of the methanolic extract and its various fractions of *L. globosus* were assessed by phosphomolybdenum method as described previously [9]. Briefly, 0.5 ml sample solution of each fraction was mixed with 3 ml of phosphomolybdenum solution comprising: 0.6 M sulphuric acid, 28 mM sodium phosphate and 4 mM ammonium molybdate. The mixture was then incubated at 95°C for 90 min followed by cooling at room temperature. The absorbance of the solution was measured at 695 nm

against blank. Ascorbic acid was used as a positive control.

### 2.5. Induction of Immobilization Stress in Mouse Model

Male Swiss albino mice weighing about 25-30gm were used for the development of immobilization stress model as described earlier [10]. Briefly, mice were subjected to immovable stress by keeping in a small box being one-sided small leakage and another side a stop cork so that when the mice is being entered into the box it cannot move into the box and can uptake air by the means of small aperture.

### 2.6. Hepatoprotective Activity Test

After completion of treatment with plant, drug or vehicle mice were sacrificed and approximately 2-3 ml of blood was collected directly from heart by syringes, centrifuged at 4000 rpm for 30 minutes to collect supernatants. Two liver enzymes most commonly used as markers of hepatic disease are serum glutamic pyruvic transaminase (SGPT) and serum glutamic oxaloacetic transaminase (SGOT). SGOT and SGPT levels were measured by UV-visible spectrophotometric method using commercial wet reagent diagnostic kits (AMP Medizintechnik GmbH; Austria) according to the manufacturer's protocol. Briefly, the amount of oxaloacetate and pyruvate formed by each of the two assays were measured by means of the 2, 4 - dinitrophenylhydrazine of pyruvic acid, the color of which was read at 520 nm by spectrophotometer. The intensity of color was proportional to the amount of enzyme in each sample.


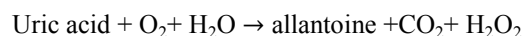
### 2.7. Analysis of Malondialdehyde (MDA) Level

The MDA levels from the brain tissues and serum were determined by the method of Draper and Hadley based on the reaction of MDA with thiobarbituric acid (TBA) at 95°C [11]. The brain tissues were homogenized separately on ice in MDA lysis buffer and centrifuged at 13,000×g for 10 min to collect the supernatant. In the TBA test reaction, MDA and TBA react to form a pink pigment with absorption maximum at 532 nm. The reaction was performed at pH 2-3 at 95°C for 15 min. The supernatant was mixed with 2.5 volumes of 10% (w/v) trichloroacetic acid to precipitate the protein. The precipitate was pelleted by centrifugation and supernatant was reacted with 0.67% TBA in a boiling water bath for 15 min. After cooling, the absorbance was read at 532nm. Arbitrary values obtained were compared with standard solutions (1, 1, 3, 3-tetramethoxypropane). Results are expressed as nmol/mg tissue.

### 2.8. Measurement of Uric Acid Level

Uric acid was determined from uric acid kits.

*Principle:* Uricase



Procedure,

20µl of serum sample (or 20µl of standard) was mixed with 1000µl of working solution. The mixture was incubated at 37°C for 10 minutes. The spectrophotometer was set zero absorbance with working reagent. The absorbance for the sample and standard was taken and calculation was done as follows:

$$C = 8 \times \frac{\text{DA of sample}}{\text{DA of standard}} (\text{mg/dl})$$

$$C = 476 \times \frac{\text{DA of sample}}{\text{DA of standard}} (\mu\text{mol/l})$$

### 2.9. Histopathological Study

After seven days of observation, the animals were killed by cervical dislocation. The liver was carefully excised, rinsed in cold sucrose solution, and blotted dry with filter paper. The specimen was fixed with 10% buffered-formalin and dehydrated in ascending order of ethanol and embedded in paraffin. The blocks were sectioned with the help of rotation microtome at 6-micron thickness. The sections were subjected to Hematoxylin and Eosin staining procedures and the histological examination was done with the aid of the high power microscope. The histological outline of each photomicrograph was conducted through a stereological grid in order to access the population of the cells in each organ. The permanent photomicrographs of each slide were recorded with a Kodak Digital Camera for subsequent histological analysis.

### 2.10. Statistical Analysis

Data were expressed as mean ± standard error of mean (SEM). Statistical comparisons were performed by one-way analysis of variance (ANOVA), followed by Scheffe's post-hoc test or students paired or unpaired t-test where appropriate. The values were considered significant when *p* were less than 0.05 (*p*<0.05). Statistical calculations and the graphs were prepared using Graph Pad Prism version 5.00 for Windows (Graph Pad Software, San Diego, CA, USA, www.graphpad.com).

## 3. Results

### 3.1. Chemical Analysis of Total Phenol and Flavonoid Contents of the Crude Methanol Extract (ME) and Its Fractions of *L. globosus*

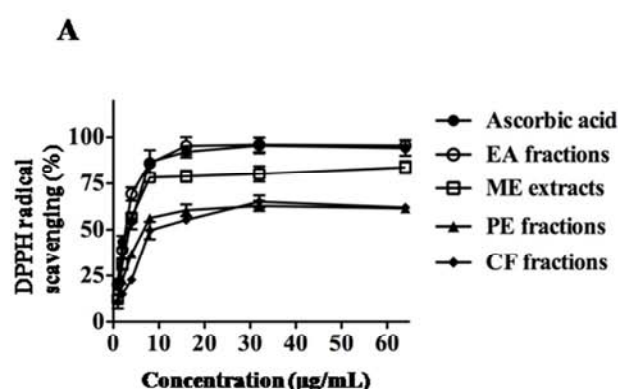
The phenolic and flavonoid compounds are considered as potential antioxidants and free radical scavengers. The contents of total phenol (TP) and total flavonoid (TF) compounds in the various fractions (PE, CF and EA) of methanolic extracts of *L. globosus* were determined. The results are shown in Table 1. The highest amount of TP and TF contents were found in EA fractions (114.84 ± 0.20 and 276.90 ± 16.34 GAE g<sup>-1</sup>, respectively).

**Table 1.** Determination of total phenol and flavonoid contents in the crude methanol (ME) extract and its various fractions of *L. globosus*.

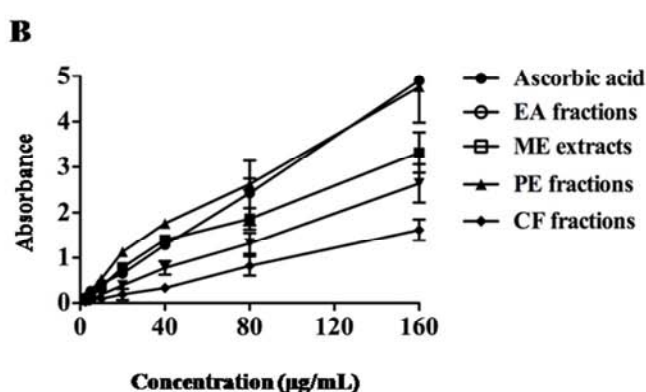
Sample	Total phenol	Total flavonoid
	GAE/gm of dried extracts	GAE/gm of dried extracts
ME extracts	73.07 ± 0.08	198.43 ± 5.19
PE fractions	14.03 ± 0.03	102.50 ± 11.3
EA fractions	114.84 ± 0.20	276.90 ± 16.34
CF fractions	31.84 ± 0.04	53.21 ± 6.09

### 3.2. In Vitro Antioxidant Activity Analysis of the Crude Methanol Extract (ME) and Its Fractions of *L. globosus*

The Figure 1A shows that there was significant scavenging of DPPH free radicals on various fractions of *L. globosus*. Maximum scavenging of  $95.6 \pm 2.5\%$  was observed by EA fractions in a similar extent to that of standard ascorbic acid



( $94.3 \pm 4.2\%$ ), followed by CF ( $62.0 \pm 1.2\%$ ) and PEF ( $61.5 \pm 2.4\%$ ), respectively. Similarly, the Figure 1B shows that the EA fractions have the highest total antioxidant activity. The order of total antioxidant activity in various fractions of *L. globosus* were EA>PE>CF. The results are concordant with the contents of total phenolic and total flavanoid in various fractions.



**Figure 1.** (A) DPPH radical scavenging activity of crude methanol extracts (ME) and its various fraction of *L. globosus*. (B) Total antioxidant activity of the crude methanol extract (ME) and its various fractions of *L. globosus*. Ascorbic acid was used as standard scavenger of the oxidant as well as standard antioxidant agent.

### 3.3. Time Course of Stress-Induced Organ Dysfunction

To assess the effect of stress on liver function, mice were subjected to immobilization stress for a different time period and their liver biomarkers, SGOT and SGPT were measured. As shown in Table 2, both the enzyme concentrations were gradually increasing with the increasing duration of treatment. The peak level was achieved on 7<sup>th</sup> day treatment which was around 30-fold compared to control level.

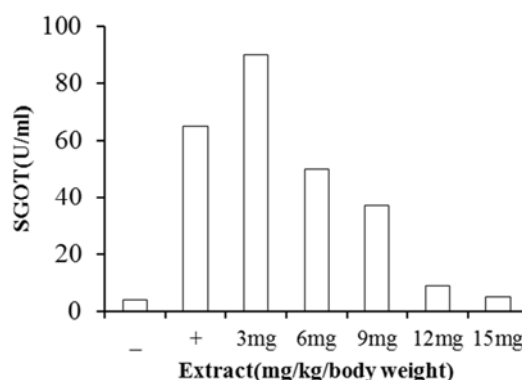
**Table 2.** Time course of change in liver enzyme in stress-induced mice.

Treatment	SGPT ( $\mu\text{kat/l}$ )	SGOT ( $\mu\text{kat/l}$ )
Control	10.2 ± 0.3	7.7 ± 0.2
Stress - 1 Day	15.0 ± 0.2	14.2 ± 0.3
Stress - 2 Day	20.1 ± 0.2*	18.03 ± 0.4*
Stress - 3 Day	27.2 ± 0.3*	22.8 ± 0.4*
Stress - 4 Day	32.9 ± 0.2*	28.9 ± 0.3*
Stress - 5 Day	58.2 ± 0.2	49.2 ± 0.4*
Stress - 6 Day	88.9 ± 0.4	64.9 ± 0.3*
Stress - 7 Day	110.56 ± 0.2	88.9 ± 0.3*
Stress - 9 Day	99.7 ± 0.2*	77.8 ± 0.3*

Values are the mean ± SEM obtained from 4-5 experiments. \*: significantly different ( $p < 0.05$ ) from the time control (tested by unpaired *t*-test).

### 3.4. Dose Dependent Effect of EA Fraction of *L. globosus* for the Reduction of SGOT Level on Stress-Induced Mice

EA fraction of *L. globosus* reduced the elevated SGOT levels of stress-induced mice in a dose dependent manner as shown in Figure 2. Dose used was 3-15 mg/kg/body weight. Among the doses, 3 and 6 mg/kg/body weight was unable to reduce SGOT level significantly. Hence, further experiment was performed with 12mg/kg/body weight of EA fraction.



**Figure 2.** Dose dependent effect of EA fraction of *L. globosus* on SGOT level on Stress-induced mice.

### 3.5. Effect of EA Fraction of *L. globosus* on Various Biochemical Parameters on Stress-Induced Mice

The effect of EA fraction of *L. globosus* on SGOT, SGPT, MDA and uric acid level on stress-induced mice are shown in the Table 3. Dexamethasone was used as standard anti-inflammatory drug. As shown in Table 3, immobilization stress caused the significant elevation of organ biomarkers

(SGOT, SGPT, serum MDA, Uric acid), which were significantly suppressed by the administration of plant extract. Stress-induced elevated MDA levels in brain tissues were also suppressed by the treatment with EA fraction of *L. globosus*, suggesting the protective effect of EA fraction of *L. globosus* on stress-induced heart, liver, brain, and kidney damages.

Table 3. Effect of EAF of *L. globosus* on organ biomarkers in stress-induced mice.

Treatment	SGPT ( $\mu\text{kat/l}$ )	SGOT ( $\mu\text{kat/l}$ )	Serum MDA ( $\mu\text{M}$ )	Brain MDA ( $\mu\text{M}$ )	Serum Uric acid (mg/dL)
Control	10.3 $\pm$ 0.5	7.7 $\pm$ 0.2	4.7 $\pm$ 0.2	4.0 $\pm$ 0.3	9.0 $\pm$ 0.1
Stress	110.5 $\pm$ 5.2*	88.8 $\pm$ 0.3*	12.5 $\pm$ 0.2*	13.9 $\pm$ 0.2*	19.9 $\pm$ 0.3*
Stress+ Dexa	17.9 $\pm$ 0.5 <sup>#</sup>	11.8 $\pm$ 0.2 <sup>#</sup>	9.8 $\pm$ 0.1 <sup>#</sup>	9.5 $\pm$ 0.3 <sup>#</sup>	14.9 $\pm$ 0.2 <sup>#</sup>
Stress + EAF	14.6 $\pm$ 0.7 <sup>#</sup>	9.9 $\pm$ 0.9 <sup>#</sup>	7.8 $\pm$ 0.1 <sup>#</sup>	7.5 $\pm$ 0.1 <sup>#</sup>	11.1 $\pm$ 0.2 <sup>#</sup>

Analyses were performed by one-way ANOVA followed by Scheffe's post-hoc test. \*: Significantly different ( $p < 0.05$ ) from time control after stress (tested by unpaired  $t$ -test). <sup>#</sup>: Significantly different ( $p < 0.05$ ) from stress control with the presence of drug as well as EA fraction of *L. globosus*. Concentration of dexamethasone and EA fraction of *L. globosus* were 2 and 12 mg/kg body weight, respectively. Values are mean  $\pm$  SEM ( $n = 4$  or  $5$ ).

### 3.6. Histopathological Analyses

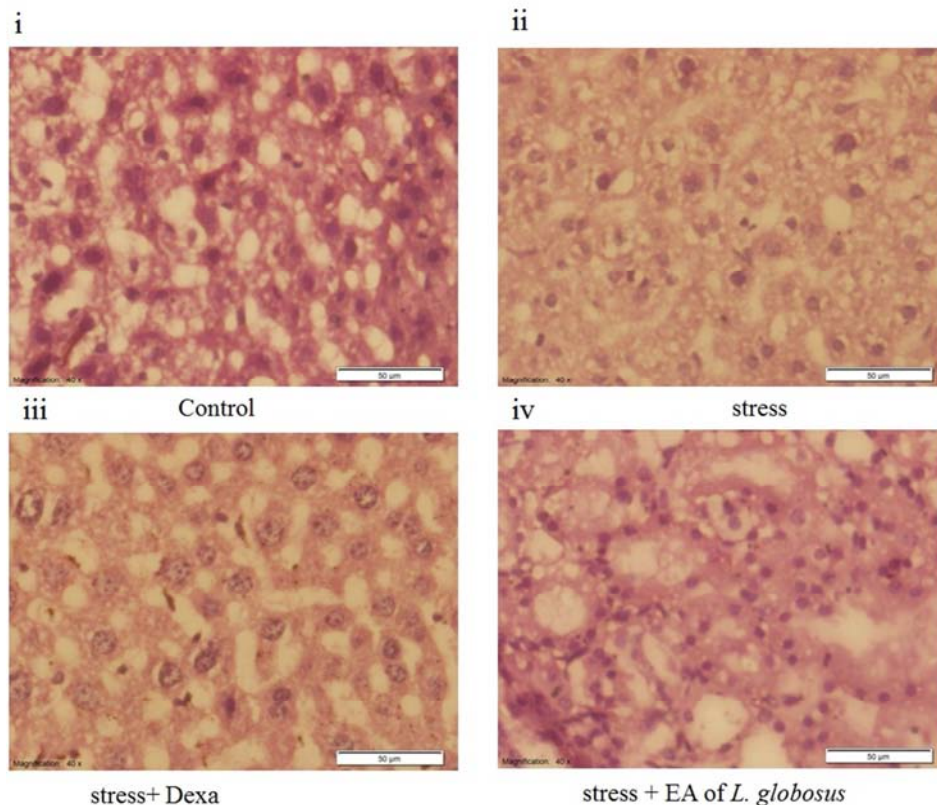
Among the general changes produced by stress in mice liver, kidney, heart, and lung are shown in the Figure 3. These consist essentially of cloudy swelling, varying in intensity associated with vacuolation of protoplasm and destruction of the nuclei; ultimately destruction of cells occurred.

The liver had severe cloudy swelling on stress-induced mice and there was marked fatty degeneration. Areas of focal

necrosis are found in the liver of the stress-induced mice. The interlobular connective tissue is infiltrated with small mononuclear leucocytes. Slight leukocytosis was also present in the livers. The kidneys are the seat of diffuse cloudy swelling.

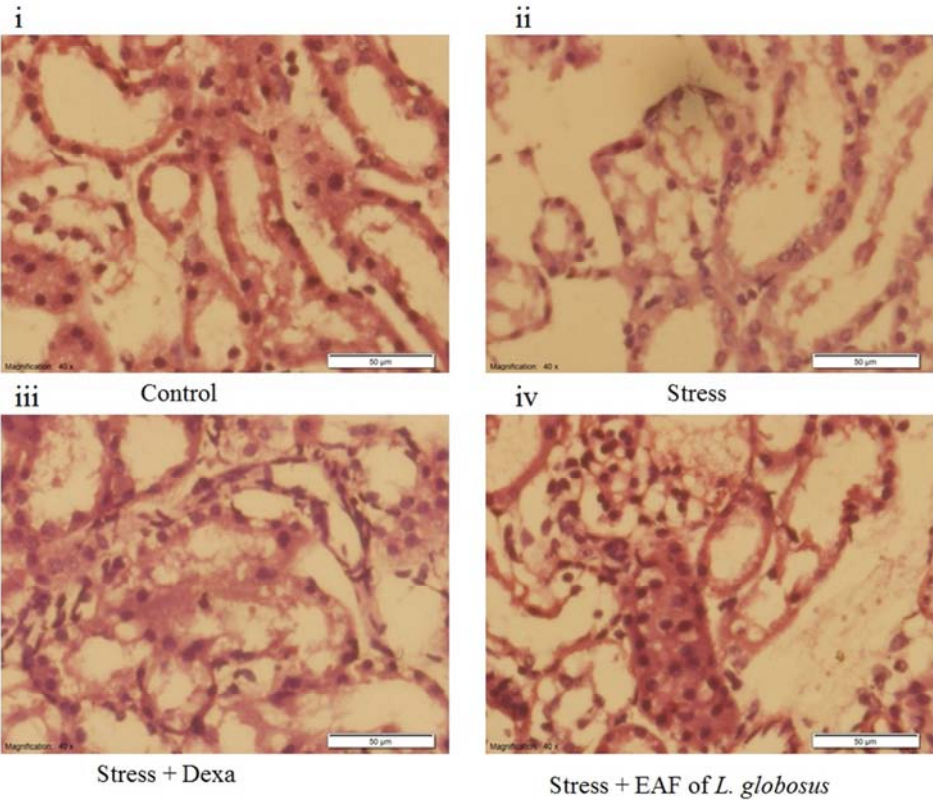
Fatty degeneration is marked in the kidneys of the stress-induced mice. The connective tissue in the kidneys of the stress-induced mice was infiltrated with small mononuclear leucocytes.

#### A Liver tissues

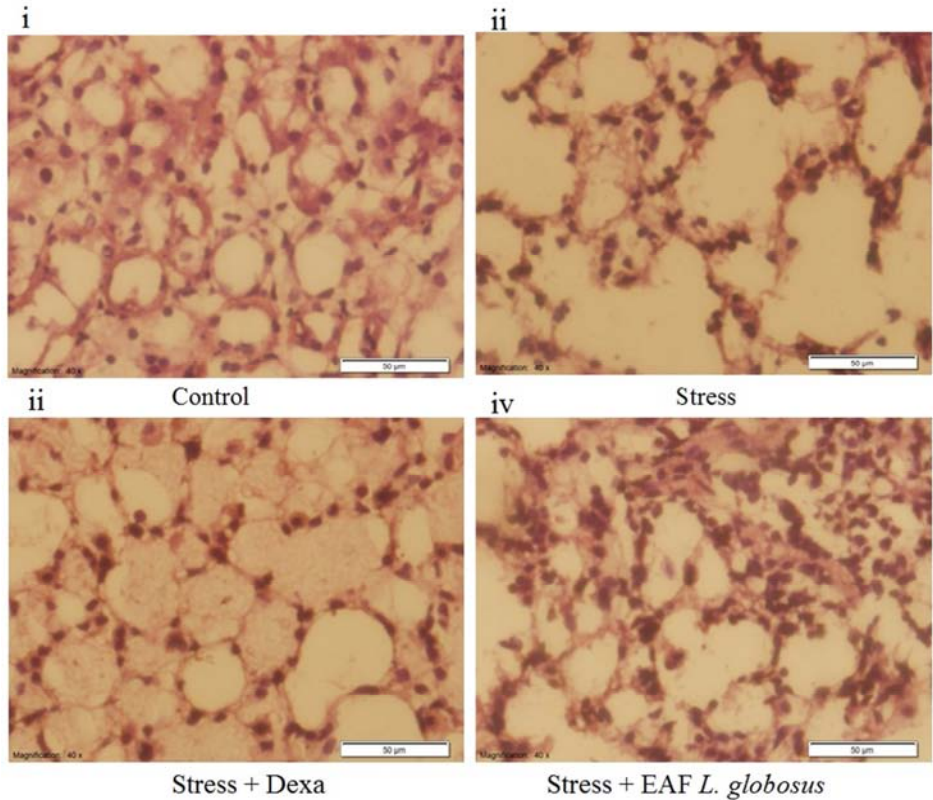


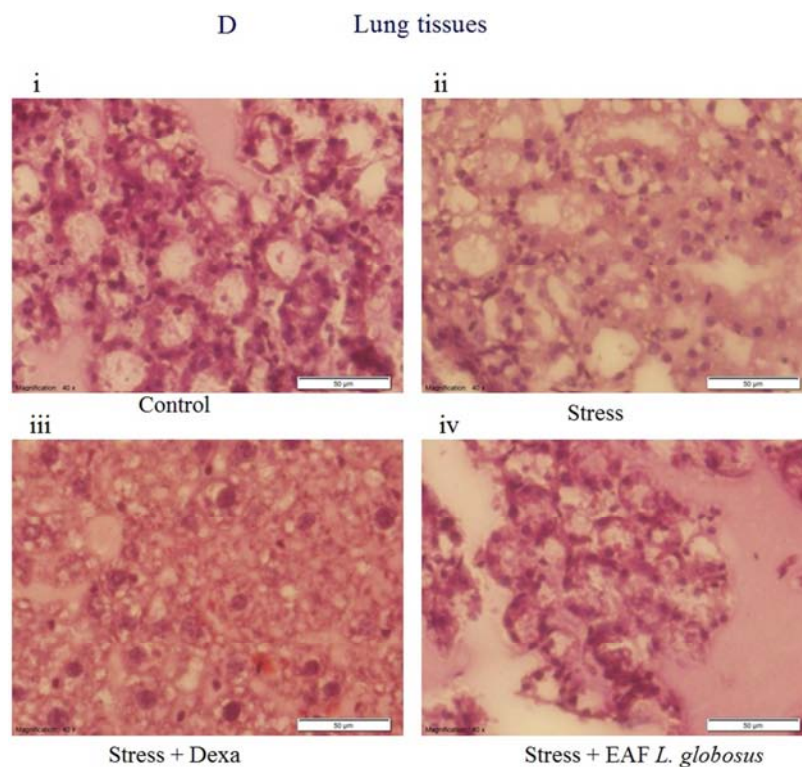


B      Heart tissues



C      Kidney tissues





**Figure 3.** Histopathological studies of stress-induced liver (A), heart (B), kidney (C), and lung (D) damage with or without the treatment of EA fraction of *L. globosus* and Dexamethasone. The representative photographs shown are (i) normal control (ii) stress-induced control (iii) stress induced-induced mice treated with anti-inflammatory compound, dexamethasone and (iv) stress-induced mice treated with EA fraction of *L. globosus*. Scale bars, 50 µm.

The lungs contained a large amount of mood and yellow pigment and eosinophlies. In some areas of the heart muscle, apparent separation of myoblasts along the intercalated discs was observed, but this was not a constant finding and probably represents tearing artifacts produced by osmication. Interestingly, the histopathological degeneration was repaired by the treatment of EA fraction of *L. globosus*. These lines of evidences strongly suggested the protective effects of EA fraction of *L. globosus* on stress-induced organ dysfunction and degeneration.

## 4. Discussion

There is a strong connection between stress and illness. Theories of the stress–illness link suggest that both acute and chronic stress can cause illness, and several studies found such a link [12, 13]. This study has shown that regardless the method of intake, various biochemical and histological abnormalities are produced in response to stress induction. There was a prominent increase of the liver enzymes such as SGOT, and SGPT; lipid peroxidation product MDA in the serum and brain and a marker for chronic kidney disease (CKD), serum uric acid on stress-induced mice. The serum enzyme levels SGPT and SGOT are direct measure of hepatic injury and they show the status of the liver. The elevation of enzymes induced by stress causes hepatotoxicity which may be due to the generation of oxidative free radical that binds to lipoprotein and leads to peroxidation of lipids of endoplasmic reticulum. The disturbance in the transport function of the hepatocytes as a result of hepatic injury

causes the leakage of enzymes from cells due to altered permeability of membrane [14]. The increased serum SGOT and SGPT level is evidence that these enzymes play an important role in the development of acute and chronic inflammation in liver [15]. The elevated level of MDA, which may be due to the free radicals, is responsible for damaging cell membranes and further intensifies inflammatory damage [16]. The inflammatory tissue damages could be due to the liberation of reactive oxygen species from phagocytes that invades the inflammatory sites [17].

Stress induction also elevated serum uric acid levels. Recent epidemiological and experimental model data suggest that uric acid may modulate CKD risk factors, specifically cardiovascular disease and metabolic syndrome. In terms of cardiovascular disease extensive epidemiological data suggests a link to uric acid [18]. These reports and our data suggested the decrease of antioxidant system both in serum and brain in stress-induced mice and overload of oxidative stress which is an important mechanism of organ damages. In our data, we have shown that stress-induced elevation of organ biomarkers was significantly suppressed by the administration of EA fraction of *L. globosus* (Table 3). Histological examination also suggested that EA fraction of *L. globosus* had the capacity to repair the stress-induced organ damages (Figure 3). Among the various phytoconstituents, flavonoids and phenolic compounds have beneficial effects in the oxidative stress-induced inflammatory condition. Flavonoids are particularly reported for significant antioxidant, vasculoprotector, antihepatotoxic,

antiallergic, anti-inflammatory and antitumor activity [19]. Our data confirmed that EA fractions of methanolic extracts of *L. globosus* exhibited potential antioxidant and free radical scavenging capacity (Figure 1) due to the presence of flavonoids and phenolic compounds (Table 1). Hence, the protective effect of EA fraction could be the result of direct free radical scavenging properties [20] or by reacting with membrane phospholipid bilayers to break the chain reaction initiated by ROS [21]. Histological analyses also supported the protective effects of EA fractions of *L. globosus* (Figure 3). The improvement of the activities of antioxidant systems might be one of the results of the free radical scavenging effect of EAF of *L. globosus*. The detailed mechanisms are worthy of further investigation.

## 5. Conclusion

In conclusion, stress induction caused the elevation of liver biomarkers; SGOT and SGPT, lipid peroxidation biomarker, MDA in liver and brain tissues, CKD biomarker, uric acid levels, which were suppressed towards normal levels by the supplementation of the EA fractions of *L. globosus* presumably via the suppression of oxidative stress responsive pathways by its antioxidant and free radical scavenging activity. Although more detailed mechanisms need to be further investigated, the present work provides a potential strategy for treating major organ dysfunctions and damages.

## Abbreviations

SGOT, serum glutamate oxalate transaminase; SGPT, serum glutamate pyruvate transaminase; MDA, malondialdehyde; EA, ethyl acetate; ME, methanol extract; PE, petroleum ether; CF, chloroform; DPPH,  $\alpha$ ,  $\alpha$ -diphenyl- $\beta$ -picrylhydrazyl.

## Conflict of Interest

The authors declare that they have no conflict of interest.

## References

- [1] M. Valko, H. Morris, M. T. Cronin. Metals, toxicity and oxidative stress. *Curr. Med. Chem.* 12(10), (2005) 1161-208.
- [2] M. D. Evans and M. S. Cooke. Factors contributing to the outcome of oxidative damage to nucleic acids. *BioEssays*, 26 (2004) 533-542.
- [3] V. J. Thannickal, B. L. Fanburg, Reactive oxygen species in cell signaling., *Am J Physiol Lung Cell Mol Physiol* 279 (2000) 1005-1008.
- [4] B. S. Berlett, E. R. Stadtman, Protein oxidation in aging, disease, and oxidative stress., *J Biol Chem* 272 (1997) 20313-20316.
- [5] H. Wiseman, B. Halliwell, Damage to DNA by reactive oxygen and nitrogen species: role in inflammatory disease and progression to cancer., *Biochem J* 313 (1996) 17-29.
- [6] K. S. Kumar, K. Ganesan, P. V. S. Rao, Antioxidant potential of solvent extracts of *Kappaphycus alvarezii* (Doty) Doty – An edible seaweed, *Food Chemistry* 107 (2007) 289-295.
- [7] J. Zhishen, T. Mengcheng, W. Jianming, The determination of flavonoid contents in mulberry and their scavenging effects on superoxide radicals, *Food Chemistry* 64 (1999) 555-559.
- [8] Y. Pan, K. Wang, S. Huang, H. Wang, X. Mu, C. He, X. Ji, J. Zhang, F. Huang, Antioxidant activity of microwave-assisted extract of longan (*Dimocarpus Longan* Lour.) peel, *Food Chemistry* 106 (2008) 1264-1270.
- [9] P. Prieto, M. Pineda, M. Aguilar, Spectrophotometric quantitation of antioxidant capacity through the formation of a Phosphomolybdenum Complex: Specific application to the determination of vitamin E, *Analytical Biochemistry* 269 (1999) 337-341.
- [10] A. S. M Anisuzzaman, S. Morishima, F. Suzuki, T. Tanaka, H. Yoshiki, I. Muramatsu. Identification of M1-muscarinic receptor subtype in rat stomach using a tissue segment binding method, and the effects of immobilization stress on the muscarinic receptors. *Eur. J. Pharmacol.* 599 (2008) 146-151.
- [11] A. Khatun, M. M. Rana, M. R. I. Khan, M. I. I. Wahed, M. A. Habib, M. N. Uddin, Z. S. Sathi, A. R. M. R. Amin, A. S. M. Anisuzzaman, Molecular mechanism formalin induced toxicity and management, *American J. Life Sci.* 3(2015) 85-92.
- [12] S. Cohen, D. J.-Deverts, W. J. Doyle, G. E. Miller, E. Frank, B. S. Rabin, and R. B. Turner. Chronic stress, glucocorticoid receptor resistance, inflammation, and disease risk. *PNAS.* 10 (2012) 1073.
- [13] S. Cohen, D. J.-Deverts, G. E. Miller. Psychological stress and diseases. *JAMA.* 298(10) (2007) 1685-1687.
- [14] H. J. Zimmerman, L. B. Seeff, Enzymes in hepatic disease., *Diagnostic Enzymology* (1970).
- [15] A. J. Anderson, W. E. Bocklehurst, A. L. Wills, Evidence for the role of lysosomes in the formation of prostaglandins during carrageenan induced inflammation in rat. *Pharmacol. Res. Comm.* 3 (1971) 13-17.
- [16] R. S. Telang, S. Chatterjee, C. Varshneya, Study on analgesic and antiinflammatory activities of *Vitex negunda* Linn, *Gen Pharmacol* 31 (1990) 363-366.
- [17] E. M. Conner, M. B. Grisham, Inflammation, free radicals, and antioxidants *Nutrition* 12 (1996) 274-277.
- [18] D. I. Feig, D. H. Kang, R. J. Johnson. Uric acid and cardiovascular risk. *N Engl J Med.* 359 (2008) 1811-1821.
- [19] A. M. Fernandez-Leon, M. Lozano, D. Gonzalez, M. C. Ayuso, M. F. Fernandez-Leon. Bioactive Compounds Content and Total Antioxidant Activity of Two Savoy Cabbages. *Czech J. Food Sci.* 32 (2014) 549-554.
- [20] A. Gurel, O. Coskun, F. Armutcu, M. Kanter, O. A. Ozen, Vitamin E against oxidative damage caused by formaldehyde in frontal cortex and hippocampus: biochemical and histological studies. *J Chem Neuroanat.* 29 (2005) 173-178.
- [21] R. J. Verma, A. Nair, Amerlitorative effect of Vitamin E on aflatoxin-induced lipid peroxidation in the testis of mice. *Asian J Androl.* 3 (2001) 217-221.